

[ CASE REPORT ]

## Stent Fracture Induced Infected Pseudo Coronary Artery Aneurysm with Massive Abscess Successfully Treated by Coronary Stent Graft

Kensho Abe, Keisuke Hirai and Tomohiro Kawasaki

### Abstract:

Infected pseudo coronary artery aneurysm (CAA) is extremely rare, and currently, there is no established treatment. We experienced a rare case of an infected pseudo CAA brought on due to a stent fracture. Following prolonged successful antimicrobial administration, which proved effective in successfully treating the patient, we performed coronary stent graft placement. Although a surgical procedure should fundamentally be the first course of action considered in such cases, when there are concerns as to the degree of invasiveness, our strategy represents a viable option.

**Key words:** pseudo coronary artery aneurysm, stent fracture, coronary stent graft

(Intern Med 60: 1403-1407, 2021)

(DOI: 10.2169/internalmedicine.5790-20)

### Introduction

Coronary artery aneurysm (CAA), although uncommon, is known to cause cardiovascular events, such as thrombosis and rupture (1). To date, only a few cases of infected CAA have been reported, with most of them receiving surgical treatment that resulted in unfavorable outcomes (2). Several reports have addressed CAA's etiology, with stent fracture (SF), recognized as one possible cause (1, 3).

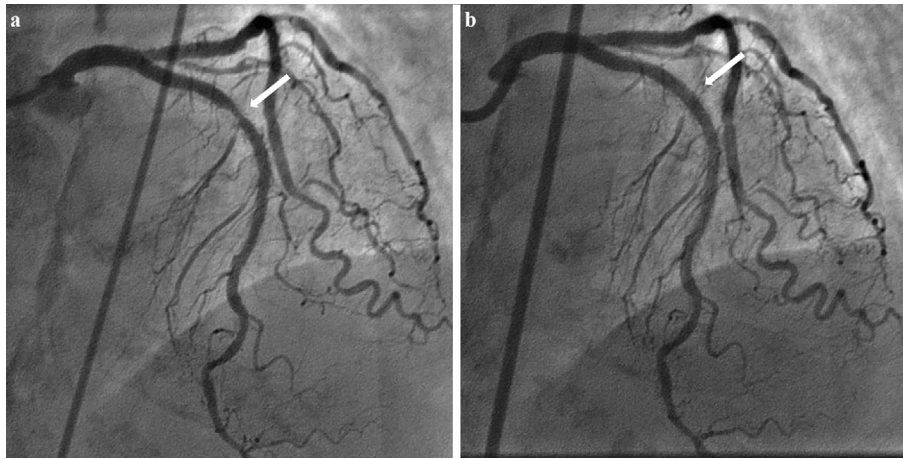
We herein report a case of an infected pseudo CAA with a massive abscess brought on by SF and complicated by bacteremia. Treatment was successfully carried out with coronary stent graft placement following prolonged antimicrobial administration.

### Case Report

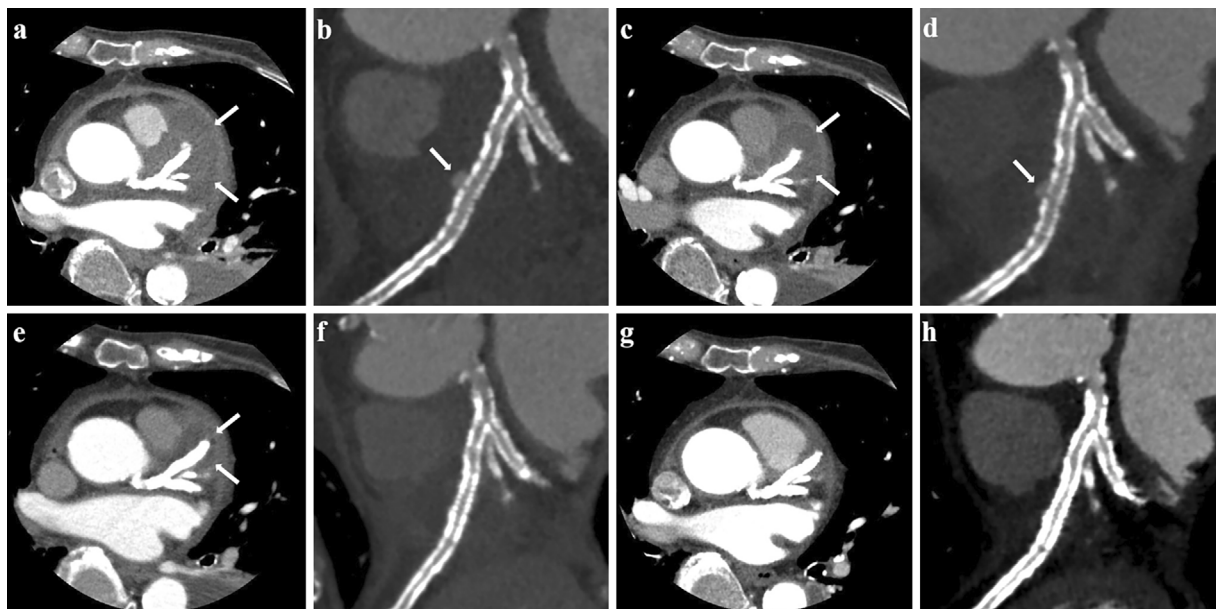
A 77-year-old woman with multiple comorbidities, including type 2 diabetes mellitus, dyslipidemia, hypertension, and hemodialysis was referred to our institution due to a prolonged fever. In June 2013, the patient was diagnosed with non-ST elevation myocardial infarction (NSTEMI) and subsequently underwent initial percutaneous coronary interven-

tion (PCI) for both the mid left anterior descending artery (LAD) and the proximal left circumflex artery (LCX) using a 3.0×28-mm everolimus-eluting stent (EES) and 3.0×15-mm+2.5×28-mm EES, respectively. In March 2018, the patient underwent a second PCI for STEMI in which a 3.0×28-mm EES was deployed due to 99% stenosis in the proximal LAD. In August 2018, we performed a third PCI to correct recurring effort angina pectoris, during which culotte stenting was successfully performed on the left main trunk (LMT) bifurcated lesion (Medina 1, 1, 1) using a 3.5×15-mm EES for the LAD and 3.25×23-mm EES for the LCX, respectively. Six months later, in 2019, a fourth PCI was needed for in-stent restenosis (ISR) of an EES, which had been implanted in the proximal LAD during the second PCI (Fig. 1a), and re-dilation using a 3.5-mm paclitaxel-coated balloon was performed following pre-dilation with 3.25-mm cutting balloon. At this point, we were unable to detect SF on either fluoroscopy or intravascular ultrasound (Fig. 1b).

In March 2020, the patient was re-admitted to our hospital because of a prolonged fever, severe malaise, and chest pain. Laboratory data showed an increased white blood cell count, elevated levels of C-reactive protein (CRP) and troponin-I and blood cultures that were positive for methicillin-resistant *Staphylococcus aureus* (MRSA). In ad-



**Figure 1.** Fourth percutaneous coronary intervention. (a) In-stent restenosis of the everolimus-eluting stent was observed in the proximal left anterior descending artery (white arrow). (b) Following dilatation with a cutting and drug-coated balloon, stent fracture was not observed (white arrow).

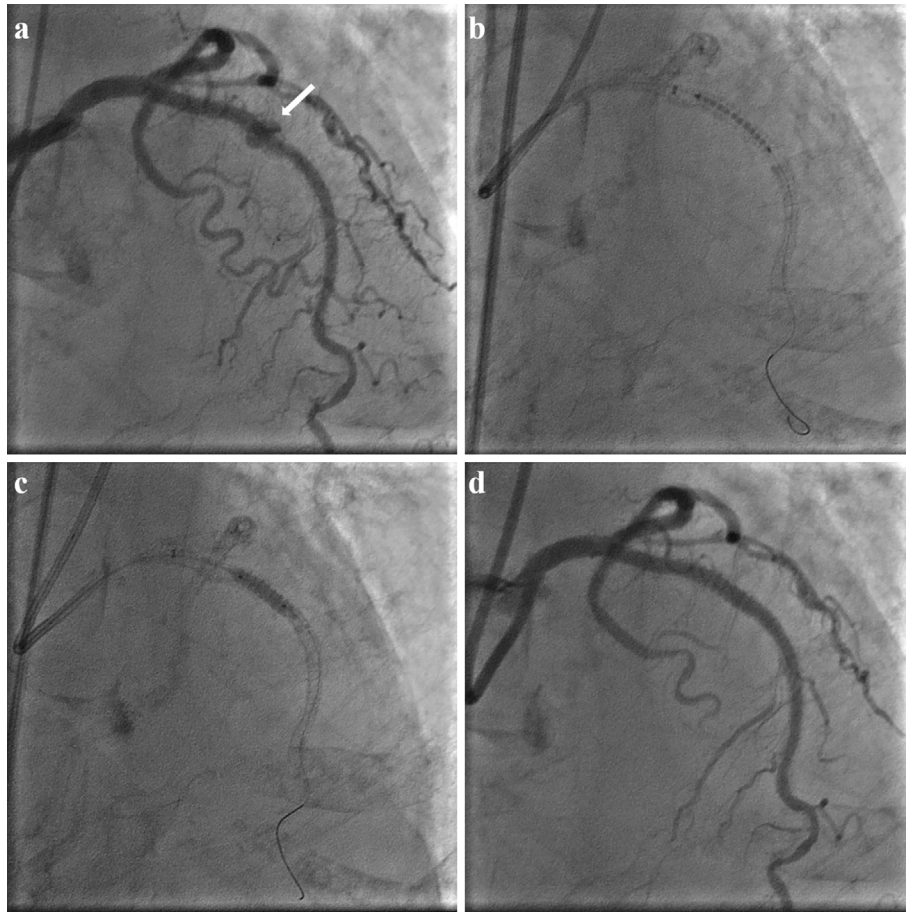

**Figure 2.** Transition of coronary computed tomography angiography findings. (a, c, e) The size of the abscess was gradually reduced with antibiotic treatment (white arrow). (b, d) A stent fracture with contrast material within the abscess was observed. Panel d is from the same period as c (white arrow). (f) After stent graft implantation, the contrast media leakage disappeared. (g, h) The abscess had almost wholly disappeared by the 30th day after discharge.

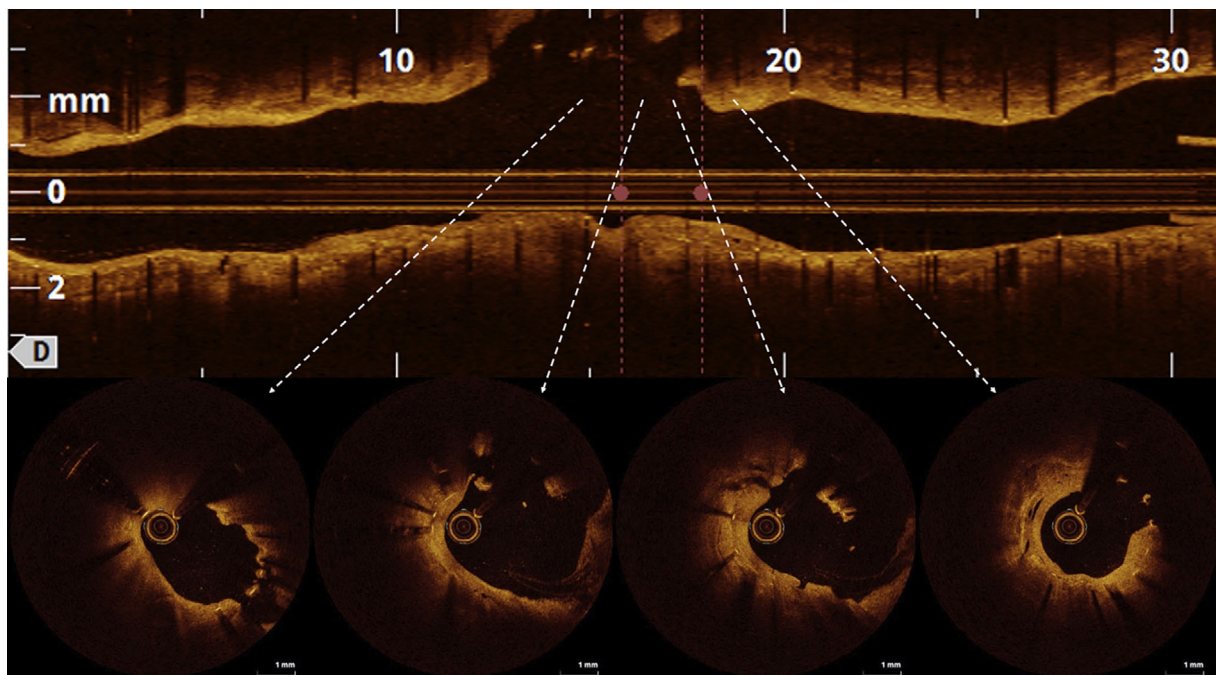
dition, ultrasound echocardiography (UCG) revealed a build-up of fluid around the left coronal cusp, and coronary computed tomography angiography (CCTA) showed a large 45×33-mm low-density mass surrounding the proximal LAD that corresponded to the site that had undergone balloon angioplasty in 2019 (Fig. 2a). Furthermore, contrast media leakage measuring 4×2-mm was observed entering into the mass located at the site of the gaps in the stent strut, and since we detected no autoimmune antibodies that could cause periarteritis (e.g., immunoglobulin-G4 27.4 mg/dL), the patient was diagnosed with a massive abscess (Fig. 2b).

After the diagnosis, we initialized antibiotic treatment

with vancomycin but observed unsatisfactory results, so daptomycin was introduced, resulting in the gradual improvement in the inflammatory response, and a reduction in the abscess confirmed by CCTA (Fig. 2c). Although improvements were seen in both the abscess and inflammatory response, the contrast media leakage remained unchanged (Fig. 2d). Consequently, we performed coronary angiography (CAG) once the inflammatory response normalized. While CAG showed no ISR, it did show a 12×5-mm contrast media leakage (Fig. 3a), and optical coherence tomography (OCT) revealed a lack of stent struts as well as the complete rupture of the vessel wall (Fig. 4). Based on



**Figure 3.** Angiographic findings during stent graft implantation. (a) The size of the contrast media leakage had increased when compared with CCTA findings (white arrow). (b) Successful stent graft delivery was achieved. (c) Post-dilation was performed with a 3.25-mm high-pressure balloon. (d) Leakage was successfully eliminated. CCTA: coronary computed tomography angiography



**Figure 4.** Optical coherence tomography findings before stent graft implantation. The left side of the images is the distal side. A lack of stent struts and vessel wall was observed in the two middle images (white dotted arrow).



the OCT findings, we determined that the pseudo CAA generated by the SF was infected and had, in turn, formed the massive abscess.

To contain the contrast media leakage, which had increased in size, we attempted to place a 2.8×19-mm coronary stent graft (Graftmaster<sup>®</sup>; Abbott Vascular, Santa Clara, USA). Delivering the Graftmaster<sup>®</sup> (Fig. 3b) and performing post-dilation with a 3.25-mm high-pressure balloon (Fig. 3c) resulted in the successful disappearance of the contrast media leakage (Fig. 3d). Post-treatment showed no fever or chest pain, and CT taken 42 days after admission showed an overall reduction in the abscess (Fig. 2e, f). Subsequently, after demonstrating negative CRP values that were also confirmed to be negative for MRSA, the patient was switched to oral antibiotics, and on the 43rd day after admission, the patient was discharged.

On the 30th day after discharge, the patient revisited our hospital for a follow-up examination. Her general condition was good, and the abscess had almost wholly disappeared (Fig. 2g, h).

## Discussion

The present case was diagnosed as an infected pseudo CAA with a massive abscess, and based on CCTA and OCT findings, the SF was determined to be the most probable cause. Kan et al. classified SF into five subtypes and analyzed their correlation with clinical events (4). Although the incidence is quite low, they reported that type 3 and 4 SF, including complete transverse fracture, are risk factors for CAA. In the present case, we were able to confirm the presence of a stent strut gap and contrast media leakage on CTA in the area that corresponded to where a prior cutting and drug-coated balloon had dilated. In addition, an aneurysmal formation similar to that seen on CTA was observed on CAG, and both a missing stent strut and disruption of the vessel wall were clearly observed on OCT at the site of the aneurysm. Given these determinants, a diagnosis of pseudoaneurysm caused by SF was made. In support of our diagnosis, we were able to confirm that the contrast media leakage had come from the SF site and that it was wholly probable that the infected pseudo CAA and massive abscess had resulted from MRSA invading the pseudoaneurysm from that site.

Infected pseudo CAA is extremely rare, and at present, there is no established treatment (5). Even disregarding the infection, there is no specific guideline for managing CAA, so an individualized approach is necessary. Thrombosis, rupture, and external compression are all known recognized as clinical complications of CAA. In the present case, as we believed there to be a risk of rupture because of the continued leakage of contrast media into the pseudo CCA, both interventional and surgical approaches were considered. While coronary stent graft and coil embolization are considered to be percutaneous interventions, ligation, resection, or marsupialization with an interposition graft are classified as

surgical procedures (1, 5, 6). In previous reports, physicians attending to cases complicated by infective endocarditis generally opted for surgical treatment (7-10). In the present case, although we first considered a surgical approach, including debridement, aneurysm excision, stent removal, and coronary bypass, upon further consideration, we believed stent removal to be impractical, since multiple stents had become completely implanted, starting at the LMT and progressing to the LAD and LCX. Since antibiotic therapy had successfully contained the infection and a surgical solution was believed to be highly invasive (logistic EuroSCORE I: 11.9%, STS SCORE: 5.3%), we ultimately opted to proceed with the PCI strategy. In determining the course of treatment, the OCT findings proved particularly useful and resulted in the successful implantation of the coronary stent graft and repair of the disruption of the vessel wall.

Post-procedure, there was no fever, chest pain, or any worsening of the patient's general condition, so after the sixth week, the course of intravenous antibiotics was terminated, and the patient was discharged from the hospital.

One limitation of this report is that no tissue diagnosis of either the infected pseudo CAA or abscess was performed. However, our diagnosis is highly probable based on the clinical, biological, and imaging parameters, and as we were able to sufficiently control the infection, we opted to use a stent graft approach. It is important to note that careful post-procedure follow-up should always be performed, and surgical treatment should be considered if infection recurs. A second limitation is the treatment process before re-admission in March 2020. The recent Ischemia CKD Study clearly demonstrated the limitation of coronary intervention in the dialysis patient population (11). Given that we believe the pseudo CAA due to the SF to have been caused by balloon angioplasty to the ISR lesion in 2019, we should have reconsidered the treatment strategy at that point.

## Conclusion

Using a stent graft while incorporating prolonged antimicrobial administration, our team successfully treated an infected pseudo CAA with a massive abscess caused by SF. Presently, there is no established treatment for infected pseudo CAA, and a coronary stent graft may be a viable alternative as a less-invasive procedure. Considering the causal relationship between CAA and SF, a multidisciplinary team can help make an appropriate decision concerning the treatment of specific patients.

**The authors state that they have no Conflict of Interest (COI).**

## Acknowledgement

The authors thank all staff in the catheter laboratory in Shin-Koga Hospital for their technical support.

## References

1. Kawsara A, Nunez Gil JJ, Alqahtani F, Moreland J, Rihal CS, Alkhouli M. Management of Coronary Artery Aneurysms. *JACC*

- Cardiovasc Interv **11**: 1211-1223, 2018.
2. Elieson M, Mixon T, Carpenter J. Coronary stent infections: a case report and literature review. *Tex Heart Inst J* **39**: 884-889, 2012.
  3. Oshima T, Minatsuki S, Myojo M, et al. Coronary artery aneurysm caused by a stent fracture. *Int Heart J* **59**: 203-208, 2018.
  4. Kan J, Ge Z, Zhang JJ, et al. Incidence and clinical outcomes of stent fractures on the basis of 6,555 patients and 16,482 drug-eluting stents from 4 centers. *JACC Cardiovasc Interv* **9**: 1115-1123, 2016.
  5. Abou Sherif S, Ozden Tok O, Taskoylu O, Goktekin O, Kilic ID. Coronary artery aneurysms: a review of the epidemiology, pathophysiology, diagnosis, and treatment. *Front Cardiovasc Med* **4**: 24, 2017.
  6. ElGuindy MS, ElGuindy AM. Aneurysmal coronary artery disease: An overview. *Glob Cardiol Sci Pract* **2017**: e201726, 2017.
  7. Dieter RS. Coronary artery stent infection. *Clin Cardiol* **23**: 808-810, 2000.
  8. Ben Messaoud M, Bouchahda N, Mahjoub M, Hmida B, Dridi Z, Gamra H. Case report: coronary artery stent infection with mycotic aneurysm secondary to tricuspid valve infective endocarditis. *F1000Res* **8**: 853, 2019.
  9. Tsai KC, Chen JS, Huang JH, Huang CY. Staphylococcal infection-related constrictive pericarditis with formation of a mycotic aneurysm in the right coronary artery. *J Formos Med Assoc* **114**: 1149-1150, 2015.
  10. Sugiyama K, Matsuyama K, Maruno K, et al. A case of ruptured infective coronary artery aneurysm. *Surg Case Rep* **3**: 75, 2017.
  11. Bangalore S, Maron DJ, O'Brien SM, et al. Management of coronary disease in patients with advanced kidney disease. *N Engl J Med* **382**: 1608-1618, 2020.

The Internal Medicine is an Open Access journal distributed under the Creative Commons Attribution-NonCommercial-NoDerivatives 4.0 International License. To view the details of this license, please visit (<https://creativecommons.org/licenses/by-nc-nd/4.0/>).