

Safety of latex urinary catheters for the short time drainage

Mehrdad Hosseinpour, Saeed Noori, Mahdiah Amir-Beigi, Mohammad Hassan Pourfakharan, Hassan Ehteram, Mohadese Hamsayeh

Trauma Research Center, Kashan University of Medical Sciences, Kashan, Iran

Abstract

Background: In this study, we attempt to identify the most appropriate catheter (silicone vs. latex) for short-term urinary catheterization. We compared the post-operative clinico-pathological complications between latex and silicone for short term catheterization in rabbits with hypospadias.

Materials and Methods: Forty rabbits were used in our study to compare complications of catheterization. They were divided in two groups. Hypospadias like defect was created by a 1 cm long excision of the ventral urethra. For urethroplasty, we used tubularized incised plate technique. Latex and silicon catheters were used in groups 1 and 2, respectively. Post-operatively, routine laboratory urine test and complications (allergy, infection, bleeding) were compared in groups.

Results: A total of 40 rabbits underwent hypospadias repair. Findings showed that there were no significant differences between groups based on urine test indices ($P = NS$). Urinary tract infection rate was 10% (2 rabbits) in latex and 0% in silicone groups ($P = NS$). There were no significant differences between groups regarding of cystitis grades between study groups ($P = NS$).

Conclusion: It seems that urinary tract catheterization with latex catheters is a safe, feasible, and in-expensive procedure for short-term post-operative course in hypospadias surgery in patients without latex hypersensitivity.

Key words: Complication, foley catheter, hypospadias, silicone catheter

Address for correspondence:

Dr. Mehrdad Hosseinpour, Trauma Research Center, Kashan University of Medical Sciences, Kashan, Iran. E-mail: meh_hosseinpour@yahoo.com

Submission: 08.03.2013, **Accepted:** 31.07.2013

INTRODUCTION

Urinary catheters are used for diagnosing pathology in the lower urinary tract, to monitor urine output, and to relieve urinary retention. Short term (≤ 2 weeks) catheterization is used following some of urological surgery such as distal to mid shaft hypospadias to enable measurement of intra- and post-operative urine output and prevention of possible acute urinary retention following surgery^[1,2] due to swelling and pain. Indwelling urethral catheters were originally made of natural latex rubber, which was flexible and inexpensive. However, there are some

controversies about the safety of these catheters in clinical practice.^[3-5] Although some surgeons believe that Foley catheter can cause allergic reaction, hemorrhagic cystitis, but there are some studies that failed to show these effects in short-term catheterization. We also did not find any reports for evaluation of these effects on histological specimens to document these changes. Therefore, we conducted an animal study to compare the post-operative clinico-pathological complications between latex and silicone for short term catheterization in rabbits with hypospadias to identify the most appropriate catheter (silicone vs. latex) for short-term urinary catheterization.

MATERIALS AND METHODS

Local research ethics committee approved the study. Forty rabbits were used in our study to compare complications of catheterization. White, male New Zealand rabbits (Razi institute, Tehran, Iran) weighing 1500 g were identified by numbering from 01 to 40, tattooed on the

Access this article online	
Quick Response Code:	Website: www.urologyannals.com
	DOI: 10.4103/0974-7796.134257

internal face of the right ear were selected. Rabbits were kept in a controlled environment (temperature: 24-26°C, humidity: 55-65%, fed a commercial pellet diet (Niro-sahand co, Tabriz, Iran) and allowed freely access to tap water until 4 h before surgery when feeding was discontinued.

They were divided into two groups (odds as group 1 (G1), evens as group (G2).

Anesthesia was done with intramuscular premedication of 2 mg/kg body weight acepromazine (30 min before anesthesia and 4 mg/kg body weight Xylazine associated with 40 mg/kg body weight ketamine intramuscularly.

Then the animal was placed in a horizontal dorsal decubitus on the surgical table and its paws fixed to the extremities of the table with thin ropes. With midline penile skin incision^[6] from base to glans, preputial glands were mobilized to expose the urethra and corpora cavernosa. Then the vertical wall of the penile urethral was longitudinally opened for 1 cm in the midline. The dorsal urethral plate was visible and incised longitudinally in the midline for 1 cm without involving the underlying tunica albugina.

Hypospadias like defect was created by a 1 cm long excision of the ventral urethra. For urethroplasty, we used tubularized incised plate (TIP) technique in all rabbits as described by Lalla et al.^[6] All procedures were performed at with 10 × magnification.

Latex and silicon catheters were used in G1 and G2, respectively (An 8 Fr catheter with a balloon).

Post-operatively, animals were kept in controlled environment for 10 days. Pre-operatively subcutaneous administration of sulfadiazine plus trimethoprim (4-8 mg/kg) was followed by post-operative administration daily for 10 days.

Routine laboratory urine test was performed on a regular basis. On post-operative assessment, number of post-operative complications (allergy, infection, bleeding) were recorded.

Allergy to catheter was diagnosed as red eyes, clear discharge from nose, and excessively touching of nose and face with paws.

Infection in the bladder or urinary tract^[7] was diagnosed according to the following criteria as bloody urine (hematuria), thick, beige or brown-colored urine, increased white blood cell counts of urine, and positive urine culture.

Bleeding was defined as symptomatic urinary hemorrhage due to infection or inflammation.

After 10 days, rabbits were killed under general anesthesia by an intra-cardial overdose of pentobarbital and bladder

necks were harvested. The bladder necks were fixed in 10% formalin. The isolated bladder neck in its expanded form was fixed, trimmed, and embedded in paraffin to prepare thin sections. Deparaffinized sections were stained with H and E and examined under light microscopy.

For pathological cystitis grading, six histological characteristics were graded (bladder epithelium denudation, submucosal edema, congestion and ectasia, inflammatory infiltrate, hemorrhage and fibrosis) as grade 0 (none) to 5 (severe).^[8]

Hematuria was graded as^[9] Grade 0: None, Grade 1: Microscopic only, Grade 2: Intermittent gross bleeding, no clots, Grade 3: Persistent gross bleeding or clots.

Statistical analysis was performed using SPSS (version 11.5). Data were expressed as mean ± SD for quantitative variables and percentage for qualitative ones.

The Mann–Whitney test was used to determine any difference in the mean scores. The relationship between qualitative scores and catheter type was investigated using two-tailed test and Fisher's exact test. *P* values less than 0.05 were considered significant.

RESULTS

A total of 40 rabbits underwent hypospadias repair. We have no mortality in our cases. In the first study group (G1), a latex catheter was placed in repaired urethra for 10 days. Animals in the second groups (G2) were catheterized by silicone catheters for the same period.

Laboratory urine test

Table 1 shows the changes of red blood cell in urine test during indwelling urinary catheterization. Findings showed that there were no significant differences between groups based on urine test indices.

Clinical complications

One rabbit in G1 had allergic reaction to latex catheter. Urinary tract infection rate was 10% (2 rabbit) in G2 and 0% in G1 (*P* = NS). It seems that the type of catheter has no effect on urinary tract infection. Table 2 shows the hematuria grades in groups, there was no significant differences between groups in short term catheterization (*P* = NS).

Post-mortem examination

Table 3 shows the cystitis grading (none to severe) in groups. There were no significant differences between groups regarding of cystitis grades between study groups [Figures 1 and 2] (*P* = NS).

Table 1: Changes in blood cells in urine test during indwelling urinary catheterization

	Latex catheter (%)	Silicone catheter (%)	P
Red blood cells			
Day 5	12 (60)	10 (50)	NS
Day 10	11 (55)	9 (45)	NS
White blood cells			
Day 5	14 (70)	12 (60)	NS
Day 10	6 (30)	6 (30)	NS

Table 2: Hematuria grading in groups

Grade	Latex group (%)	Silicone group (%)
0	5 (25)	4 (20)
1	11 (55)	9 (45)
2	3 (15)	7 (35)
3	1 (5)	0 (0)

Table 3: Microscopic grading of cystitis in study groups

Pathological grades	Latex group (%)	Silicone group (%)
0	0 (0)	0 (0)
1	0 (0)	4 (20)
2	6 (30)	2 (20)
3	10 (50)	6 (30)
4	0 (0)	4 (20)
5	4 (20)	4 (20)

DISCUSSION

While pediatric surgeon increasingly managing children with multiple and complex urological diseases such as hypospadias, it is important that they choose an appropriate catheter type for their patients. Despite the progress in hypospadias surgery, the choice of urine catheter to drain bladder is still controversially discussed.

Indwelling urethral catheters were originally made of natural latex rubber, which is flexible and inexpensive but other types of catheters such as silicone,^[10] silastic,^[11] polyvinylchloride,^[12] and poly ethylene^[13] and anti-microbial coated^[14] are also used in clinical practice.

In this study, we conducted an animal investigation in an attempt to identify the most appropriate catheter (silicone vs. latex) for short-term urinary catheterization after hypospadias repair. Based on our knowledge our study is a unique study for evaluation of urinary catheter effects on histological changes in animal model.

Urinary tract inflammation

Indwelling catheters are almost invariably associated with characteristic mucosal lesions of urinary bladder, commonly referred to polypoid cystitis. Our findings showed that there was no correlation between the type of catheter and mucosal lesions. This finding was also reported by Norlen *et al.*^[15] They

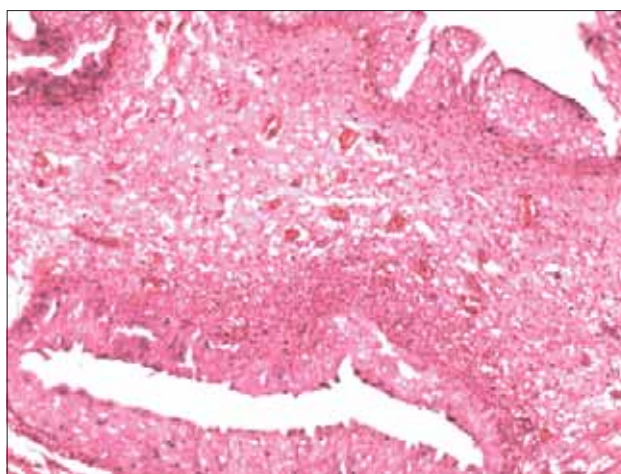


Figure 1: Microscopic findings of cystitis in latex group

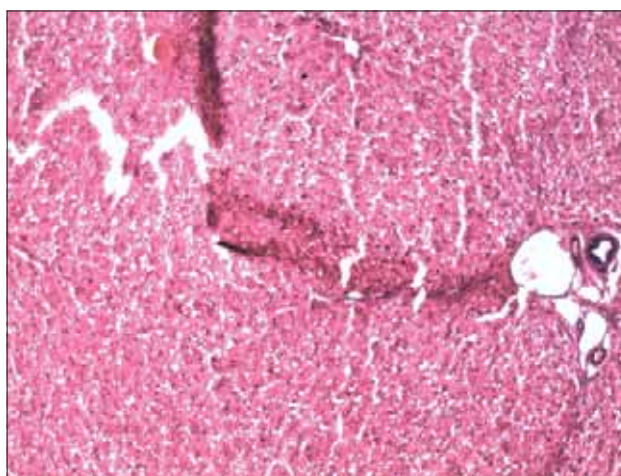


Figure 2: Microscopic findings of cystitis in Silicone group

also showed that there was no correlation between the length of catheterization and mucosal lesions. It seems that mechanical irritation and/or pressure exerted by the catheter on the mucosa is responsible for the development of cystitis.

This mechanical/pressure mechanism was also showed by Abu-Yousef *et al.*^[16] study as bulbous (thickened mucosa in early stage, redundant, and polypoid in late stage) in cystosonography. However, indwelling catheters initiate the accumulation and prevent drainage of urethral secretion causing urethritis, some studies showed that silicone catheters have a wider lumen and urethritis following short-term catheterization may be significantly reduced.^[17]

We did not evaluate urethral histo-pathological changes in our animals and this would be one of the weaknesses of our study.

Although in Wei-yao report,^[18] in comparison with latex catheter, silicone catheters caused less injuries and urinary mucosal irritation in patients who need long-term catheterization,

however use of catheters in animal models for longer than 6 weeks showed no difference in inflammatory response between latex and silicone materials.^[19]

Urinary tract infection

Although a variety of specialized antiseptic/antibiotic impregnated catheters have been designed to reduce the risk of UTI, but they are expensive and not achievable in every pediatric surgery ward.

In our study, there was no significant difference between groups for urinary tract infection in short-term course. This finding is similar to Schumm *et al.* study.^[20] They also showed that there was not enough evidence to suggest whether or not any standard catheter was better than another in term of reducing the risk of UTI in hospitalized patients with short-term catheterization.

Although two studies showed that silicone catheters postpone bacteriuria and had the potential to minimize catheter related infection, but this result should be interpreted with some caution as the trials were small and the outcome definitions and compared specific catheters varied.^[19] In one study, silver impregnated catheters were associated with more frequent bacteriuria and an increased risk of staphylococcal bacteriuria.^[19]

CONCLUSION

Based on our results, it seems that urinary tract catheterization with latex catheters is a safe, feasible, and in-expensive procedure for short-term post-operative course in hypospadias surgery in patients without latex hypersensitivity.

REFERENCES

1. Ramakrishan K, Mold JW. Urinary catheters: A review. *Internet J Fam Pract* 2005;3:1-29.
2. Lepor H. Managing and preventing acute urinary retention. *Rev Urol* 2005;7(Suppl 8): S26-33.
3. Wilson M. Addressing the problems of long-term urethral catheterization: Part 2. *Br J Nurs* 2012;21:16,18-20, 22.
4. Wu AK, Blaschko SD, Garcia M, McAninch JW, Aaronson DS. Safer urethral

5. catheters: How study of catheter balloon pressure and force can guide design. *BJU Int* 2012;109:1110-4.
5. Mizuno J, In-Nami H. 2009 Japanese Society of Latex Allergy guidelines for the safe management of latex allergy. *Masui* 2011;60:753-6.
6. Lalla M, Riis C, Jørgensen CS, Danielsen CC, Jørgensen TM. A biomechanical, histological and biochemical study in an experimental rabbit hypospadias repair model using scanning acoustic microscopy. *J Pediatr Urol* 2011;7:404-11.
7. Evliyaoğlu Y, Kobaner M, Celebi H, Yelsel K, Doğan A. The efficacy of a novel antibacterial hydroxyapatite nanoparticle-coated indwelling urinary catheter in preventing biofilm formation and catheter-associated urinary tract infection in rabbits. *Urol Res* 2011;39:443-9.
8. Rosamilia A, Igawa Y, Higashi S. Pathology of interstitial cystitis. *Int J Urol* 2003;10:S11-5.
9. Cancer Therapy Evaluation Program. Common toxicity criteria, Version 2.0 DCTD, NCI, NIH, DHHS March 1998.
10. Siddiq DM, Darouiche RO. New strategies to prevent catheter-associated urinary tract infections. *Nat Rev Urol* 2012;9:305-14.
11. Walter JS, Wheeler JS, Wang X, Wurster RD. Balloon-tipped catheter for measuring urethral pressures. *J Spinal Cord Med* 2009;32:578-82.
12. Witjes JA, Del Popolo G, Marberger M, Jonsson O, Kaps HP, Chapple CR. A multicenter, double-blind, randomized, parallel group study comparing polyvinyl chloride and polyvinyl chloride-free catheter materials. *J Urol* 2009;182:2794-8.
13. Sankar S, Rajalakshmi T. Application of poly ethylene glycol hydrogel to overcome latex urinary catheter related problems. *Biofactors* 2007;30:217-25.
14. Kowalczyk D, Gowin E, Miazga-Karska M. Quantitative evaluation of sparfloxacin binding to urological catheter surfaces. *Pharmazie* 2012;67:20-4.
15. Norlén LJ, Ekelund P, Hedelin H, Johansson SL. Effects of indwelling catheters on the urethral mucosa (polypoid urethritis). *Scand J Urol Nephrol* 1988;22:81-6.
16. Abu-Yousef MM, Narayana AS, brown RC. Catheter-induced cystitis: Evaluation by cystosonography. *Radiology* 1984;151:471-3.
17. Talja M, Korpela A, Järvi K. Comparison of urethral reaction to full silicone, hydrogen-coated and siliconised latex catheters. *Br J Urol* 1990;66:652-7.
18. Huang WY, Wei LP, Ji YG, Xu DX, Mo JK. Effects of silicone and latex urinary catheters: A comparative study. *Di Yi Jun Yi Da Xue Xue Bao* 2005;25:1026-8.
19. Cravens DD, Zweig S. Urinary catheter management. *Am Fam Physician* 2000;61:369-76.
20. Schumm K, Lam TB. Types of urethral catheters for management of short-term voiding problems in hospitalized adults: A short version Cochrane review. *Neurol Urodyn* 2008;27:738-46.

How to cite this article: Hosseinpour M, Noori S, Amir-Beigi M, Pourfakharan MH, Ehteram H, Hamsayeh M. Safety of latex urinary catheters for the short time drainage. *Urol Ann* 2014;6:198-201.

Source of Support: Nil, **Conflict of Interest:** None.