

Available online at www.sciencedirect.com

ScienceDirect

journal homepage: www.elsevier.com/locate/ihj

Case Report

A unique and unexplained ricochet leak post PCI — Successfully treated with intra-coronary glue

Pravin K. Goel^{a,*}, Sanjeev K. Syal^b^a Professor & Head, Department of Cardiology, Sanjay Gandhi Postgraduate Institute of Medical Sciences, Lucknow 226014, India^b Senior Resident, Department of Cardiology, Sanjay Gandhi Postgraduate Institute of Medical Sciences, Lucknow 226014, India

ARTICLE INFO

Article history:

Received 13 March 2013

Accepted 5 December 2013

Available online 26 December 2013

Keywords:

Electrocardiogram

PTCA

Intra-arterial glue

ISR

Angioplasty

ABSTRACT

We herein describe a unique case of coronary artery perforation treated with covered stent with repeat cardiac tamponade resulting out of a fresh unexplained leak from a remote vessel (Ricochet) and successfully treated with intra-coronary injection of sterile synthetic glue, cyanoacrylate.

Copyright © 2014, Cardiological Society of India. All rights reserved.

1. Case

TTR was a 72-year-old gentleman, a follow up case of angioplasty and stent to LAD done in 2007 and repeat PCI to a new lesion in CX/OM done 6 months back. He presented with history of rest angina with raised cardiac enzymes a week prior to index procedure. Electrocardiogram revealed LBBB with discordant T waves. Coronary angiogram done this time revealed severe in-stent restenosis (ISR) of OM and patent stents to LCX and LAD (Fig. 1). RCA had mild ostial disease as before. The patient was planned for a balloon angioplasty to ISR segment followed by possible drug eluting balloon.

Left coronary artery was engaged with extra back-up 3.5 guiding catheter (Medtronic Inc.) and the lesion crossed with whisper wire. Lesion dilatation was attempted with 2.5 mm

monorail PTCA balloon (Voyager, Abbott Vasc, USA) but it slipped repeatedly and hence was changed to a 2.5 mm diameter and 12 mm long knobby balloon (Acrostack AG, Switzerland) which achieved adequate dilatation within the stented segment. A mild lesion was seen distally just beyond the stent which was further dilated with same balloon. The angiogram done immediately post final balloon dilatation now showed a small bulge in contour (Fig. 2A), which quickly progressed to complete rupture (coronary perforation grade 3, Fig. 2B) with the immediately following injection showing torrential leak into the pericardial space. The patient's blood pressure fell precipitously and expansion of cardiac silhouette could be seen on fluoroscopy. Echo revealed massive pericardial effusion with cardiac tamponade. Immediate attempt to seal the perforation site with a covered stent, Graft-master

* Corresponding author. Tel.: +91 0522 2494227 (O), +91 0522 2494228 (R), +91 9839015010 (mobile); fax: +91 522 2668017, +91 522 2668078.

E-mail addresses: golf_pgi@yahoo.co.in, pkgoel@sgpgi.ac.in (P.K. Goel).

0019-4832/\$ – see front matter Copyright © 2014, Cardiological Society of India. All rights reserved.

<http://dx.doi.org/10.1016/j.ihj.2013.12.031>

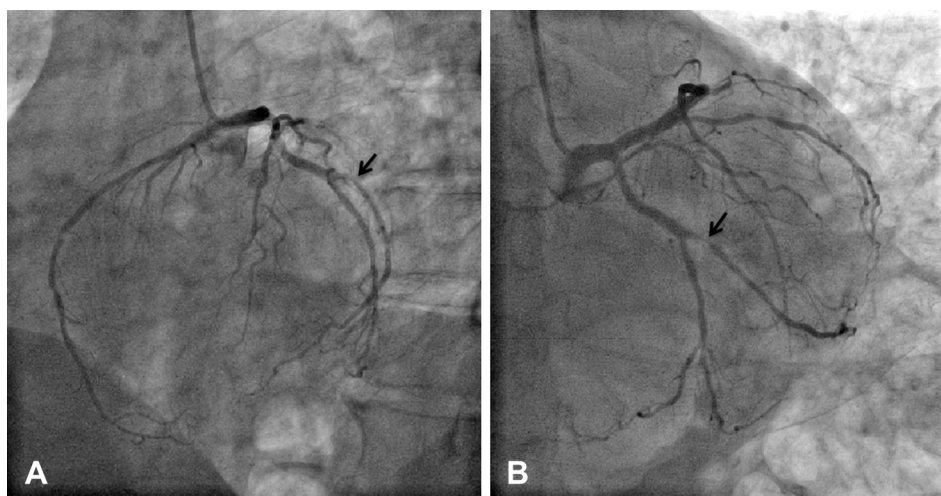


Fig. 1 – Diagnostic angiograms showing severe in-stent restenosis in Major OM stent.

(Abbott Vasc, USA) 3×16 mm was made with successful closure of the leak and containment of the cause (Fig. 3A and B). Immediately following this pericardiocentesis through subcostal approach was done using a pigtail catheter and around 250 ml of fresh blood aspirated which was auto-transfused resulting in restoration of blood pressure and vitals to within normal limits. The patient was then sent back to the intensive cardiac care unit for further observation post procedure.

Within half an hour the patient again had a precipitous fall in blood pressure with moderate collection in the pericardial space and repeat cardiac tamponade, needing further pericardial fluid aspiration. A check angiogram was immediately planned to look for any residual blood leak from the perforation site. Angiogram however revealed that previous perforation site was well sealed with the covered stent and, to our surprise, there was torrential leak of blood from distal end of a

small ramus like vessel, an artery which had not been worked upon anytime during the procedure (Fig. 4A and B) and the cause of this leak was in a way unexplained.

The leaking ramus had to be now targeted for occlusive treatment and for which intra-coronary injection of cyanoacrylate glue was considered, a technique, which in our past experience has proved to be quite reliable with instantaneous and predictable results.¹ The leaking vessel was thus accessed with a micro-catheter (Stride, Asahi Intecc Co. Ltd, Japan) over a regular PTCA wire. The wire was next removed and micro-catheter flushed with 5% dextrose solution followed by injection of 2 ml glue mixed with equal volume of lipiodol. The tiny ramus vessel occluded instantaneously at mid level with immediate stoppage of the leak into the pericardium (Fig. 5A and B). The remaining pericardial fluid was drained through in situ drainage catheter already in place. The patient was observed over next 3 days. There was no further

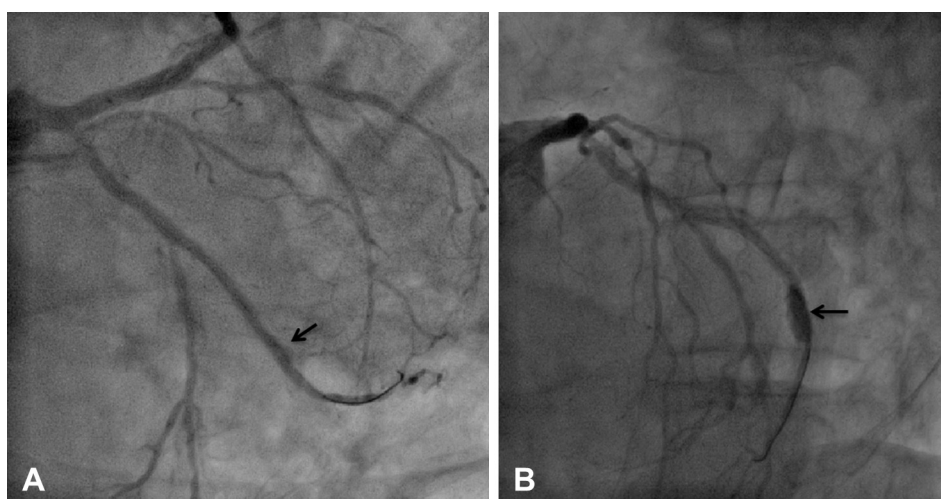


Fig. 2 – A- Slight bulge in contour (black arrow) seen at distal end of stent post dilatation. B- Progression to Ellis grade III perforation.

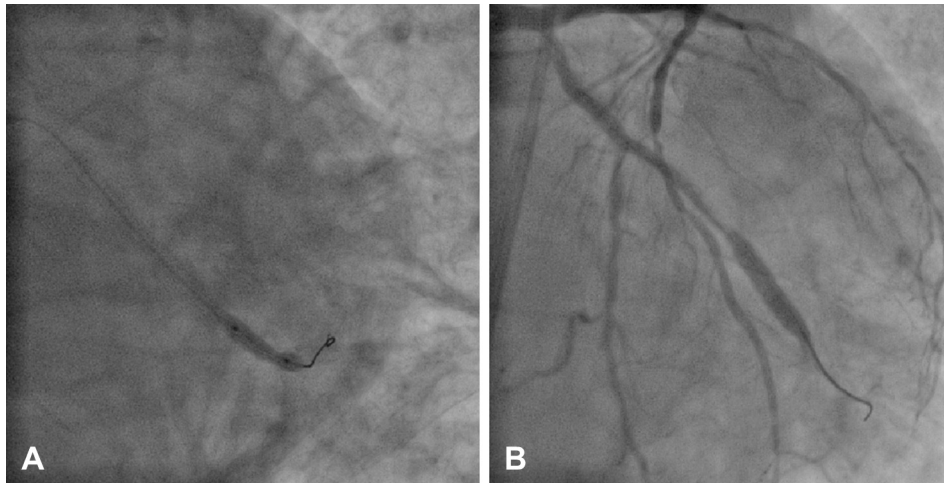


Fig. 3 – A- Covered stent Graft-master 3 × 16 mm deployed. B- No residual leak from perforation site.

collection in pericardium and his further recovery was uneventful. The patient was discharged in stable condition on the fourth day post procedure.

2. Discussion

Percutaneous Coronary Intervention (PCI) is the standard of care for obstructive CAD. With advancement in medical technology, increasingly complex procedures are being performed with increasing success but the risk of potentially lethal complications remain and coronary artery perforation (CAP)² is one such important complication secondary to coronary rupture following balloon dilatation. There are several described risk factors for CAP like older age,^{3,4} hypertension,⁵ type B or C lesions,^{5–7} chronic total occluded arteries, small vessels,^{1,6} calcified lesions, tortuous and angulated vessels, the presence of multivessel coronary disease, use of hydrophilic wires,⁸ atherectomy devices like rotablator,^{9,10} inflation with high pressure,¹¹ oversized balloons, and noncompliant

balloons. Our patient was 74 years of age, hypertensive and the balloon used to vessel diameter ratio was incidentally about 1.1 which possibly predisposed him to the perforation.

Salvage techniques for CAP including prolonged balloon inflation,¹² polytetrafluoroethylene-covered stents^{13–15} and transcatheter embolization of micro-coils,^{16,17} subcutaneous tissue,¹⁸ thrombin,¹⁹ a sterile synthetic glue,¹ polyvinyl alcohol,²⁰ or collagen.^{21,22}

Sterile intra-arterial synthetic glue as a modality to treat CAP was first described by us in 2009 in a case of RCA perforation.²¹ Leaks from small caliber vessels are not suitable for covered stents which are usually bulky and call for alternative options amongst which intra-arterial injection of sterile synthetic glue seems quite reliable with predictable results in our experience. The advantage of intra-arterial glue is immediate closure of the vessel in question, a feature which is of utmost importance while treating these situations which are life threatening emergencies. The only downside of this modality is the fact that the entire vessel closes downstream, hence the technique cannot be used for major proximal arterial leaks like the left main or proximal LAD.

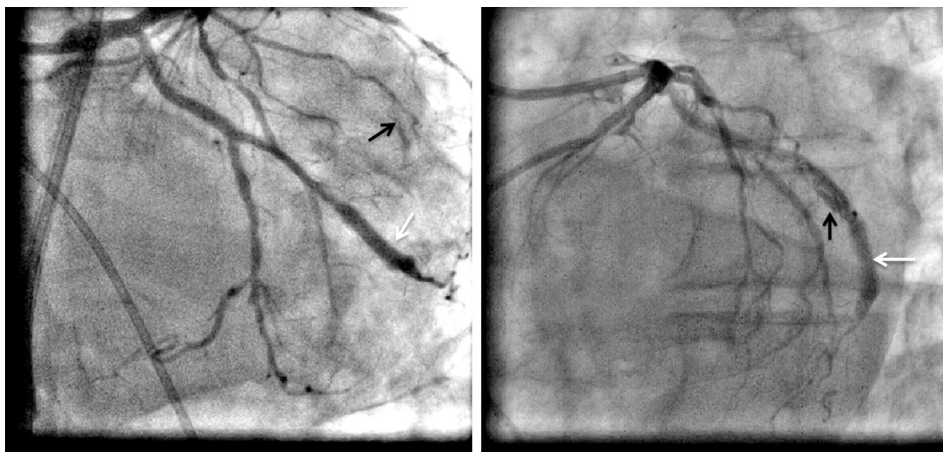

Fig. 4 – Check angiogram showing jet of contrast from tip of ramus (Black arrow) and no leak from covered stent site (white arrow).

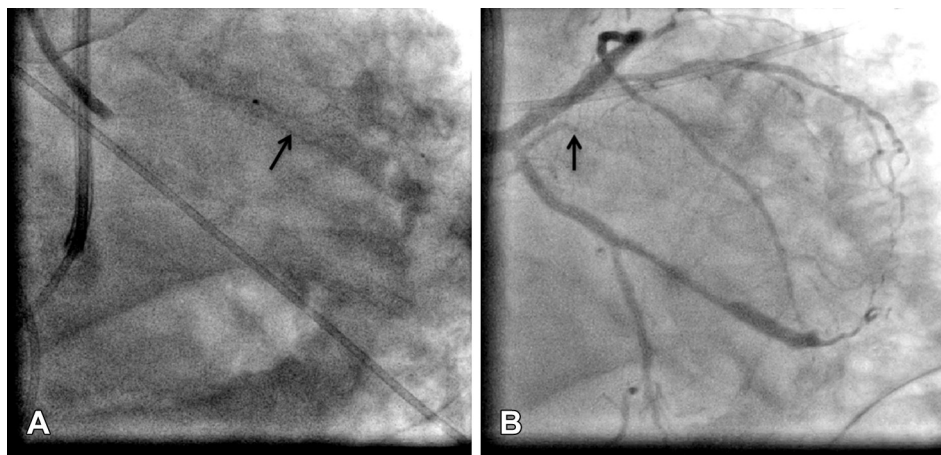


Fig. 5 – A- injection of sterile intra-arterial glue mixed with lipiodol into small ramus (black arrow). B- Complete occlusion of small ramus (Black arrow).

The odd point of our patient was the leak seen in a remote vessel i.e. a vessel which had not been worked upon at all during the procedure and hence the name 'Ricochet' given by us and that too after having successfully managed the real perforation with a covered stent. The only cause we can ascribe to this remote leak is a direct hit by the pericardiocentesis needle, a phenomenon which though possible is not well reported and hence the uniqueness of the case.

We conclude that nothing is impossible in interventional cardiology and one must be ready for any eventuality in the catheterization laboratory with intra-arterial glue being a strong handy support tool for managing such emergencies.

3. Conclusion

Coronary perforation is an uncommon but fatal complications of PCI if left untreated which needs to be identified and handled promptly. Pericardial tap done in emergency as a life saving measure in itself can lead to a new leak if done in haste. Intra-arterial glue is a reliable method to handle such complications emerging out of tiny vessel leaks which may be as devastating.

Conflicts of interest

All authors have none to declare.

REFERENCES

- Goel PK. Delayed and repeated cardiac tamponade following microleak in RCA successfully treated with intra-arterial sterile glue injection. *Catheter Cardiovasc Interv.* 2009;73:797–800.
- Chua Su-Kiat, Lee Shih-Huang, Shyu Kou-Gi, Hung Huei-Fong, Lin Sheng-Chang, Cheng Jun-Jack. Incidence, management, and clinical outcomes of procedure-related coronary artery perforation: analysis of 13,888 coronary angioplasty procedures. *Acta Cardiol Sin.* 2008;24:80–85.
- Doll JA, Nikolsky E, Stone GW, et al. Outcomes of patients with coronary artery perforation complicating percutaneous coronary intervention and correlations with the type of adjunctive antithrombotic therapy: pooled analysis from REPLACE-2, ACUITY, and HORIZONS-AMI trials. *J Interv Cardiol.* 2009;22:453–459.
- Ellis SG, Ajluni S, Arnold AZ, et al. Increased coronary perforation in the new device era: incidence, classification, management, and outcome. *Circulation.* 1994;90:2725–2730.
- Shimony A, Zahger D, Van Straten M, et al. Incidence, risk factors, management and outcomes of coronary artery perforation during percutaneous coronary intervention. *Am J Cardiol.* 2009;104:1674–1677.
- Stankovic G, Orlic D, Corvaja N, et al. Incidence, predictors, in-hospital, and late outcomes of coronary artery perforations. *Am J Cardiol.* 2004;93:213–216.
- Fasseas P, Orford JL, Panetta CJ, et al. Incidence, correlates, management, and clinical outcome of coronary perforation: analysis of 16,298 procedures. *Am Heart J.* 2004;147:140–145.
- Javaid A, Buch AN, Satler LF, et al. Management and outcomes of coronary artery perforation during percutaneous coronary intervention. *Am J Cardiol.* 2006;98:911–914.
- Dippel EJ, Kereiakes DJ, Tramuta DA, et al. Coronary perforation during percutaneous coronary intervention in the era of abciximab platelet glycoprotein IIb/IIIa blockade: an algorithm for percutaneous management. *Catheter Cardiovasc Interv.* 2001;52:279–286.
- Bittl JA, Ryan Jr TJ, Keaney Jr JF, et al. Coronary artery perforation during excimer laser coronary angioplasty: the percutaneous Excimer Laser Coronary Angioplasty Registry. *J Am Coll Cardiol.* 1993;21:1158–1165.
- Ajluni SC, Glazier S, Blankenship L, O'Neill WW, Safian RD. Perforations after percutaneous coronary interventions: clinical, angiographic, and therapeutic observations. *Cathet Cardiovasc Diagn.* 1994;32:206–212.
- Stack RS, Quigley PJ, Collins G, Phillips III HR. Perfusion balloon catheter. *Am J Cardiol.* 1988;61:77G–80G.
- Briguori C, Nishida T, Anzuini A, et al. Emergency polytetrafluoroethylene covered stent implantation to treat coronary ruptures. *Circulation.* 2000;102:3028–3031.
- Subraya RG, Tannenbaum AK. Successful sealing of perforation of saphenous vein graft by coronary stent. *Catheter Cardiovasc Interv.* 2000;50:460–462.

15. Stefanadis C, Toutouzas K, Tsiamis E, et al. Implantation of stents covered by autologous arterial grafts in human coronary arteries: a new technique. *J Invasive Cardiol*. 2000;12:7–12.
16. Mahmud E, Douglas Jr JS. Coil embolization for successful treatment of perforation of chronically occluded proximal coronary artery. *Catheter Cardiovasc Interv*. 2001;53:549–552.
17. Dorros G, Jain A, Kumar K. Management of coronary artery rupture: covered stent or microcoiled embolization. *Cathet Cardiovasc Diagn*. 1995;36:148–154.
18. Oda H, Oda M, Makiyama Y, et al. Guidewire-induced coronary artery perforation treated with transcatheter delivery of subcutaneous tissue. *Catheter Cardiovasc Interv*. 2005;66:369–374.
19. Fischell TA, Korban EH, Lauer MA. Successful treatment of distal coronary guidewire-induced perforation with balloon catheter delivery of intracoronary thrombin. *Catheter Cardiovasc Interv*. 2003;58:370–374.
20. Yoo BS, Yoon J, Lee SH, et al. Guidewire-induced coronary artery perforation treated with transcatheter injection of polyvinyl alcohol form. *Catheter Cardiovasc Interv*. 2001;52:231–234.
21. Aleong G, Jimenez-Quevedo P, Alfonso F. Collagen embolization for the successful treatment of a distal coronary artery perforation. *Catheter Cardiovasc Interv*. 2009;73:332–335.
22. Kiernan TJ, Yan BP, Ruggiero N, et al. Coronary artery perforations in the contemporary interventional era. *J Interv Cardiol*. 2009;22:350–353.