

# Preemptive pericapsular nerve group block to facilitate sitting position for neuraxial anesthesia in patients with acetabular fractures: A case series

## ABSTRACT

Acetabular fractures are uncommon types of pelvic fractures associated with restricted mobility due to severe pain. The high analgesic demands can be fulfilled by using multimodal analgesia incorporating regional analgesia. The choice of regional analgesia technique depends on the type of acetabular fracture and innervation of the affected components. We report a case series of five patients with acetabular fractures, in whom pre-emptive administration of pericapsular nerve group block provided effective analgesia to facilitate the sitting position for the neuraxial block.

**Key words:** Acetabular fractures, acute pain management, neuraxial anesthesia, PENG block, regional analgesia

## Introduction

Acetabular fracture is an uncommon type of pelvic fracture that may involve ilium, ischium, and/or pubis depending upon the fracture severity. The management of such fractures is challenging to both the orthopedic surgeons and anesthesiologists due to the complexity of fractures, severity of pain, intraoperative blood loss, and prolonged duration of surgery. The restricted mobility due to associated severe pain in acetabular fracture makes the patient prone to develop deep venous thrombosis.<sup>[1]</sup>

In our hospital, acetabular fractures are usually operated under combined spinal-epidural anesthesia (CSEA), requiring the patient to be in a sitting position. To facilitate


positioning (sitting or lateral) during neuraxial anesthesia, such patients require adequate analgesia with either intravenous analgesics or suitable regional analgesia (RA) technique covering innervations of the pain generators. In the modern era of opioid-free anesthesia, modalities supporting minimal-to-no use of opioids are always encouraged. The best modality to deal with the pain associated with acetabular fracture includes multimodal analgesia (MMA), incorporating RA as an essential component to avoid potential side-effects of opioids and other analgesics.

Various techniques like infiltration of local anesthetic (LA), supra-inguinal fascia iliaca compartment block (SIFICB),

This is an open access journal, and articles are distributed under the terms of the Creative Commons Attribution-NonCommercial-ShareAlike 4.0 License, which allows others to remix, tweak, and build upon the work non-commercially, as long as appropriate credit is given and the new creations are licensed under the identical terms.

**For reprints contact:** WKHLRPMedknow\_reprints@wolterskluwer.com

**How to cite this article:** Mistry T, Sonawane K, Raghuvanshi A, Balavenkatasubramanian J, Gurumoorthi P. Preemptive pericapsular nerve group block to facilitate sitting position for neuraxial anesthesia in patients with acetabular fractures: A case series. Saudi J Anaesth 2022;16:221-5.

Access this article online	
<b>Website:</b> www.saudija.org	<b>Quick Response Code</b> 
<b>DOI:</b> 10.4103/sja.sja_614_21	

**TUHIN MISTRY, KARTIK SONAWANE, APURVA RAGHUVANSHI, JAGANNATHAN BALAVENKATASUBRAMANIAN, PALANICHAMY GURUMOORTHY**

Department of Anaesthesiology, Ganga Medical Centre and Hospitals Pvt Ltd, Coimbatore, Tamil Nadu, India

**Address for correspondence:** Dr. Tuhin Mistry, Department of Anaesthesiology, Ganga Medical Centre and Hospitals Pvt Ltd, Coimbatore, Tamil Nadu, India.

E-mail: tm.tuhin87@gmail.com

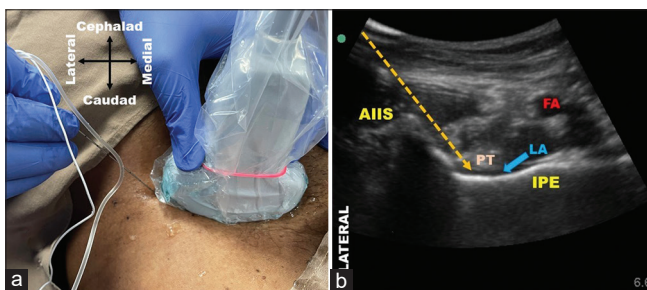
**Submitted:** 20-Aug-2021, **Revised:** 29-Aug-2021, **Accepted:** 31-Aug-2021, **Published:** 17-Mar-2022

and lumbar plexus block (LPB) have been described in the literature as a component of perioperative multimodal analgesia for acetabular surgeries.<sup>[2-4]</sup> Among the available RA techniques for hip fractures, we believe that the pericapsular nerve group (PENG) block might be suitable for obtaining desired analgesic outcomes for both resting and dynamic pain in acetabular fractures. Although the available literature encourages PENG block for hip fractures involving proximal femur,<sup>[5]</sup> there is limited evidence of its application for acetabular fractures.<sup>[6]</sup>

We report a novel application of preemptive PENG block to facilitate sitting position for the neuraxial blockade in five patients with acetabular fractures. All the patients included in this case series provided informed and written consent for the PENG block and publication of this report.

## Case Reports

A total of five patients of the American Society of Anesthesiologists (ASA) physical status I-II with acetabular fracture were included in this case series. Preoperatively, the dynamic pain score (by doing passive straight leg raise to 15-30 degrees) before block (T0) was noted using a numeric rating scale (NRS) score of 0-10 (where 0 = no pain and 10 = worst pain imaginable). Before shifting the patient to the operating room, an ultrasound-guided PENG block was performed on the affected side using the technique described by Girón-Arango *et al.*<sup>[5]</sup> A low-frequency curvilinear transducer (Sonosite rC60xi/5-2 MHz; Fujifilm SonoSite Inc., Bothell, WA, USA) was used to identify anatomical landmarks and a 20-G 100 mm nerve block needle was inserted in-plane from lateral to medial side. After negative aspiration for blood, the LA solution (28 ml 0.2% ropivacaine + 8 mg dexamethasone) was deposited between the psoas tendon and the superior pubic ramus [Figure 1a and b]. Following the block, dynamic pain scores were recorded after 15 minutes (T15) and 30 minutes (T30) using NRS inside the block room.



**Figure 1: (a) Position of curvilinear transducer and point of needle entry for PENG block; (b) Ultrasound image of PENG block; AIIS = anterior inferior iliac spine, IPE = iliopubic eminence, LA = local anesthetic, PT = psoas tendon, FA = femoral artery, yellow arrow = needle trajectory**

Inside the operating room, all patients were connected to the ASA standard monitors and placed in a sitting position with the help of assistants for the neuraxial blockade. The dynamic pain score in the sitting position (Ts) was recorded. The patient demographics and pain scores are depicted in [Table 1].

There was a significant decrease in the pain scores (both resting and dynamic) at T15 and T30 from the pain score at T0. Three patients with anterior column acetabular fracture (ACAF) could sit upright utilizing human support without any pain or discomfort for the neuraxial block. However, two patients with associated posterior column acetabular fracture (PCAF) required additional systemic analgesics (fentanyl or ketamine).

## Discussion

PENG block successfully provided effective and adequate analgesia, especially for ACAF, to make the patient sit comfortably for the neuraxial anesthesia. However, it failed to do so in patients with PCAF, which required additional analgesic support. To understand this discrepancy, background knowledge of pelvic anatomy, acetabular fractures, and innervations of the affected structures is essential.

The pelvis (pelvic girdle) is a basin-shaped complex bony structure formed by two hip bones (innominate or pelvic bones), a spade-shaped sacrum, and a coccyx (tail bone). Each hip bone comprises ilium, ischium, and pubis. All these bones formed four articulations within the pelvis: two sacroiliac joints (between ilium and sacrum), sacrococcygeal symphysis (between sacrum and coccyx), and the pubic symphysis (between two pubic bones on either side).<sup>[7]</sup> Two bony columns (anterior and posterior), forming an “inverted Y,” support the acetabulum and connect to the sacrum through a sciatic buttress [Figure 2a]. The anterior column comprises the anterior ilium (gluteus medius tubercle), anterior wall and dome, iliopectineal eminence, and lateral superior pubic ramus. The posterior column comprises a quadrilateral surface, posterior wall and dome, ischial tuberosity, and greater/lesser sciatic notches.<sup>[8]</sup>

Acetabular fractures are uncommon (three in one lakh trauma patients per year)<sup>[9]</sup> pelvic fracture involving the hip joint’s articular surface and one or two columns, one or two walls, or the roof within the pelvis. They have bimodal distribution with the younger patients due to high-energy trauma (e.g., motor vehicle accidents) and elderly patients due to low-energy trauma (e.g., fall on the floor or from height).<sup>[10]</sup> The most common type of fractures in the younger include posterior

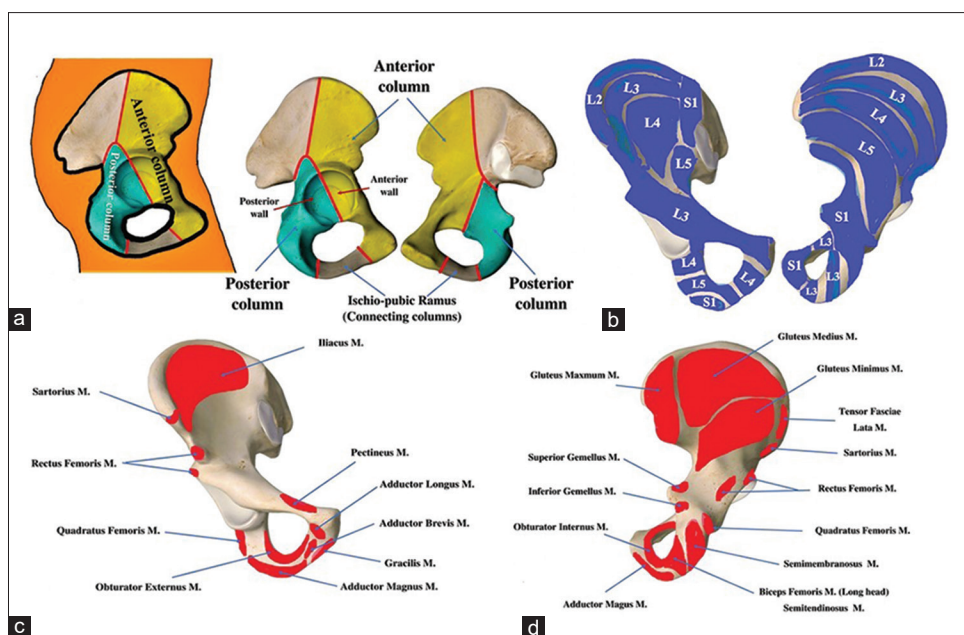


Figure 2: (a) Anterior and posterior columns of acetabulum; (b) predominant osteotome innervations by spinal segments, (c) muscle attachments on the anterior surface of the pelvis, (d) muscle attachments on the posterior surface of the pelvis; M = muscle

Table 1: Summary of clinical information

Patient	Age (years)	Sex (M/F)	ASA (I/II)	Diagnosis	Dynamic NRS before block (T0)	Dynamic NRS 15 min after block (T15)	Dynamic NRS 30 min after block (T30)	Dynamic NRS inside the operative room while in sitting position (Ts)	Additional analgesic required
1	46	M	I	Right ACAF	10	6	2	1	-
2	55	M	I	Left ACAF	08	4	1	1	-
3	39	M	I	Right ACAF	08	4	2	1	-
4	44	M	II	Right comminuted ACAF and PCAF	10	6	4	4	25 mg ketamine
5	48	M	I	Left ACAF and PCAF, superior and inferior pubic rami fracture	10	6	3	4	80 mcg fentanyl

wall or transverse type fractures, whereas the elders include anterior column, posterior hemi-transverse, or column fractures. Approximately 80.5% of acetabular fractures result from motor vehicle accidents, and 10.7% result from falls.<sup>[11]</sup>

The Judet and Letournel classification system divides acetabular fractures into 10 types (five elementary and five associated).<sup>[12]</sup> The five elementary types include posterior wall, anterior wall, posterior column, anterior column, and transverse fractures. The five associated fracture types are combinations of the elementary fractures that include transverse with the posterior wall, the posterior column with the posterior wall, T-shaped, anterior column or wall with posterior hemi-transverse, and associated both columns fracture. The associated injuries of acetabular fractures involve lower extremity (36%), lung (26%), retroperitoneal hematoma (24%), upper extremity fracture (21%), spine fracture (16%), brain (9%), spleen and liver (8% each), bladder

and vascular (5% each), kidney (3%), and bowel (2%).<sup>[13]</sup> The incidence of sciatic nerve injury following acetabular fractures has been reported to be as high as 30%.<sup>[14]</sup>

The conservative management (for nondisplaced acetabular fractures) includes traction, pelvic binder, early mobilization with variable weight-bearing. The surgical management (for displaced acetabular fracture) includes open reduction and internal fixation or sometimes primary hip arthroplasty. Due to associated severe pain, acetabular fractures have higher analgesic demands, which can be fulfilled by MMA incorporating RA as an adjuvant. The choice of the RA for an acetabular fracture depends on the type of fracture and its sensory innervation [Figure 2b]. The sensory innervation of the anterior column is derived from the lumbar plexus through its branches, which also supply muscles attached to the anterior column [Figure 2c] and anterior capsule of the hip joint. Similarly, the sensory innervation of the

posterior column is derived from the sacral plexus through its branches, which also supply muscles attached [Figure 2d] to the posterior column and posterior capsule of the hip joint.

The anterior capsule of the hip joint is richly innervated compared to the posterior capsule. The former is mainly nociceptive, whereas the latter is mainly proprioceptive.<sup>[5]</sup> Due to this innervation pattern, most of the RA options targets branches supplying the anterior capsule. The PENG block involves LA deposition between the anterior inferior iliac spine and iliopectineal eminence, directly targeting the articular branches of femoral and accessory obturator nerves.<sup>[5]</sup> It also indirectly involves the obturator nerve through the LA spread to the sub-pectineal plane. Thus, it provides osseous sensory analgesia due to LA spread along the adjacent bony surface. SIFICB and LPB have been reported to provide perioperative analgesia for patients undergoing acetabular fracture fixation under general anesthesia (GA).<sup>[3,4]</sup> However, inadvertent quadriceps weakness or sparing of obturator nerve can happen with SIFICB and LPB, and lateral position is required to perform LPB. The analgesic coverage of both blocks and PENG block is almost similar as they target specific innervation of the anterior capsule of the hip joint. Hence, they might be equally effective in providing analgesia for ACAF. Also, both blocks may be equally ineffective for PCAF like the PENG block as they do not cover posterior or sacral plexus innervations.

In our cases, the PENG block provided adequate analgesia in patients with ACAF, facilitating positioning for the neuraxial block. In contrast, it failed to provide the same analgesic quality in patients with PCAF, requiring additional systemic analgesics. It could be due to possible sparing of the posterior column innervations by the PENG block. The PENG block analgesic coverage is volume-dependent as higher volumes (30-40 ml) have a comprehensive analgesic coverage than lower volumes (10-20 ml). For pre-emptive PENG block to facilitate sitting position for the neuraxial blockade, 20-30 ml of LA volume is sufficient to provide required joint analgesia. However, higher LA volumes (30-40 ml) may be needed for intraoperative analgesia to cover all required innervations (dermatomes, osteotomes, and myotomes). Bilal *et al.*<sup>[6]</sup> reported successful use of high-volume (30 ml) PENG block for intraoperative analgesia in two patients undergoing open reduction and internal fixation of acetabular fractures under GA.

In conclusion, we advocate that the PENG block might be a suitable alternative or adjunct to pharmacologic therapy for providing analgesia before positioning for neuraxial blockade

in patients with acetabular fractures. Although PENG block seems to be a promising option, a more extensive study is needed to support its safety, efficacy, and reliability.

#### Declaration of patient consent

The authors certify that they have obtained all appropriate patient consent forms. In the form the patient(s) has/have given his/her/their consent for his/her/their images and other clinical information to be reported in the journal. The patients understand that their names and initials will not be published and due efforts will be made to conceal their identity, but anonymity cannot be guaranteed.

#### Financial support and sponsorship

Nil.

#### Conflicts of interest

There are no conflicts of interest.

#### References

1. Wang P, Kandemir U, Zhang B, Wang B, Li J, Zhuang Y, *et al.* Incidence and risk factors of deep vein thrombosis in patients with pelvic and acetabular fractures. *Clin Appl Thromb Hemost* 2019;25:1076029619845066.
2. Langworthy MJ, Sanzone AG. Multimodal pain strategies including liposomal bupivacaine for isolated acetabular fracture surgery. *J Orthop Trauma* 2018;32(Suppl 2):S11-5.
3. Vergari A, Frassanito L, Tamburello E, Nestorini R, Sala FD, Lais G, *et al.* Supra-inguinal fascia iliaca compartment block for postoperative analgesia after Acetabular fracture surgery. *Injury* 2020;51:2996-8.
4. Chelly JE, Casati A, Al-Samsam T, Coupe K, Criswell A, Tucker J. Continuous lumbar plexus block for acute postoperative pain management after open reduction and internal fixation of acetabular fractures. *J Orthop Trauma* 2003;17:362-7.
5. Girón-Arango L, Peng PWH, Chin KJ, Brull R, Perlas A. Pericapsular nerve group (PENG) block for hip fracture. *Reg Anesth Pain Med* 2018;43:859-63.
6. Bilal B, Öksüz G, Boran ÖF, Topak D, Doğar F. High volume pericapsular nerve group (PENG) block for acetabular fracture surgery: A new horizon for novel block. *J Clin Anesth* 2020;62:109702.
7. Fisher M, Bordoni B. Anatomy, Bony Pelvis and Lower Limb, Pelvic Joints. [Updated 2021 Jul 26]. In: StatPearls [Internet]. Treasure Island (FL): StatPearls Publishing; 2021. Available from: <https://www.ncbi.nlm.nih.gov/books/NBK538523/>. [Last accessed on 2021 Aug 29].
8. Lawrence DA, Menn K, Baumgaertner M, Haims AH. Acetabular fractures: Anatomic and clinical considerations. *AJR Am J Roentgenol* 2013;201:W425-36.
9. Laird A, Keating JF. Acetabular fractures: A 16-year prospective epidemiological study. *J Bone Joint Surg (Br)* 2005;87:969-73.
10. Wu H, Shao Q, Shang R, Song C, Liu X, Cai X. Open reduction and internal fixation of quadrilateral plate fractures in the elderly: Association between initial fracture pattern and outcomes. *BMC Musculoskelet Disord* 2021;22:122.
11. Negrin LL, Seligson D. Results of 167 consecutive cases of acetabular fractures using the Kocher-Langenbeck approach: A case series. *J Orthop Surg Res* 2017;12:66.
12. Alton TB, Gee AO. Classifications in brief: Letournel classification for acetabular fractures. *Clin Orthop Relat Res* 2014;472:35-8.

13. Porter SE, Schroeder AC, Dzigan SS, Graves ML, Zhang L, Russell GV. Acetabular fracture patterns and their associated injuries. *J Orthop Trauma* 2008;22:165-70.
14. Issack PS, Helfet DL. Sciatic nerve injury associated with acetabular fractures. *HSS J* 2009;5:12-8.
15. Bugada D, Bellini V, Lorini LF, Mariano ER. Update on selective regional analgesia for hip surgery patients. *Anesthesiol Clin* 2018;36:403-15.