

Carotid artery stent continued expansion days after deployment, without post stent deployment angioplasty

Umair Qazi, Tammam Obeid, Isibor Arhuidese, Mahmoud Malas

Department of Surgery, The Johns Hopkins University, Baltimore, MD, USA

Abstract

This is a carotid artery stent (CAS) case report, which avoids post-stent deployment angioplasty (Post-SDA), with duplex confirmed continued stent expansion at 1, 3 and 30-day post deployment. This report confirms that self-expanding nitinol stents in the carotid artery may not require Post-SDA. We believe CAS can be performed without Post-SDA, which helps reduce the occurrence of intraoperative hemodynamic depression.

Case Report

A pleasant 77-year old female experienced acute left hand weakness following coronary artery stenting for the treatment of acute myocardial infarction. Magnetic resonance imaging (MRI) confirmed bilateral cerebral and right cerebellar infarcts. Echocardiogram showed severe aortic arch atherosclerosis with mobile thrombus. A carotid artery duplex ultrasound was performed which revealed a peak systolic velocity (PSV) of 440 cm/s and an end diastolic velocity (EDV) of 162 cm/s in the left internal carotid artery (ICA), the left ICA to common carotid artery (CCA) ratio was 5.7 consistent with 70-99% stenosis. Because of the bilateral hemisphere embolic events and the fresh thrombus in the arch the patient was started on warfarin after an intravenous heparin bridge as well as aspirin and clopidogrel. Three month later patient presented with left facial droop. MRI revealed new acute infarcts in the left occipital lobe with subacute infarcts noted in the left periventricular region and corpus callosum, despite been therapeutic on warfarin. Duplex ultrasound showed an increase in left ICA PSV from the 440 cm/s to 605 cm/s, end diastolic velocity increased from 162 cm/s to 236 cm/s and ratio from 5.7 to 10.1 (Figure 1A).

Procedure

We decided to proceed with left carotid artery stent (CAS) instead of carotid endarterectomy (CEA) given the recent myocardial infarction. Due to severe arch disease and the severity of stenosis, we believed a trans-cervical approach with flow reversal cerebral protection would be the safest for the patient. After proper consent, the patient was enrolled in the ROADSTER plus study *Investigation Of Flow Altered, Short Transcervical Carotid Artery Stenting In Patients With Significant Carotid Artery Disease With Filter*.

The patient underwent successful transcervical carotid artery stenting procedure using the michi flow reversal system. We did perform pre-stent angioplasty once the flow reversal system was engaged. We did however opt not to do any post-stent deployment angioplasty. The completion carotid angiogram showed good results with a 30% residual stenosis in the left ICA. There was a remarkable improvement in the flow into the anterior and middle cerebral artery on completion cerebral angiogram. Performing the entire procedure under local anesthesia, we are able to monitor the patient neurological status throughout the case. The patient remained neurologically and hemodynamically stable. She was transferred in stable condition to the neurological critical care unit.

Post-operative course

The patient experienced stable course with no adverse events. Post-operative duplex ultrasound on the day of surgery revealed proximal ICA PSV of 445 cm/s, EDV of 139 cm/s and ratio of 3.53 (severe 70-99% stenosis) (Figure 1B). Patient remained hospitalized under neurology for anticoagulation bridge. On postoperative day 3 the duplex was repeated, which revealed a significant drop in the velocities, with PSV 220 cm/s, EDV 64 cm/s, ratio of 1.5 (moderate 50-69% stenosis) (Figure 1C). Patient was discharged home in stable condition.

On 30-day follow-up visit the patient reported no complaints and had an intact neurological exam. Carotid duplex ultrasound showed further reduction in PSV to 126 cm/s, EDV to 41 cm/s and ratio of 1.05 indicating complete stent expansions (Figure 1D).

Figure 2A shows steady decrease in PSV and EDV over 4-weeks post operatively, while Figure 2B shows ipsilateral ICA/CCA ratio indicating complete self-expansion without the need of post-stent deployment angioplasty (Post-SDA).

Correspondence: Mahmoud B. Malas, Johns Hopkins Bayview Medical Center, 4940 Eastern Ave, Building A, 5th Floor, Baltimore, MD 21224 USA.
Tel.: 41.550.4335 - Fax: 410.550.1274.
E-mail: uqazil@jhmi.edu

Key words: Carotid disease; carotid artery stenting; hemodynamic depression.

Received for publication: 23 February 2015.

Accepted for publication: 23 June 2015.

This work is licensed under a Creative Commons Attribution NonCommercial 3.0 License (CC BY-NC 3.0).

©Copyright U. Qazi et al., 2015
Licensee PAGEPress, Italy
Clinics and Practice 2015; 5:767
doi:10.4081/cp.2015.767

Discussion

Carotid artery stenting is now considered as an acceptable method of treatment of carotid disease for stroke prevention. Stent expansion over time was first observed in biliary stents.¹ It has been shown in coronary stents^{2,3} and also in carotid cases.^{4,5} Our case report confirms stent expansion in the carotid artery with the use of carotid duplex ultrasound.

Currently degree of stenosis is our best method to determine whether an asymptomatic patient needs an intervention, however, resolving the stenosis is not how we prevent stroke. CEA remain the gold standard treatment of severe carotid artery stenosis because it physically removes the source the emboli. CAS has been proven to be effective in preventing stroke because it stabilizes the plaque and not because it resolves the stenosis.

Conclusions

This report confirms that self-expanding nitinol stents may not require Post-SDA. These stents continue to expand days after deployment, thus reducing residual stenosis. Treating the underlying pathophysiology in carotid disease and not the radiological findings on angiogram will reduce the risk of hemodynamic instability and stroke associated with carotid stenting and improves patients' outcomes.

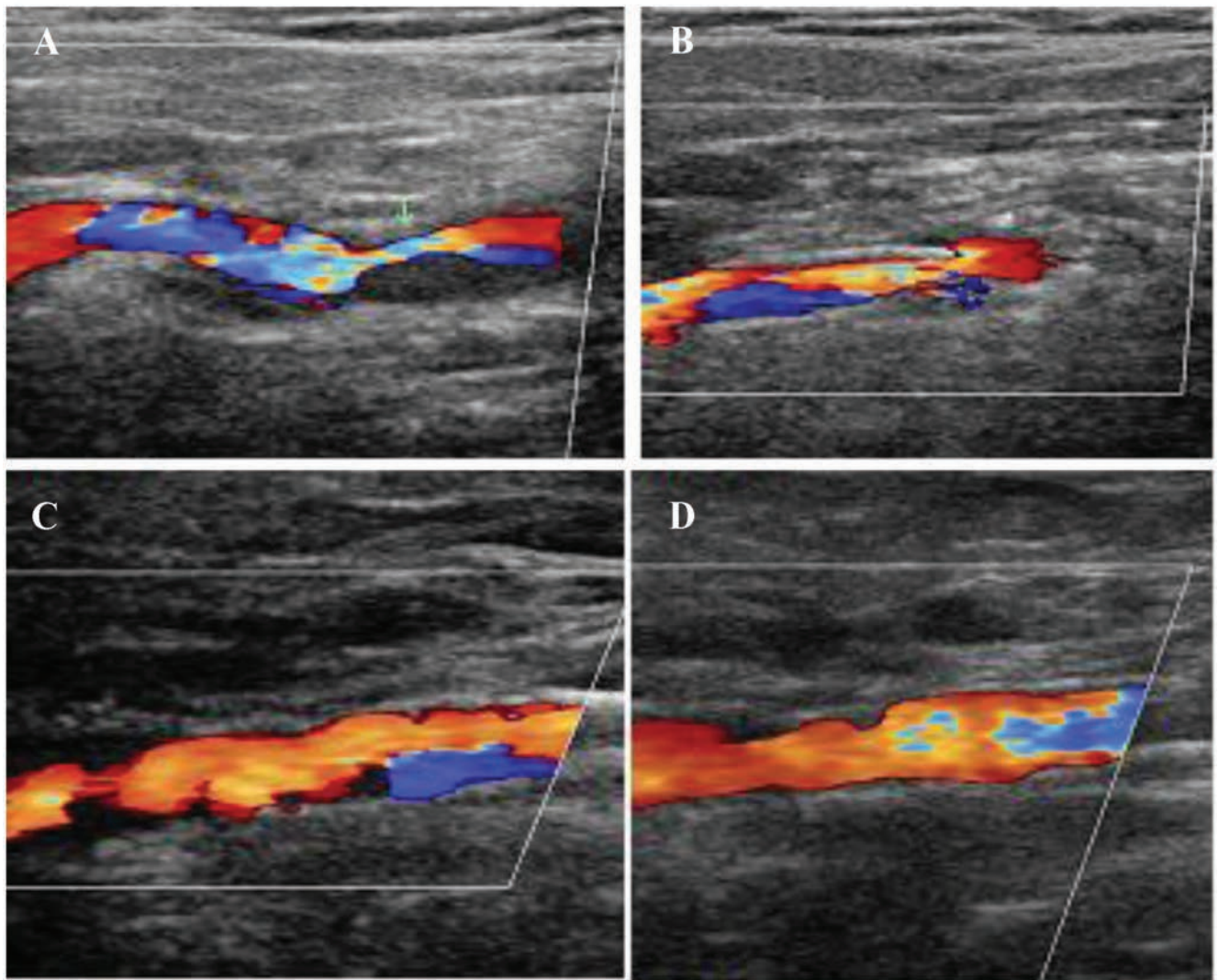


Figure 1. Duplex ultrasound images: A) pre-operative; B) post-operative day-1; C) post-operative day-3; D) post-operative day-30.

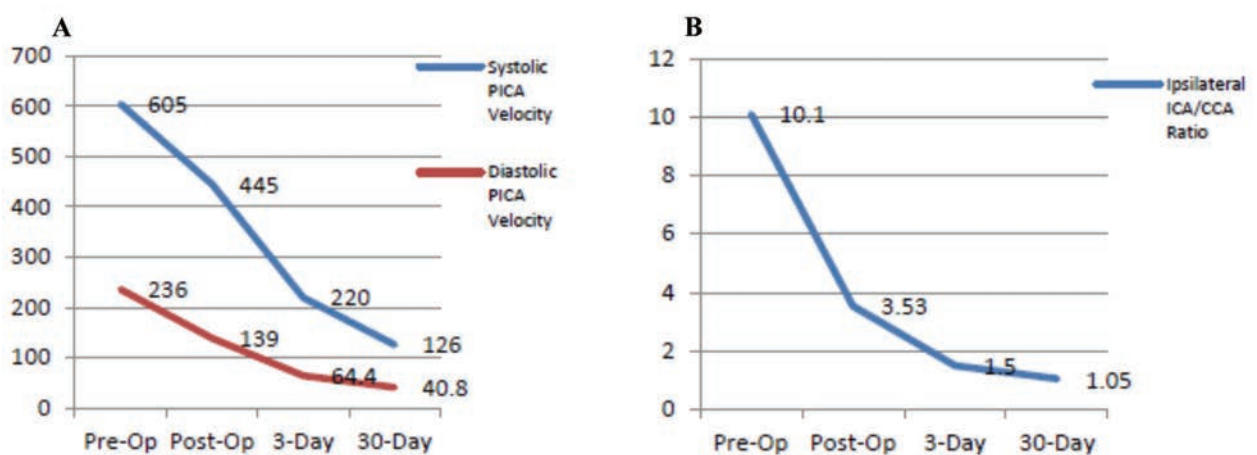


Figure 2. Complete stent self-expansion without the need of post stent deployment angioplasty: A) showing steady decrease in peak systolic and end diastolic velocity over 4-week post-operatively; B) showing ipsilateral internal/common carotid artery ratio over 4-week post-operatively.

References

1. Men S, Hekimoglu B, Kaderoglu H, et al. Palliation of malignant obstructive jaundice. Use of self-expandable metal stents. *Acta Radiol* 1996;37:259-66.
2. Lownie SP, Pelz DM, Lee DH, et al. Efficacy of treatment of severe carotid bifurcation stenosis by using self-expanding stents without deliberate use of angioplasty balloons. *AJNR Am J Neuroradiol* 2005;26:1241-8.
3. Spacek M, Zimolova P, Veselka J. Carotid artery stenting without post-dilation. *J Interv Cardiol* 2012;25:190-6.
4. Roguin A, Grenadier E, Linn S, et al. Continued expansion of the nitinol self-expanding coronary stent: angiographic analysis and 1-year clinical follow-up. *Am Heart J* 1999;138:326-33.
5. Von Birgelen C, Airiian SG, De Feyter PJ, et al. Coronary wall stents show significant late, post procedural expansion despite implantation with adjunct high-pressure balloon inflations. *Am J Cardiol* 1998;82:129-34.