

A complex dissected chronic occlusion: targeted balloon dilatation of false lumen to access true lumen, combined localized subintimal tracking and re-entry, parallel wire, contralateral injection and a useful antegrade lumen re-entry technique

Farrukh Hussain, Mehrdad Golian, James W. Tam

St. Boniface General Hospital, University of Manitoba, Canada

Abstract

Chronic total occlusion (CTO) angioplasty is one of the most challenging procedures remaining for the interventional operator. Recanalizing CTOs can improve exercise capacity, symptoms, left ventricular function and possibly reduce mortality. Multiple strategies such as escalating wire, parallel wire, see-saw, contralateral injection, subintimal tracking and re-entry (STAR), retrograde wire techniques (controlled antegrade retrograde subintimal tracking, CART), reverse CART, confluent balloon, rendezvous in coronary, and other techniques have all been described. Selection of the most appropriate approach is based on assessment of vessel course, length of occluded segment, presence of bridging collaterals, presence of bifurcating side branches at the occlusion site, and other variables. Today, with significant operator expertise and the use of available techniques, the literature reports a 50-95% success rate for recanalizing CTOs.

Introduction

Chronic total occlusion (CTO) angioplasty is one of the most challenging procedures remaining for the interventional operator. Recanalizing CTOs can improve exercise capacity, symptoms, left ventricular function and possibly reduce mortality.^{1,2} Many strategies, such as escalating wire, parallel wire, see-saw, contralateral injection, subintimal tracking and re-entry (STAR), retrograde wire techniques (controlled antegrade retrograde subintimal tracking, CART), reverse CART, confluent balloon, rendezvous in coronary, and other techniques, have been described.¹⁻¹⁶ Selection of the most appropriate approach is based on assessment of vessel course, length of occluded segment, presence of bridging collaterals, presence of bifurcating side branches at the occlusion site and other variables. Today, with significant operator expertise and the use of available techniques, the literature reports a 50-95% success rate for recanalizing CTOs.¹⁻⁵

We describe the use of a variety of previously described techniques, including STAR, parallel wire, and contralateral injection techniques to attempt a complex dissected CTO. After failure of these techniques, we successfully performed a high-risk maneuver described in peripheral angioplasty literature of aggressive dilation and perforation of the created false lumen to allow access to the true lumen for recanalization without loss of major branches.¹⁷ Although false lumen balloon dilatation is not completely novel in itself (it is, in fact, used in the CART technique) its use to avoid side branch loss and allow earlier or more proximal re-entry into true lumen has, to our knowledge, not yet been described in detail.

Case Report

A 54-year old male smoker with a history of hypertension presented with a 6-month history of progressive angina culminating in admission with prolonged episodes of angina post exercise. Electrocardiography revealed normal sinus rhythm with inferior pathological Q-waves. Echocardiography revealed hypokinesis of the inferobasal wall. He was subsequently referred for coronary angiography. The body of the left anterior descending (LAD) and left circumflex (LCx) arteries had minimal disease. A small caliber diagonal vessel had a severe lesion best served with medical therapy. Excellent Rentrop grade III collaterals were present to the right coronary artery (RCA) branches culminating at the crux (Figure 1). The native RCA was dominant and had a segment 3 occlusion with the appearance of a possible wedge-like linear dissection and a discreet false lumen observed post occlusion (Figure 2).

A 6 French JR4 guider was engaged into the RCA and then a 5 French diagnostic catheter was placed in the left main coronary artery for contralateral guidance. A Whisper MSTTM (Abbott Vascular Inc.) followed by a Fielder XTTM (ASAHI, Abbott Vascular Inc.) wire were unsuccessful in crossing this apparently dissected CTO. Subsequently, a MiracleBros 6[®] (ASAHI, Abbott Vascular Inc.) CTO wire was utilized, and initially crossed into the established proximal false lumen (Figure 3). The MiracleBros 6 wire was, with significant difficulty, gradually manipulated into the posterior descending vessel branch distally, and a second soft wire was easily tracked along the course of the Miracle 6 wire. After a contralateral test shot to ensure luminal placement of both wires, the Miracle 6 wire was pulled back in order to avoid distal perforation (Figure 4). Initially, a 2.0 mm balloon would not cross the occlusion. Therefore, a 1.25x6 mm non-compliant Sprinter[®] Legend (Medtronic Inc.) bal-

Correspondence: Farrukh Hussain, Cardiac Catheterization Lab., St. Boniface General Hospital, University of Manitoba, Canada. Tel. +1.204.237.2023 - Fax: +1.204.233.2157. E-mail: fhussain@sbgh.mb.ca

Key words: percutaneous coronary intervention, chronic total occlusion.

Received for publication: 5 December 2011.

Revision received: 4 March 2012.

Accepted for publication: 5 March 2012.

This work is licensed under a Creative Commons Attribution NonCommercial 3.0 License (CC BY-NC 3.0).

©Copyright F. Hussain et al., 2012
Licensee PAGEPress, Italy
Heart International 2012; 7:e7
doi:10.4081/hi.2012.e7

loon was used to dilate the occluded segment followed by a 2.0×15 mm balloon. After balloon dilatation, only thrombolysis in myocardial infarction (TIMI) grades I-II flow was achieved. The balloon was not able to traverse the crux of the vessel into the posterior descending artery (PDA) even after repeated attempts. On angiography, it appeared that the wire had continued into a false subintimal lumen from the beginning of the CTO and then re-entered into the true lumen distally at the crux (STAR technique without the wire knuckling component) with access to both the PDA and posterolateral branches (Figure 5). A separate contrast-filled true lumen could be visualized in the distal RCA on the inferior border of the vessel below the subintimal plane due to retrograde contrast filling from the PDA (Figure 5). No balloons were able to reach the crux since all would catch at the distal re-entry site. Multiple parallel wires including Miracle wires were used to attempt earlier re-entry to true lumen in the distal RCA so as not to compromise the PDA or posterolateral branches by shifting the dissection plane across one of the major branches during stent placement. However, all wires kept crossing into the previously established subintimal plane. Intravascular ultrasound (IVUS) guided earlier pre-crux wire re-entry into true lumen was not thought to be wise at this juncture as no catheter would move beyond the crux region and imaging for re-entry was required fairly distal in the vessel, risking extension of the subintimal plane further into the PDA or posterolateral vessel.

We had limited operator familiarity with retrograde techniques for the CART or reverse CART techniques, so these were not utilized. Based on previous peripheral angioplasty literature and the retrograde confluence balloon techniques, we attempted to dilate more aggressively with 2.25 and 2.5 mm balloons halfway into the false lumen with the hope of either rupturing/perforating the intima and allowing entry back into true lumen, or disrupting microchannels and loose fibrous tissue and opening a proximal true-distal true lumen connection (Figure 6).^{14,17} At this point, the balloon dilations in the false lumen appeared to open a new channel toward the inferior aspect of the vessel allowing easy wiring through a shorter segment of false channel, more proximal to the crux bifurcation, allowing access to the true lumen more proximally in the vessel (Figure 7). The first wire was repositioned distally into the posterolateral branch to avoid confusion and the second wire was left in the PDA. Further balloon inflations were performed over this second wire as opposed to the first wire, restoring TIMI III flow for the first time, since the vessel flow was no longer impeded by a long subintimal channel as before. Over this second wire, the bal-

loons would easily cross beyond the crux into the PDA, unlike over the first wire that was caught at the crux in the subintimal plane. Over this second wire, two drug eluting stents (3.0×28 mm and 3.5×28 mm) were subsequently deployed in an overlapping fashion obtaining an excellent angiographic result with completely preserved distal branches (Figures 8 and 9). The patient remains asymptomatic with good exercise tolerance at 3-month clinical follow up.

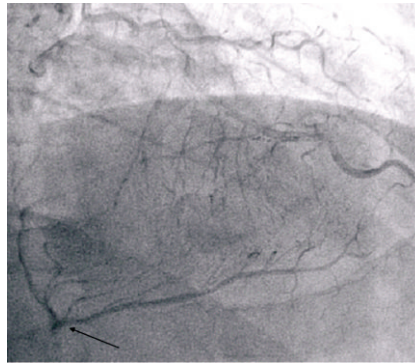


Figure 1. Rentrop grade III collaterals from left coronary to distal right coronary artery till crux of vessel.

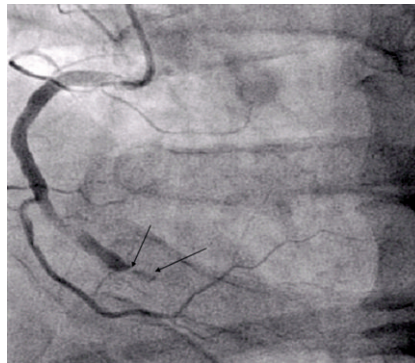


Figure 2. Dissected chronic total occlusion with linear defect followed by weak opacification of distal false lumen.

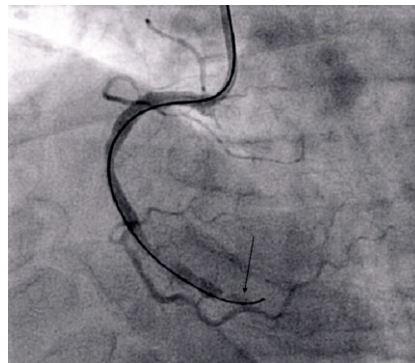


Figure 3. MiracleBros 6 wire in false lumen of chronic total occlusion.

Discussion

Contemporary CTO negotiation strategies, techniques and equipment have progressed rapidly over the last few years. With antegrade dedicated CTO wires, parallel wire, see-saw, IVUS guidance, Tornus, STAR technique and the subsequent surge in retrograde techniques

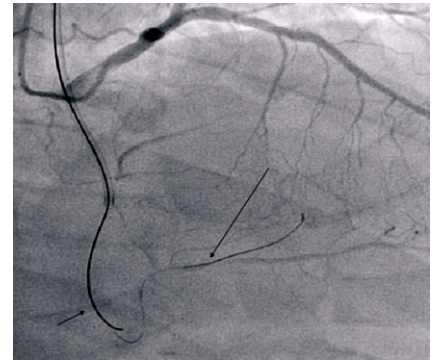


Figure 4. Contralateral injection demonstrating second soft wire in true lumen of branch of posterior descending vessel with MiracleBros 6 wire pulled back.

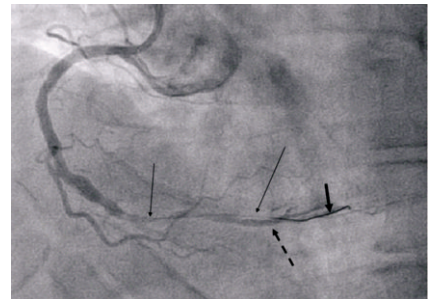


Figure 5. Right coronary artery after dilation with a 1.25 mm balloon demonstrating the false lumen initial course (thin arrows) of the wire till the crux and subsequent re-entry into true lumen beyond crux (thick arrow), demonstrating true lumen of distal right coronary artery on inferior border of vessel (hyphenated arrow).

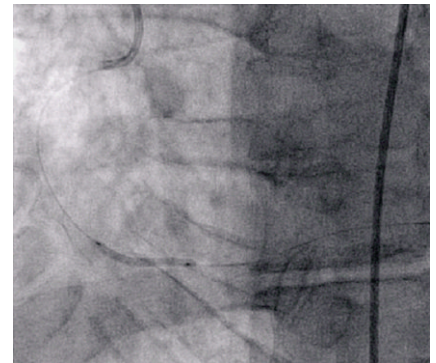


Figure 6. 2.5 mm balloon inflation in false lumen to allow rupture into true lumen.

(CART, reverse CART, knuckle wire) and others, the armamentarium for tackling CTOs continues to grow.¹⁻¹⁶ However, the most important factors determining success in complex CTOs remain operator experience, patience and perseverance. The intentional creation of false antegrade and retrograde lumens to create subintimal vessel courses is well described in the peripheral angioplasty literature and in descriptions of the STAR and CART/reverse CART techniques.^{11-14,17} Some of the disadvantages of the routine STAR technique may include potential loss of side branches, longer stent length requirement, risk of vessel perforation, and stent thrombosis.^{8,9} It is, however, a unique and very useful tool to tackle difficult CTOs and has contributed both technically and conceptually to important advances made in this field, being a potential set-up for the newer CART technique.

Histological studies of CTOs have shown small microchannels (100-200 μm) in the center of the occlusion for *younger* CTOs, whereas these microchannels are often found to connect the lumen to the vasa vasorum for *older* CTOs, often leading to subintimal wire tracking with antegrade wiring for these more established occlusions.¹⁸ Other CTOs have been found to harbor masses of loose fibrous tissue that may potentially disrupt balloon inflations, allowing wire penetration.¹⁸ Peripheral angioplasty literature has described balloon angioplasty of false lumens for lower extremity STAR technique angioplasty that may allow rupture of the intima and facilitate re-entry into the true lumen.¹⁷ The confluent balloon technique described by Wu *et al.* describes the placement of an antegrade false lumen balloon catheter with a simultaneous placement of a retrograde balloon catheter in a separate false lumen generated retrogradely.¹⁴ After placement of both balloons at the same longitudinal position, the authors describe the creation of a confluent lumen by simultaneous balloon inflation to allow rupture of both false lumens into each other.¹⁴

We have described a novel case of dilation of a false lumen channel to allow rupture into the true lumen and stenting without side branch loss. This is especially important with RCA CTOs that are distal and may involve the crux where side branch loss is not tolerable, unlike acute marginal loss in the mid- or proximal-RCA that is often better tolerated. This is a high-risk maneuver that may cause false lumen extension/enlargement with loss of hetero-collaterals, preventing wire re-entry if intimal rupture or disruption is not successfully accomplished with this method or even, less commonly, perforation. We certainly do not recommend this method as a mainstay or first-line approach and it should be reserved as an end-stage option. Calcification of the intima

and degree of rigidity of the CTO may determine the success of this maneuver in accomplishing intimal rupture. Certainly, re-entry may not always be successfully established. Operator experience and ability to deal with the possible complications that may ensue, such as perforation, false lumen extension and compromised side branch, is mandatory before attempting such an approach. IVUS guided re-entry, if sufficient distal vessel prior to bifurcation is available (not the case here), utilization of other re-entry equipment such as the StingrayTM catheter (Bridgepoint Medical Inc.), and retrograde recovery techniques, if available at the center, may be more established methods that should be used first. Other techniques that have been well described include the mini-STAR technique where a microcatheter is advanced to the proximal cap of the occlusion and a Fielder family wire (Asahi Intecc, Nagoya, Japan) with a 40-50° first curve and a 15-20° second curve 3-5 mm proximal to the tip is used to navigate through microchannels or, alternatively, assumes a J-shape configuration and knuckles through a subintimal plane re-entering true lumen distally.¹⁹ In a single center study, this technique yielded a high success rate when other conventional techniques had failed.¹⁹ An alternative limited antegrade subadventitial technique (LAST) also limits the amount of subadventitial extraluminal tracking to the region of the chronic total occlusion.²⁰ Furthermore, the Venture wire control catheter (St Jude, Minneapolis, MN, USA) has been used both as a device for wire support at the site of proximal cap entry and, more importantly, due to its ability to form angulation, has been described for distal true lumen re-entry, both with routine CTO wires and together with the Stingray 0.0035 inch tapered tip stiff wire for luminal re-entry, especially in cases of occlusive in-stent restenosis CTOs.²¹⁻²³ A novel technique described to enter the proximal cap for challenging CTOs has been the *open sesame* technique. There are some similarities between our balloon rupture technique and the plaque shift theorized with the *open sesame* technique that allows for proximal cap penetration. The *open sesame* technique essentially requires a stiff wire or balloon to be placed in the ostium or proximal segment of a branch (which is ideally 90° angulated) which is situated at the proximal cap.²⁴ Saito theorizes that this may favorably shift plaque or create an opening in the proximal cap of CTOs with branches to allow subsequent wire penetration with dedicated CTO wires.²⁴ Clearly, our method should only be used as a last resort, as complete collapse of the true lumen may occur making further wiring impossible. We would recommend the use of many of the routine CTO techniques, as well as one or a combination of the above more established techniques, prior to

embarking on our high-risk *no option* method described here. Surgical advice and backup is always recommended in complex cases such as these since bailout surgical intervention in case of catastrophic perforation or infarction may be a valuable option.

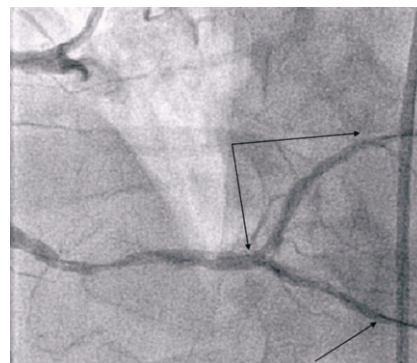


Figure 7. Top wire in posterolateral vessel (double arrow) through false lumen proximally with distal in true lumen, second wire now through earlier re-entry into true lumen in distal right coronary artery positioned distally in posterior descending vessel (bottom arrow); this wire allowed easy tracking of balloons into branches.

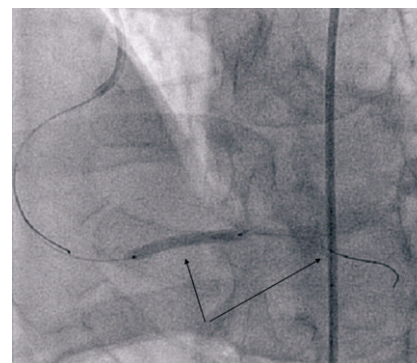


Figure 8. First stent deployed at crux of right coronary artery over posterior descending vessel wire.

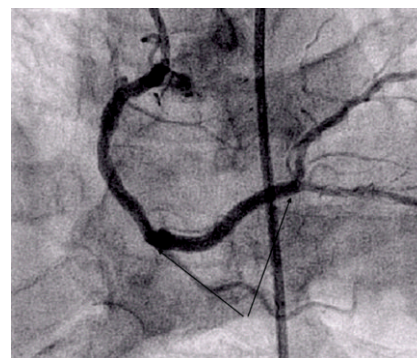


Figure 9. Result post 2 drug eluting stent implantation over posterior descending vessel wire with completely preserved branches and thrombolysis in myocardial infarction 3 flow.

Conclusion

We describe a strategy of balloon dilatation of false lumen subintimal entry to allow intimal rupture and re-entry into true lumen in case of intentional or inadvertent STAR technique for complex antegrade CTO negotiation. The aim was to allow distal side branch preservation for more complete revascularization and to minimize false lumen stenting, hopefully reducing perforation risk. Although false lumen balloon dilatation has been previously described in the CART technique, targeted false lumen inflation to allow earlier re-entry and prevent side branch loss has not yet, to our knowledge, been described. Given the risks involved, this technique should be kept as a last step option in the hands of experienced operators. This report will hopefully make a small contribution to the evergrowing armamentarium of CTO techniques and equipment.

References

- Joyal D, Affialo J, Rinfret S. Effectiveness of recanalization of chronic total occlusions: a systematic review and meta-analysis. *Am Heart J* 2010;160:179-87.
- Genereux P, Dangas G. Antegrade, retrograde, and combination strategies for chronic total occlusions. *Curr Cardiol Rep* 2010;12:429-39.
- Grantham JA, Marso SP, Spertus J, et al. Chronic total occlusion angioplasty in the United States. *J Am Coll Cardiol Intv* 2009;2:479-86.
- Shah PB. Management of coronary chronic total occlusion. *Circulation* 2011;123:1780-4.
- Weisz G, Moses JW. Contemporary principles of coronary chronic total occlusion recanalization. *Catheter Cardiovasc Interv* 2010;75:S21-7.
- Wu EB, Chan WWM, Yu CM. Retrograde chronic total occlusion intervention: Tips and tricks. *Catheter Cardiovasc Interv* 2008;72:806-14.
- Saito S, Tanaka S, Hiroe Y, et al. Angioplasty for chronic total occlusion by using tapered-tip guidewires. *Catheter Cardiovasc Interv* 2003;59:305-11.
- Colombo A, Mikhail GW, Michev I, et al. Treating chronic total occlusions using subintimal tracking and reentry: The STAR technique. *Catheter Cardiovasc Interv* 2005;64:407-11.
- Carlino M, Godino C, Latib A, et al. Subintimal Tracking and Re-entry Technique with Contrast Guidance: A Safer Approach. *Catheter and Cardiovasc Interv* 2008;72:790-6.
- Surmely JF, Katoh O, Tsuchikane E, et al. Coronary septal collaterals as an access for the retrograde approach in the percutaneous treatment of coronary chronic total occlusions. *Catheter Cardiovasc Interv* 2007;69:826-32.
- Surmely JF, Tsuchikane E, Katoh O, et al. New concept for CTO recanalization using controlled antegrade and retrograde subintimal tracking: the CART technique. *J Invasive Cardiol* 2006;18:334-8.
- Kimura M, Katoh O, Tsuchikane E, et al. The efficacy of a bilateral approach for treating lesions with chronic total occlusions: The CART (Controlled Antegrade and Retrograde subintimal Tracking) registry. *J Am Coll Cardiol Intv* 2009;2:1135-41.
- Muramatsu T, Tsukahara R, Ito Y. Rendezvous in coronary technique with the retrograde approach for chronic total occlusion. *J Invasive Cardiol* 2010;22:E179-82.
- Wu EB, Chan WWM, Yu CM. The confluent balloon technique – two cases illustrating a novel method to achieve rapid wire crossing of chronic total occlusion during retrograde approach percutaneous coronary intervention. *J Invasive Cardiol* 2009;21:539-42.
- Liu W, Wagatsuma K. A novel technique of chronic total occlusion retrograde wire crossing by wiring into the antegrade microcatheter. *Catheter Cardiovasc Interv* 2010;76:847-9.
- Wu CC, Fang HY, Wu CJ. Salvage for long-tract false lumen dissection via IVUS guidance in CTO lesions. *Acta Cardiol Sin* 2009;25:226-8.
- Lupattelli T, Basile A, Sardanelli F. Percutaneous extraluminal recanalization: usefulness of false channel balloon dilation and heparin administration before true lumen reentry. *Radiology* 2005;237:744-5.
- Katsuragawa M, Fujiwara H, Miyamae M, Sasayama S. Histologic studies in percutaneous transluminal coronary angioplasty for chronic total occlusion: comparison of tapering and abrupt types of occlusion and short and long occluded segments. *JACC* 1993;21:604-11.
- Galassi AR, Tomasello SD, Costanzo L, et al. Mini-STAR as bailout strategy for percutaneous coronary intervention of chronic total occlusion. *Cathet Cardiovasc Interv* 2012;79:30-40.
- Lombardi W. Retrograde PCI: What will they think of next? *J Invasive Cardiol* 2009;21:543.
- Iturbe JM, Abdel-Karim AR, Raja VN, et al. Use of the venture wire control catheter for the treatment of coronary artery chronic total occlusions. *Cathet Cardiovasc Interv* 2010;76:936-41.
- Badhey N, Lombardi WL, Thompson CA, et al. Use of the venture wire control catheter for subintimal coronary dissection and reentry in chronic total occlusions. *J Invasive Cardiol* 2010;22:445-8.
- Brilakis ES, Lombardi W, Banerjee S. Use of the stingray guidewire and the venture catheter for crossing flush coronary chronic total occlusions due to in-stent restenosis. *Cathet and Cardiovasc Interv* 2010;76:391-4.
- Saito S. Open sesame technique for chronic total occlusion. *Cathet Cardiovasc Interv* 2010;75:690-4.