

# The effect of post-operative ultrasound-guided transmuscular quadratus lumborum block on post-operative analgesia after hip arthroplasty in elderly patients: A randomised controlled double-blind study

**Address for correspondence:**  
Dr. Sameh Abdelkhalik Ahmed,  
Saied Street, Tanta,  
Al Gharbia Governate, Egypt.  
E-mail: samehabdelkhalik  
1982@gmail.com

**Submitted:** 21-Apr-2020

**Revised:** 15-May-2020

**Accepted:** 15-Jul-2020

**Published:** 01-Oct-2020

**Mohammad Ali Abdullallah, Sameh Abdelkhalik Ahmed, Mohamed Shebl Abdelghany**  
Department of Anaesthesia and Surgical Intensive Care, Faculty of Medicine, Tanta University, Tanta,  
Al Gharbia Governate, Egypt

## ABSTRACT

**Background and Aim:** The best analgesic technique after hip surgeries is a matter of debate. This clinical trial aimed to assess the effect of transmuscular ultrasound-guided quadratus lumborum (QL) block on post-operative analgesic consumption after hip arthroplasty in elderly patients. **Methods:** This prospective randomised double-blind study was carried out on 60 patients aged 60–80 years presented for total hip replacement under unilateral spinal anaesthesia. Patients were randomly allocated to one of two groups: A control group, receiving sham transmuscular QL block (QLB) (1 ml of normal saline), and a QL group, receiving real transmuscular QLB (30 ml of plain bupivacaine 0.25%). Post-operative morphine consumption (primary outcome), post-operative pain score (secondary outcome), time to the first request of rescue analgesia, patient's satisfaction and the occurrence of post-operative complications were measured. **Results:** Compared to the control group, the use of QLB in the second group significantly decreased intravenous morphine consumption postoperatively from  $8.50 \pm 3.06$  mg to  $5.60 \pm 3.22$  mg ( $P = 0.0007$ ) with a significant prolongation of the time to the first call for analgesia ( $P < 0.0001$ ). It also decreased the post-operative visual analogue score 4 h, 6 h and 8 h postoperatively ( $P < 0.05$ ). However, there was no difference between both the groups regarding patient's satisfaction and the occurrence of complications ( $P > 0.05$ ). **Conclusion:** The use of transmuscular QLB in patients undergoing total hip replacement decreased post-operative analgesic consumption and post-operative pain score and prolonged post-operative analgesia. It did not affect patients' satisfaction and occurrence of post-operative complications.

**Key words:** Elderly patients, hip arthroplasty, patients' satisfaction, post-operative analgesia, quadratus lumborum block

### Access this article online

Website: [www.ijaweb.org](http://www.ijaweb.org)

DOI: 10.4103/ija.IJA\_275\_20

Quick response code



## INTRODUCTION

The ideal peripheral nerve block technique for hip arthroplasty should achieve adequate sensory block without affecting motor function. The sensory afferents of the hip joint arise from several branches of the lumbar plexus. Femoral nerve block, lumbar plexus block, psoas compartment block and fascia iliaca compartment block can be used for post-operative analgesia for patients undergoing hip surgeries. However, the usefulness of peripheral nerve block techniques is not well established yet.<sup>[1]</sup>

Lumbar plexus block was found to be effective in reducing opioid requirements in hip arthroplasty

This is an open access journal, and articles are distributed under the terms of the Creative Commons Attribution-NonCommercial-ShareAlike 4.0 License, which allows others to remix, tweak, and build upon the work non-commercially, as long as appropriate credit is given and the new creations are licensed under the identical terms.

**For reprints contact:** [reprints@medknow.com](mailto:reprints@medknow.com)

**How to cite this article:** Abdullallah MA, Ahmed SA, Abdelghany MS. The effect of post-operative ultrasound-guided transmuscular quadratus lumborum block on post-operative analgesia after hip arthroplasty in elderly patients: A randomised controlled double-blind study. *Indian J Anaesth* 2020;64:887-93.

surgery.<sup>[2]</sup> However, some studies suggest that the analgesic effect of femoral nerve block or lumbar plexus block after hip arthroplasty is not clearly demonstrated. Their use was not associated with a decrease in post-operative analgesic consumption.<sup>[3]</sup> Furthermore, the use of lumbar plexus block may be limited by the potential risk of bilateral spread and systemic absorption of local anaesthetics. The use of a femoral catheter also increases the risk of bacterial colonisation and localised infection.<sup>[4]</sup>

Ultrasonographic-guided quadratus lumborum (QL) block has been described as an analgesic technique in abdominal surgeries (lateral or posterior QL block [QLB]). It is performed through the injection of a local anaesthetic mixture between the lateral abdominal layers and QL muscle.<sup>[5]</sup> After that, several modifications have been made to the nomenclature, owing to modifications in the technique that have made it useful in various surgeries. Studies had demonstrated that the injectate of QLB spreads to the lumbar plexus, and thus, it can induce hip analgesia that enables its use after hip arthroplasty surgery.<sup>[6]</sup>

We hypothesised that the use of ultrasound-guided transmuscular QLB in patients presenting for hip arthroplasty may decrease post-operative analgesic consumption and improve post-operative pain score. This randomised controlled clinical trial was conducted to evaluate the effect of post-operative ultrasound-guided transmuscular QLB on post-operative rescue analgesia consumption and pain scores in patients presenting for hip arthroplasty under unilateral spinal anaesthesia.

## METHODS

This prospective randomised double-blind study was carried out at our University Hospitals, Orthopaedic Operating Room, after being approved by the local research ethics committee and registered on the Pan African Clinical Trial Registry since July 2018 (Trial no of PACTR201807122404473). The study was conducted in the period from July 2018 to June 2019. Informed written consent was obtained from all participants.

Patients included in this clinical study were aged 60–80 years, classified as the American Society of Anaesthesiologists (ASA) class II or class III and presented for primary hip arthroplasty surgery. Patients were excluded upon refusal to participate or

having coagulopathy, allergy to medications used in the study, a recent hip fracture, spinal deformities, cognitive dysfunction or major cardiac, renal or hepatic disorders. Computer-generated randomisation numbers concealed in sealed opaque envelopes were used for allocation in groups. Each patient could randomly choose the envelope that determined his group. The two classified groups were as follows.

### Control group (c group) (30 patients)

Patients in this group received ipsilateral sham ultrasound-guided QLB via an injection of 1 ml of normal saline (in the fascial plane between QL and psoas major [PM] muscles) after surgery.

### Quadratus lumborum group (30 patients)

Patients in this group received an ipsilateral single-shot QLB (30 ml of plain bupivacaine 0.25%) after surgery using ultrasonographic guidance.

Upon patients' admission to the operating theatre, monitoring devices were attached to each, including a pulse oximeter, 5-lead electrocardiogram, non-invasive blood pressure monitor and temperature monitor. Then, intravenous access was established, with an infusion of lactated ringer solution 7 ml/kg over 30 min. All the equipment required for spinal, general anaesthesia, resuscitation and nerve block was prepared by an expert anaesthesiologist not participating in this study.

The patient was turned to the lateral decubitus position (the healthy side directed upwards). Under complete aseptic conditions and local anaesthetic skin infiltration with 3 ml lidocaine 1% at L3–L4 or L4–L5 intervertebral space, paramedian spinal anaesthesia was performed using a 25-gauge spinal needle. Once intrathecal placement had been confirmed, a mixture of 2 ml of hyperbaric bupivacaine (10 mg) and 0.5 ml of fentanyl (25 µg) was injected. The patient was left in this position for 20 min, during which monitoring of the haemodynamic parameters (heart rate and mean arterial pressure) was carried out every 3 min. Moreover, sensory and motor blockade was assessed. Oxygen was provided to the patient through an oxygen mask at a flow rate of 4 L/min.

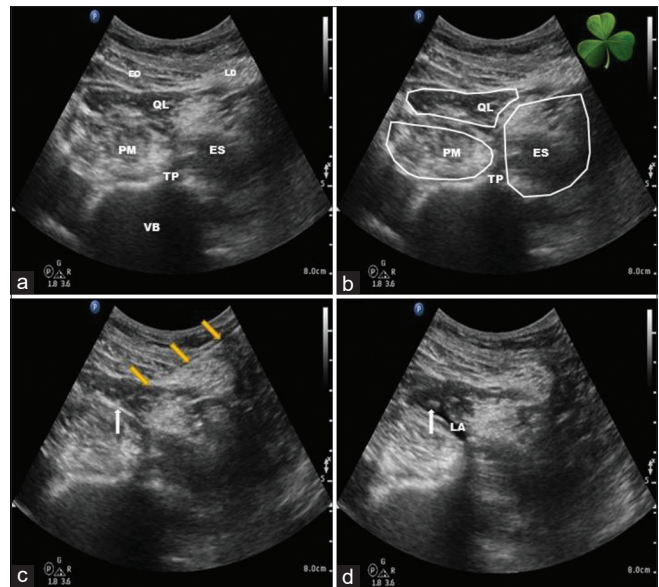
The pinprick test from caudal to cephalic direction using a 25-gauge needle was used to evaluate the sensory block until the sensory level reached T10 or higher. Motor block was assessed every 5 min by the Bromage score<sup>[7]</sup> (Grade 0: No paralysis, Grade 1:

Unable to raise an extended leg but able to move the knees and ankles, Grade 2: Unable to flex knees but able to flex ankle and Grade 3: No movement) until reaching a score of 2 or 3. If the blockade was not adequate within 20 min, the patient would receive general anaesthesia and be excluded from the study. The patient was turned to the contralateral decubitus position (diseased side upwards) after ensuring adequate level of sensory and motor block. A decrease in the heart rate below 50 beat/min was managed by administering atropine 0.3 mg intravenous (I V), while a decrease in the mean arterial pressure below 65 mmHg was managed by administering 10 mg ephedrine IV and intravenous fluids.

At the end of the surgery, in a lateral decubitus position and under antiseptic precautions, a low-frequency (2–5 MHz) convex ultrasound probe was placed transverse to the abdominal flank in the anterior axillary line above the iliac crest to clearly visualise the three abdominal muscle layers. Then, the probe was moved posteriorly with the external oblique and the internal oblique muscles disappearing into aponeurosis and the latissimus dorsi appearing with the QL muscle beneath. By moving the probe farther posteriorly, the transverse process of the lumbar vertebra, QL, PM and erector spinae muscles was identified as a ‘Shamrock sign.’ Using the in-plane technique, the needle was inserted from the posterior end of the ultrasound probe through the back muscles and then advanced through the QL muscle (transmuscular approach), targeting the fascial plane between the QL and PM muscles where the local anaesthetic (30 ml of plain bupivacaine 0.25%) was deposited in the QL group and 1 ml of normal saline was deposited in the control group [Figure 1].

An anaesthesia resident who was not involved in the study helped in data collection and assessment. The visual analogue score (score for the severity of pain in the range 0–10, where 0 = no pain and 10 = severe pain) was used to assess post-operative pain during rest, every 2 h till 12 h and then every 4 h till 24 h (secondary outcome). Rescue analgesia in the form of 3 mg of intravenous morphine was administered whenever the visual analogue scale (VAS) score was 4 or more. All patients received paracetamol 1000 mg intravenous infusion every 6 h. Morphine total dose consumption in the first 24 h of the post-operative period was recorded (primary outcome).

Furthermore, the time to the first request for rescue analgesia was recorded, which represents the time from



**Figure 1:** Ultrasound-guided quadratus lumborum block (transmuscular approach). (a) Cross-sectional sonoanatomy of the lateral abdominal wall showing from anterior to posterior EO – External oblique; QL – Quadratus lumborum; PM – Psoas major; TP – transverse process; VB – vertebral body; LD – latissimus dorsi; ES – Erector spinae. (b) Shamrock sign with the quadratus lumborum, psoas major and erector spinae muscles as leaves of the Shamrock and the transverse process as the stem. (c) Trajectory of the needle (yellow arrows) from the posterior to the anterior through the latissimus dorsi and the quadratus lumborum muscles, notice the needle tip (white arrow) in the fascial plane between the quadratus lumborum and the psoas major muscles. (d) Deposition of the local anaesthetic – LA; in the fascial plane between the quadratus lumborum and the psoas major muscles.

the operating room discharge until the administration of the first dose of rescue analgesia. Moreover, the incidence of post-operative complications such as nausea and vomiting, bradycardia, hypotension, pruritus, local infection or local haematoma was recorded. In the morning after surgery, the patients were asked to grade their degree of satisfaction regarding post-operative analgesia using a 4-point scale where 4 = very satisfied, 3 = satisfied, 2 = dissatisfied and 1 = very dissatisfied.

A preliminary similar study was conducted on 10 patients (not included in the final study). Morphine rescue analgesia consumption in the first 24 h after surgery was significantly decreased from  $10.80 \pm 1.64$  mg in the control group to  $6.00 \pm 3.09$  mg in the QL group. Based on these results, 24 patients in each group were required to detect a statistically significant difference in post-operative morphine consumption of 3 mg at  $\alpha$  error of 0.05 and power of study of 90%. Assuming that the dropout rate is 20%, 30 patients were required in each group. Through the aid of Statistical Package for the Social Sciences version 16 (SPSS Inc., Chicago, IL, USA), the statistical analysis was carried

out with the use of the Kolmogorov–Smirnov test for checking the assumption of normality. Parametric data were expressed as mean ± standard deviation after analysis using the unpaired *t*-test, while categorical data were expressed as a number and percent after they had been analysed by Fisher’s exact test. The Mann–Whitney U-test was used for statistical analysis of the post-operative VAS score and patient’s satisfaction. A linear mixed-effect model was used to analyse the repeated measurements of post-operative pain score to detect the relationship between the visual analogue score over time and the technique of intervention. The model includes the patient indicator as a random effect and time, treatment and the interaction between them as fixed effects. The statistically significant difference was considered as  $P < 0.05$ .

## RESULTS

Sixty-nine patients undergoing hip arthroplasty were assessed for eligibility for this randomised clinical study. The inclusion criteria were not applicable on six patients (two had coagulopathy, three had liver insufficiency and one had cognitive dysfunction) and another three patients refused to participate. The remaining 60 patients were randomly distributed into two equal groups, with follow-up and analysis of the data of all studied patients [Figure 2].

Basic demographic data (age, gender, body weight and ASA class) and surgical criteria (side and duration of surgery) were comparable between the two groups ( $P > 0.05$ ) [Table 1].

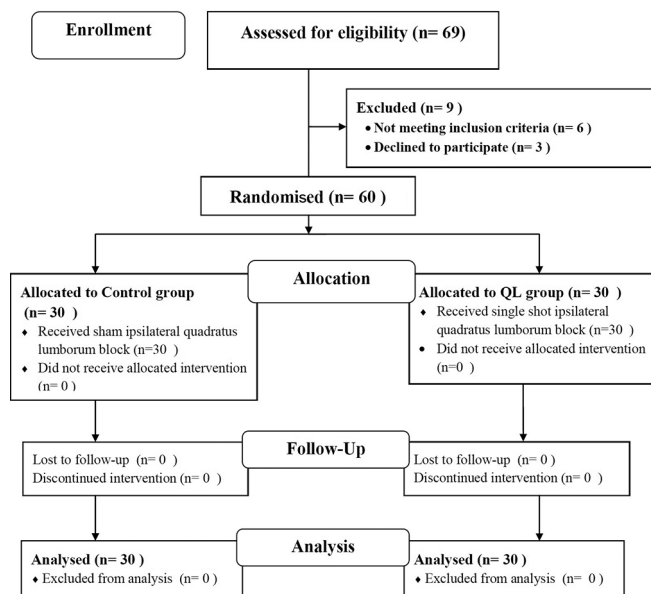


Figure 2: CONSORT flowchart of the study

The total intravenous morphine consumption in the first 24 h after surgery was significantly lower in the QLB group than the control group ( $P = 0.007$ ; 95% confidence interval [CI]: 1.27; 4.52). The time to the first request for rescue analgesia was significantly longer in the QLB group than the control group ( $P < 0.0001$ ). In addition, the post-operative visual analogue score was significantly lower in the QLB group than the control group, 4, 6 and 8 h postoperatively ( $P < 0.05$ ), with an insignificant statistical difference between the two groups all over other time intervals ( $P > 0.05$ ). Moreover, the linear mixed-effect analysis of the VAS score revealed a significant interaction of treatment and time ( $P < 0.0001$ ) [Table 2].

The incidence of post-operative complications including nausea and vomiting, bradycardia, hypotension, pruritus and haematoma was statistically insignificant among the two groups. No cases of localised infection were reported in any of them throughout the hospitalisation period [Table 2].

Patients who received real QLB were not statistically more satisfied than the patients in the control group ( $P = 0.09$ ) (95% CI:  $-1.00$ ;  $-0.0001$ ). However, more patients in the QL group were satisfied and very satisfied than patients in the control group [Figure 3].

## DISCUSSION

This trial revealed that unilateral post-operative single-shot ultrasound-guided transmuscular QLB in elderly patients undergoing primary total hip arthroplasty significantly decreased consumption of morphine rescue analgesia on the 1<sup>st</sup> day following surgery, prolonged the time to the first call for rescue analgesia and decreased the post-operative pain scores, neither significantly improved patients’ satisfaction nor caused an increase in the post-operative adverse events, compared to sham QLB.

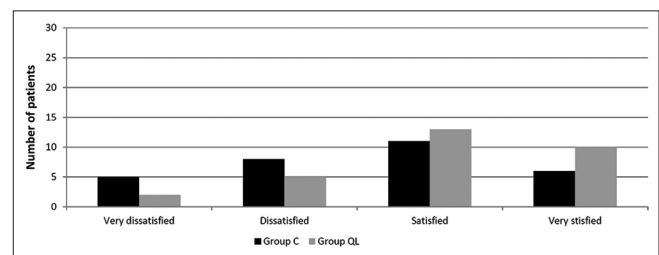


Figure 3: Patients’ satisfaction in the two groups. Control group ( $n = 30$  patients) quadratus lumborum group ( $n = 30$  patients). QL = Transmuscular quadratus lumborum block. Control group = sham group where we inject saline through transmuscular quadratus lumborum needle. Data were expressed as patients’ number



**Table 1: Demographic and surgical data of the studied patients**

	Control group (n=30)	QLB group (n=30)	P	CI (95%)
Age (years)	66.43±3.89	67.90±4.8	0.20	-0.79-3.73
Gender, n (%)				
Male	11 (36.67)	9 (30)	0.79	-0.19-0.34
Female	19 (63.33)	21 (70)		
Body weight (kg)	79.67±4.90	77.53±4.42	0.08	-4.54-0.27
ASA class, n (%)				
II	20 (66.67)	23 (76.67)	0.57	-0.15-0.40
III	10 (33.33)	7 (23.33)		
Side of surgery, n (%)				
Right side	17 (56.67)	14 (46.67)	0.61	-0.15-0.35
Left side	13 (43.33)	16 (53.33)		
Duration of surgery (min)	125.03±4.55	122.00±9.15	0.11	-6.76-0.70

QLB: Transmuscular quadratus lumborum block, Control group: sham group where we inject saline through transmuscular quadratus lumborum needle. Data are presented as mean±SD or patients number (%). SD: Standard deviation, CI: Confidence interval, ASA: American Society of Anesthesiologists

**Table 2: Criteria of post-operative analgesia**

	Control group (n=30)	QLB group (n=30)	P	CI (95%)
24 h total dose of morphine consumption (mg), mean±SD	8.50±3.06	5.60±3.22	0.0007*	1.27-4.52
Time for the first request of rescue analgesia (min), mean±SD	357.00±40.44	427.00±37.52	<0.0001*	49.83-90.16
VAS score (median and interquartile range)				
Immediately post-operative	2 (0-4)	2 (0-3)	0.20	
2 h	2 (1-4)	2 (1-3)	0.28	
4 h	3 (1-6)	2 (1-4)	0.01*	
6 h	5 (2-7)	3 (2-7)	0.001*	
8 h	5 (3-7)	4 (2-7)	0.0007*	
10 h	3 (2-7)	3 (2-5)	0.34	
12 h	3 (2-4)	3 (2-3)	0.63	
16 h	2 (1-4)	2 (1-3)	0.18	
20 h	2 (1-3)	2 (1-3)	0.69	
24 h	1 (0-3)	1 (0-3)	0.73	
Post-operative complications, n (%)				
N and V	8 (26.67)	2 (6.67)	0.08	
Bradycardia	4 (13.33)	7 (23.33)	0.51	
Hypotension	2 (6.67)	4 (13.33)	0.64	
Pruritus	3 (10)	4 (13.33)	1.00	
Infection	0 (0)	0 (0)	-	
Haematoma	0 (0)	3 (10)	0.24	

QL: Transmuscular quadratus lumborum block, Control group: Sham group where we inject saline through transmuscular quadratus lumborum needle. Data were presented as mean±SD or median and IQR or number and percent. \*Significant changes between the two groups. N and V: Nausea and vomiting, SD: Standard deviation, CI: Confidence interval, VAS: Visual analogue scale, IQR: Interquartile range

The nerve supply of the hip joint mainly originates from the lower part of the lumbar plexus (L2–L4) and the upper part of the sacral plexus (L4–S1) through the femoral nerve (L2–L4), obturator nerve (L2–L4) and sciatic nerve (L4-S3). The lateral gluteal region and the proximal lateral thigh receive additional nerve supply from the lateral femoral cutaneous nerve (L2–L3), the subcostal nerve (T12) and the lateral cutaneous branch of iliohypogastric nerve (T12 and L1).<sup>[8]</sup>

Ultrasound-guided QLB was first described in 2007 by Blanco.<sup>[9]</sup> The technique then gained increased popularity for its use in paediatrics,<sup>[10,11]</sup> adults<sup>[12]</sup> and to control the post-operative pain after caesarean

section.<sup>[13]</sup> It can be performed through many approaches including lateral (QL1), posterior (QL2), anterior (transmuscular [TQL]) and intramuscular approaches.<sup>[14]</sup> The transmuscular QLB might be used for analgesia for the trunk and the lower limb (T10–L4), as the local anaesthetic mixture is injected between the psoas muscle and the QL muscle, which is the site where the branches of the lumbar plexus run.<sup>[15,16]</sup> This may be supported by the cadaveric studies of Carline *et al.*<sup>[5]</sup> and Dam *et al.*<sup>[17]</sup> and the radiological and anatomical study conducted by Adhikary *et al.*<sup>[18]</sup> The local anaesthetic mixture in transmuscular QLB spreads to the lumbar paravertebral space and may be the lower thoracic paravertebral space. This leads

to the block of most of the nerve roots innervating the hip joint (L1–L4), sparing the sacral roots. It can thus be used as an effective post-operative analgesic technique but not as an anaesthetic technique in hip surgeries.<sup>[19]</sup>

Many case reports describe the use of different approaches of QLB as an analgesic technique for laparotomy,<sup>[12]</sup> chronic pain,<sup>[20]</sup> paediatrics,<sup>[10,11]</sup> after caesarean section<sup>[21,22]</sup> and in patients undergoing surgeries in lower extremities.<sup>[6,23–25]</sup> Parras and Blanco compared the post-operative analgesic effect of TAP block, QLB and femoral block in patients presenting for fixation of fractured neck femur and concluded that QLB had a more analgesic effect in comparison with the femoral block and TAP block.<sup>[26]</sup> Furthermore, the clinical study of Tulgar *et al.* found that transmuscular QLB and lumbar erector spinae plane block improved the quality of post-operative analgesia following hip and proximal femoral surgeries in comparison with standard intravenous analgesia.<sup>[27]</sup>

Recently, a clinical study by Kukreja *et al.* showed improved post-operative analgesia and decreased opioid analgesia consumption in patients undergoing primary total hip arthroplasty with the use of an anterior QLB.<sup>[28]</sup> They also revealed that the post-operative opioid requirement and the post-operative pain score were significantly decreased in patients undergoing primary total hip replacement under general or spinal anaesthesia if they received preoperative posterior QLB.<sup>[29]</sup> Furthermore, Green *et al.* evaluated the use of transmuscular QLB in patients undergoing hip surgeries. They concluded that its use decreases the length of hospital stay and intraoperative fentanyl consumption. However, the post-operative pain score lacked statistical significance, which may be due to the use of general anaesthesia in all patients and the small sample size.<sup>[30]</sup>

A limitation to this clinical trial is the few available randomised controlled studies evaluating the analgesic effect of QLB in patients undergoing hip surgeries. Furthermore, motor block was not assessed in the post-operative period, and the inability to perform a continuous QLB limited the study. Moreover, patient-controlled analgesia was not used routinely in the two groups owing to limited resources. On the other hand, the use of single concentration and volume of the local anaesthetic mixture without local anaesthetic adjuvant added to the study limitations.

## CONCLUSION

In conclusion, in elderly patients undergoing hip arthroplasty surgery under unilateral spinal anaesthesia, the use of one-sided single-shot ultrasound-guided transmuscular QLB decreased post-operative morphine consumption.

## Acknowledgements

We would like to acknowledge all the members of the Department of Anaesthesia and Intensive Care, Faculty of Medicine, Tanta University.

## Financial support and sponsorship

Nil.

## Conflicts of interest

There are no conflicts of interest.

## REFERENCES

- Rao AR, Lakshmanan A, Ajith A, Rao SM. Centenarians: Hip fractures and peripheral lower limb nerve blocks. *Indian J Anaesth* 2010;54:268.
- Capdevila X, Macaire P, Dadure C, Choquet O, Biboulet P, Ryckwaert Y, *et al.* Continuous psoas compartment block for postoperative analgesia after total hip arthroplasty: New landmarks, technical guidelines, and clinical evaluation. *Anesth Analg* 2002;94:1606-13, table of contents.
- Biboulet P, Morau D, Aubas P, Bringuier-Branchereau S, Capdevila X. Postoperative analgesia after total-hip arthroplasty: Comparison of intravenous patient-controlled analgesia with morphine and single injection of femoral nerve or psoas compartment block. A prospective, randomized, double-blind study. *Reg Anesth Pain Med* 2004;29:102-9.
- Cuvillon P, Ripart J, Lalourcey L, Veyrat E, L'Hermite J, Boisson C, *et al.* The continuous femoral nerve block catheter for postoperative analgesia: Bacterial colonization, infectious rate and adverse effects. *Anesth Analg* 2001;93:1045-9.
- Carline L, McLeod GA, Lamb C. A cadaver study comparing spread of dye and nerve involvement after three different quadratus lumborum blocks. *Br J Anaesth* 2016;117:387-94.
- La Colla L, Uskova A, Ben-David B. Single-shot quadratus lumborum block for postoperative analgesia after minimally invasive hip arthroplasty: A new alternative to continuous lumbar plexus block? *Reg Anesth Pain Med* 2017;42:125-6.
- Jagtap S, Chhabra A, Dawoodi S, Jain A. Comparison of intrathecal ropivacaine-fentanyl and bupivacaine-fentanyl for major lower limb orthopaedic surgery: A randomised double-blind study. *Indian J of Anaesth* 2014;58:442.
- Talawar P, Tandon S, Tripathy D, Kaushal AJ. Combined pericapsular nerve group and lateral femoral cutaneous nerve blocks for surgical anaesthesia in hip arthroscopy. *Indian J Anaesth* 2020;64:638.
- Blanco R. TAP block under ultrasound guidance: The description of a 'non pops technique'. *Reg Anaesth Pain Med* 2007;32:130.
- Chakraborty A, Goswami J, Patro VJ, Practice A. Ultrasound-guided continuous quadratus lumborum block for postoperative analgesia in a pediatric patient. *A A Practice* 2015;4:34-6.
- Visoiu M, Yakovleva N. Continuous postoperative analgesia via quadratus lumborum block-an alternative to transversus abdominis plane block. *Paediatr Anaesth* 2013;23:959-61.

12. Kadam VR. Ultrasound-guided quadratus lumborum block as a postoperative analgesic technique for laparotomy. *J Anaesthesiol Clin Pharmacol* 2013;29:550-2.
13. Blanco R, Ansari T, Riad W, Shetty N. Quadratus lumborum block versus transversus abdominis plane block for postoperative pain after cesarean delivery: A randomized controlled trial. *Reg Anesth Pain Med* 2016;41:757-62.
14. Ueshima H, Otake H, Lin JA. Ultrasound-Guided Quadratus Lumborum Block: An Updated Review of Anatomy and Techniques. *Biomed Res Int* 2017;2017:2752876.
15. Ueshima H, Yoshiyama S, Otake H. The ultrasound-guided continuous transmuscular quadratus lumborum block is an effective analgesia for total hip arthroplasty. *J Clin Anesth* 2016;31:35.
16. Kadam VR, Howell S. Ultrasound-guided continuous transmuscular quadratus lumborum block- L4 or L2 level catheter insertion for analgesia in open abdominal surgery: Case series. *Indian J Anaesth* 2018;62:555-7.
17. Dam M, Moriggl B, Hansen CK, Hoermann R, Bendtsen TF, Borglum J. The pathway of injectate spread with the transmuscular quadratus lumborum block: A cadaver study. *Anesth Analg* 2017;125:303-12.
18. Adhikary SD, El-Boghdadly K, Nasralah Z, Sarwani N, Nixon AM, Chin KJ. A radiologic and anatomic assessment of injectate spread following transmuscular quadratus lumborum block in cadavers. *Anaesthesia* 2017;72:73-9.
19. Elsharkawy H, El-Boghdadly K, Kolli S, Esa WA, DeGrande S, Soliman LM, *et al.* Injectate spread following anterior sub-costal and posterior approaches to the quadratus lumborum block. *Eur J Anaesthesiol* 2017;34:587-95.
20. Carvalho R, Segura E, Loureiro MD, Assuncao JP. Quadratus lumborum block in chronic pain after abdominal hernia repair: Case report. *Rev Brasileira de Anaesthesiol* 2017;67:107-9.
21. Blanco R, Ansari T, Girgis E. Quadratus lumborum block for postoperative pain after caesarean section: A randomised controlled trial. *Eur J Anaesthesiol* 2015;32:812-8.
22. Krohg A, Ullensvang K, Rosseland LA, Langesæter E, Sauter AR. The analgesic effect of ultrasound-guided quadratus lumborum block after cesarean delivery: A randomized clinical trial. *Anesth Analg* 2018;126:559-65.
23. Hockett MM, Hembrador S, Lee A. Continuous quadratus lumborum block for postoperative pain in total hip arthroplasty: A case report. *A & A case reports* 2016; 7:129-31.
24. La Colla L, Ben-David B, Merman R. Quadratus lumborum block as an alternative to lumbar plexus block for hip surgery: A report of 2 cases. *A & A case reports* 2017; 8:4-6.
25. Tulgar S, Ermis MN, Ozer Z. Combination of lumbar erector spinae plane block and transmuscular quadratus lumborum block for surgical anaesthesia in hemiarthroplasty for femoral neck fracture. *Indian J of Anaesth* 2018;62:802.
26. Parras T, Blanco R. Randomised trial comparing the transversus abdominis plane block posterior approach or quadratus lumborum block type I with femoral block for postoperative analgesia in femoral neck fracture, both ultrasound-guided. *Rev Esp Anesthesiol Reanim* 2016;63:141-8.
27. Tulgar S, Kose HC, Selvi O, Senturk O, Thomas DT, Ermis MN, *et al.* Comparison of ultrasound-guided lumbar erector spinae plane block and transmuscular quadratus lumborum block for postoperative analgesia in hip and proximal femur surgery: A prospective randomized feasibility study. *Anesth Essays Res* 2018;12:825-31.
28. Kukreja P, MacBeth L, Sturdivant A, Morgan CJ, Ghanem E, Kalagara H, *et al.* Anterior quadratus lumborum block analgesia for total hip arthroplasty: A randomized, controlled study. *Reg Anesth Pain Med* 2019;44:1-5.
29. Kukreja P, MacBeth L, Potter W, Buddemeyer K, DeBell H, Elsharkawy H, *et al.* Posterior quadratus lumborum block for primary total hip arthroplasty analgesia: A comparative study. *Einstein (São Paulo)* 2019;17:eA04905.
30. Green MS, Hoffman CR, Iqbal U, Ives OO, Hurd B. Transmuscular quadratus lumborum block reduces length of stay in patients receiving total hip arthroplasty. *Anesth Pain Med* 2018;8:E80233.

### Central Supplement of IJA

Now! Opportunity for our members to submit their articles to the Central Supplement of IJA (CSIJA)! The CSIJA, launched by ISA covering the central zone of ISA, solicits articles in Anaesthesiology, Critical care, Pain and Palliative Medicine. Visit <http://www.cjsa.org> for details.

Dr. Syed Moied Ahmed, Aligarh  
Editor In Chief