



# Evaluation of wound healing activity of cow urine ark in diabetic Wistar albino rats

Hiren N. Hirapara<sup>1</sup>, Vishal M. Ghori<sup>2</sup>, Ashish P. Anovadiya<sup>3</sup>, Chandrabhanu R. Tripathi<sup>3</sup>

## ABSTRACT

**Aim:** To evaluate wound healing activity of cow urine ark in diabetic rats. **Materials and Methods:** Streptozotocin-induced diabetic Wistar albino rats were randomly divided into six groups ( $n = 6$ ). Three groups - diabetic control, active control (glibenclamide), and treatment (cow urine ark) were operated for excision wounds (EWs). Rats in these groups received distilled water 1 ml/day, glibenclamide 0.5 mg/kg body weight/day, and cow urine ark 5.5 ml/kg body weight/day orally till complete healing of the EWs. EWs were evaluated for wound contraction on 3<sup>rd</sup>, 7<sup>th</sup>, and 11<sup>th</sup> day and for reepithelization on 11<sup>th</sup> day. The other three groups were operated for incision wounds (IW) as well as dead space wounds (DW) in the same animal which received the above agents orally for 11 days. IWs were analyzed for wound breaking strength and DWs were analyzed for dry weight, hydroxyproline content, and histology of granulation tissue. **Results:** EWs showed significantly increased wound closure in the treatment group as compared to the diabetic as well as active control groups at 3<sup>rd</sup> ( $P < 0.001$ ) and 11<sup>th</sup> ( $P < 0.05$ ) post-wounding day and to the only diabetic control group at 7<sup>th</sup> ( $P < 0.01$ ) post-wounding day. IWs showed significant improvement in wound breaking strength in the treatment as compared to diabetic ( $P < 0.001$ ) and active control ( $P < 0.01$ ) groups. DWs showed significant increase in hydroxyproline content of granulation tissue in the treatment as compared to diabetic control ( $P < 0.001$ ) and active control ( $P < 0.001$ ) groups. Wound breaking strength and hydroxyproline content also significantly increased in the active control group compared to diabetic control ( $P < 0.001$  and  $P < 0.05$ , respectively). Granulation tissue dry weight was significantly increased in treatment and active control groups as compared to diabetic control ( $P < 0.001$ ). **Conclusion:** Cow urine ark increases granulation tissue formation as well as collagen content. Wound contraction was also significantly improved. The cow urine ark could be potentially effective in promoting healing of diabetic wounds by increasing granulation tissue formation and collagen content, however, further studies are required for its clinical application.

**KEY WORDS:** Collagen, cow urine ark, granulation tissue, streptozotocin-induced diabetes

<sup>1</sup>Department of Pharmacology, GMERS Medical College, Junagadh, Gujarat, India, <sup>2</sup>Department of Pharmacology, Billev Pharma East, Ljubljana, Slovenia, <sup>3</sup>Department of Pharmacology, Government Medical College, Bhavnagar, Gujarat, India

### Address for correspondence:

Hiren N. Hirapara, GMERS Medical College, Junagadh, Gujarat, India. E-mail: dr.hirenhirapara@gmail.com

**Received:** July 25, 2016

**Accepted:** September 02, 2016

**Published:** September 25, 2016

## INTRODUCTION

Diabetes mellitus (DM) is part of a larger global epidemic of non-communicable diseases. India accounts for nearly 15% of the global diabetes burden with 40.9 million people affected [1]. The wound healing is a complex but highly dynamic process of cellular, physiological and biochemical events, which leads to the functional restoration of injured tissue. DM is one of the common causes of impaired wound healing, which imposes high morbidity and health care cost [2,3]. Chronic non-healing ulcers are the common complications associated with diabetes [4]. Diabetic patients often ignore lower extremity ulcers, which lead to wound infection and ultimately amputation. Causal mechanisms associated with impaired wound healing in diabetes are micro- and macro-vascular abnormalities, impaired epithelization, and reduced angiogenesis [5]. Besides, oxidative stress associated with hyperglycemia in wound environment has

also been suggested to delay wound healing process in diabetic patients [6].

Because of lack of well-established medical treatment, diabetic wounds are conservatively treated by surgical debridement of necrotic tissue as well as by controlling blood sugar level. A variety of treatments had been evaluated for the management of diabetic wounds including herbal medicines. In ancient Indian Ayurvedic literature such as Charak Samhita and Sushruta Samhita, cow urine is mentioned as the most effective substance of animal origin with innumerable therapeutic value [7]. It is one of the important contents of "Panchgavya" containing five important substances obtained from cow, namely urine, dung, milk, ghee, and curd [8].

Medicinal properties of cow urine such as bioenhancer, antibiotic, antifungal, and anticancer have been patented

under US patent number 6,896,907 and 6,410,059 [9,10]. Several studies had suggested that cow urine has anti-diabetic potential probably due to its antioxidant properties [11,12]. Besides, external application of cow urine on excision wound (EW) has shown to hasten the wound healing [13]. Another study of histomorphological analysis of surgically created wounds in healthy goats showed significant infiltration of polymorphonuclear cells, neovascularization, and fibroblast proliferation in cow urine treated wounds [14]. Based on these observations, we designed this study to evaluate wound healing effect of cow urine ark in diabetic rats.

## MATERIALS AND METHODS

Institutional Animal Ethics Committee, Government Medical College, Bhavnagar, Gujarat (India) (Approval No. - 26/2012; Pharmacology No. - 24/2012) approval was taken before starting this study. Wistar albino rats of either sex with an approximate weight of 200-350 g were placed in individual polypropylene cages and acclimatized to the laboratory environment for 1 week. The rats were maintained on normal laboratory food and water *ad libitum*, under controlled room temperature (25°C ± 2°C, 60-70% humidity) and 12-12 h light-dark cycle.

### Streptozotocin (STZ) - Induced Diabetes

The rats were given a single intraperitoneal dose of STZ 50 mg/kg body weight (Alfa Aesar, A Johnson Matthey Company, MA/USA, CAS: 18883-66-4) to produce DM [15]. Random blood sugar (RBS) was measured from a blood drop drawn from the tail vein using glucometer (Accu - Chek Go, Roche Diagnostic, Germany) after 4 days of STZ injection. The rats with RBS >300 mg/dl were enrolled in the study. Insulin neutral protamine Hagedorn (5 IU/kg body weight; Wosulin, Wockhardt Limited, India) was given subcutaneously, once a day to maintain the RBS between 250 and 350 mg/dl.

### Experimental Design and Wound Models

The diabetic Wistar albino rats were divided into six groups (n = 6 in each group). Three groups - Group I (diabetic control), Group II (glibenclamide - active control), and Group III (Cow urine ark - treatment group) served as the EW groups. They received distilled water 1 ml/day, glibenclamide (SIGMA Life Science, New Delhi, India) 0.5 mg/kg body weight/day, and cow urine ark 5.5 ml/kg body weight/day orally till complete healing of the EWs. The cow urine ark was procured from Go-Vigyan Anushandhan Kendra, Nagpur, India. The remaining three groups - Group IV (Diabetic control), Group V (Glibenclamide - active control), and Group VI (Cow urine ark - treatment) served as incision and dead space wound (DW) groups and received the same doses of respective agents, as described above, for 11 days. All the wounds were inflicted under ketamine (75 mg/kg body weight) and xylazine (10 mg/kg body weight) anesthesia with proper aseptic precautions.

## EW

EWs were inflicted by excising a circular patch of full thickness skin (measuring approximately 500 mm<sup>2</sup>) from the nape of the neck [16]. Wound margins were traced on transparent plastic sheets on day 0, 3, 7 and 11 to evaluate the wound contraction. Reepithelization was measured on 11<sup>th</sup> post wounding day when epithelization was visible. The wound area was measured using a UTHSCA image analyzer (version 3.00, The University of Texas Health Science Center, San Antonio, USA) from the scanned transparent plastic sheets. Wound closure rate was calculated by the formula [15]:

$$\text{Wound closure rate (\%)} = \frac{\text{Area day 0} - \text{Area day n}}{\text{Area day 0}} \times 100$$

Where area day 0 = Initial wound area at day 0,  
Area day n = Area on n<sup>th</sup> post wounding day.

The wound re-epithelialization was calculated using the formula [15]:

$$\text{Reepithelialization (\%)} \text{ on } 11^{\text{th}} \text{ day} = \text{Total wound area (\%)} - \text{Wound area not covered with epidermis (\%)}$$

### Re-sutured Incision and DW

About 5 cm long full thickness paravertebral incisions were made on either side of the vertebral column and sutured with black silk 4.0 sutures [17]. Sterile grass piths (measuring 2.5 cm × 0.3 cm) were inserted and sutured in the loose areolar tissue of the groins in the same rats to produce DWs. While in axillary region, sterile cotton pellet (weighing 10 mg) was inserted and sutured. The sutures of incision wound (IW) were removed on the 7<sup>th</sup> day of wounding and of DWs on the 11<sup>th</sup> day. The IW breaking strength was measured on 11<sup>th</sup> post wounding day by constant water flow technique described by Lee under anesthesia [18]. The rats were then sacrificed with a high dose of ketamine and xylazine. The granulation tissue formed on grass piths were utilized for the hydroxyproline estimation and histological examination [19]. The hydroxyproline content was measured as µg/100 mg of granulation tissue. The cotton pellets with granulation tissue around it were excised from the axillary region and dried overnight at 60°C in hot air oven. The weight of overnight dried pellets was expressed as mg/100 g body weight [20].

Hematoxylin and Eosine (H and E) stained sections of granulation tissues were semi-quantitatively analyzed by a pathologist. Grades were given (grade 1-4) for the presence of polymorphonuclear cells, macrophages, fibroblasts, and neo-angiogenesis [21].

### Statistical Analysis

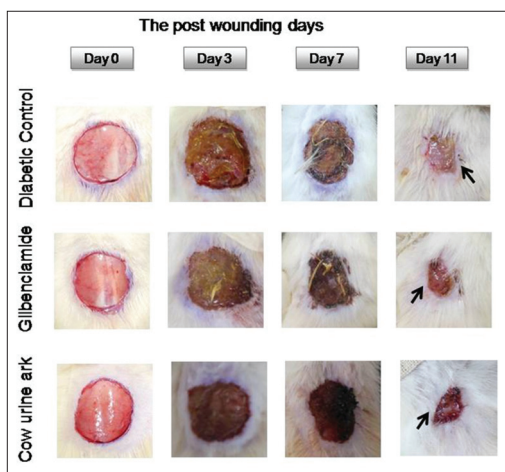
Analyses were performed using GraphPad InStat demo version number 3.0. The data were expressed as mean ± standard error of mean. One-way analysis of variance followed by Tukey-Kramer test for parametric variables and Kruskal-

Wallis followed by Dunn’s multiple comparison test for non-parametric variables were used to compare mean differences between different groups.  $P < 0.05$  was considered as statistically significant.

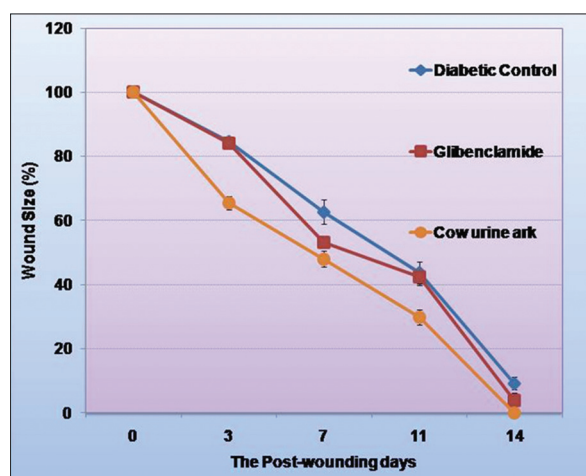
## RESULTS

### EW

The wound contraction was significantly higher in cow urine ark group than diabetic control group throughout healing period. Statistically significant wound healing was also observed in cow urine ark group as compared to glibenclamide group on day 3 and 11 (Table 1). The wound closure photographs of all the groups are shown in Figure 1. Re-epithelialization on the 11<sup>th</sup> post wounding day was not significantly affected in cow urine ark group (Table 1). The wound closure was a faster throughout healing period (owing to wound contraction) as shown in Figure 2. The wound closure was almost 100% on day 14 in cow urine ark group (Figure 2).



**Figure 1:** The excision wound healing time course noted on 0, 3, 7 and 11 post-wounding day



**Figure 2:** Wound healing curve. The graph shows the percentage of excision wound closure over the time period

### Resutured Incision and DW

Mean IW breaking strength on the 11<sup>th</sup> post wounding day in cow urine ark group was significantly higher as compared to diabetic control as well as glibenclamide group. The hydroxyproline content in granulation tissue from cow urine ark group was significantly higher than both the diabetic control and glibenclamide group (Table 2). Overnight dried cotton pellet weight (granulation tissue dry weight) was also significantly increased as compared to diabetic control group; however, it could not reach statistically significant level as compared to glibenclamide group.

A semi-quantitative histological analysis of granulation tissue obtained at 11<sup>th</sup> post-wounding day did not show any difference among the groups in any of the parameters examined (Table 3).

## DISCUSSION

The wound healing activity of cow urine ark in diabetic Wistar albino rats was evaluated in this study using several models

**Table 1:** Effect of cow urine ark on excision wound model

Groups (n=6)	Wound closure (%)			Re-epithelialization (%) 11 <sup>th</sup> Day
	3 <sup>rd</sup> Day	7 <sup>th</sup> Day	11 <sup>th</sup> Day	
Diabetic control	15.3±1.4	37.3±3.8	56.3±3.4	56.01±2.5
Glibenclamide	15.7±1.2	46.7±1.8	57.6±2.5	63.2±1.8
Cow urine ark	34.5±2.1*	52.0±2.5 <sup>#</sup>	70.2±2.4 <sup>§</sup>	55.9±1.6

n=6 in each group, values are represented as mean±SEM, \* $P < 0.001$  as compared to diabetic control and glibenclamide; <sup>#</sup> $P < 0.01$  as compared to diabetic control (Tukey Kramer multiple comparison test); <sup>§</sup> $P < 0.05$  as compared to diabetic control and glibenclamide (Dunn’s multiple comparisons test)

**Table 2:** Effect of cow urine ark on incision and dead space wound model

Group	Incision wound breaking strength (g)	Granulation tissue dry weight (mg/100 g body weight)	Hydroxyproline (µg/100 mg granulation tissue)
Diabetic control	265.8±10.4	26.1±0.6	19.3±0.5
Glibenclamide	369.2±8.9*	37.5±0.9*	24.4±0.9 <sup>@</sup>
Cow urine ark	457.5±19.5* <sup>#</sup>	39.1±1.4*	36.5±1.9* <sup>§</sup>

n=6 in each group, values are represented as mean±SEM. \* $P < 0.001$  as compared to diabetic control; <sup>#</sup> $P < 0.01$  as compared to glibenclamide; <sup>§</sup> $P < 0.001$  as compared to glibenclamide; <sup>@</sup> $P < 0.05$  as compared to diabetic control (Tukey–Kramer multiple comparison test)

**Table 3:** Semi-quantitative evaluation of histological changes in granulation tissue in dead space wound model

Histological changes	Groups		
	Diabetic control	Glibenclamide	Cow urine ark
Neutrophils	1.0±0.36	1.5±0.55	1.1±0.1
Macrophages	0.3±0.21	0.8±0.3	0.6±0.21
Fibroblasts	2.5±0.42	1.4±0.2	2.3±0.21
Neo-angiogenesis	1.8±0.54	1.2±0.16	1.4±0.2

n=6 in each group, values are represented as mean±SEMs. (Dunn’s multiple comparison test,  $P < 0.05$ )

based on previous research, which demonstrated significant anti-diabetic, antimicrobial, and antioxidant effects [11,12,22]. Besides, volatile fatty acids present in cow urine ark probably contribute to its antioxidant properties which might reduce oxidative stress in diabetic wounds [23]. Cow urine has been studied for wound healing activity in non-diabetic wounds using EW model, however, at the best of our knowledge; this study is the first to evaluate the wound healing activity of cow urine ark in diabetic wounds using different wound models [13].

In this study, we used a well-established model of diabetic wound healing, i.e., STZ-induced diabetes model [24]. This model has been shown to exhibit increased superoxide levels [25]. Thus, it provides suitable opportunity to study effects of the study agent on diabetic wound healing. We used glibenclamide as active control as lowering of blood glucose in diabetes has shown to promote wound healing [26]. This active control group helps to differentiate if cow urine ark has any additional advantage in promoting diabetic wound healing over blood glucose lowering agents.

In EW group, cow urine ark significantly increased wound contraction as compared to the diabetic as well as active control groups. This is similar to the previous study which showed significant wound contraction in non-diabetic rats topically treated with cow urine [13]. Reepithelization on the 11<sup>th</sup> post wounding day was not much affected by cow urine ark. Significant improvement in wound contraction as compared to glibenclamide in our study suggests that cow urine ark has an additional advantage over blood glucose lowering agents.

Cow urine ark had significantly increased the IW breaking strength, granulation tissue dry weight, and hydroxyproline contents compared to diabetic control. Furthermore, it had significantly increased IW breaking strength and granulation tissue hydroxyproline content as compared to glibenclamide group. Hyperglycemia associated with the DM is responsible for the generation of reactive oxygen species which in turn create excessive oxidative stress [27]. Increased oxidative stress leads to activation of matrix metalloproteinases (MMP) which increase collagen degradation and decreases collagen synthesis [28]. The antioxidant property of cow urine ark could decrease collagen degradation and increase collagen synthesis which can explain increased IW breaking strength and hydroxyproline content of granulation tissue in the treatment group.

Diabetic wounds are generally more susceptible to infection than non-diabetic wounds [29]. Wound infection is a common cause of wound chronicity. It prolongs the inflammatory phase by increasing the production of inflammatory cytokines which lead to additional tissue destruction as well as delays wound collagen synthesis [30]. Therefore, preventing wound infection would hasten wound healing process by promoting collagen synthesis. Various studies have demonstrated that cow urine, as well as its distillate, has antibacterial and antifungal activity against various clinical strains of these pathogens [8,22,31]. Thus, cow urine ark could have hastened the process of collagen formation by preventing the subtle wound infections which ultimately increased IW breaking

strength, granulation tissue dry weight and hydroxyproline contents in this study.

Histological examination of granulation tissue obtained from DWs did not reveal any significant difference among the groups in polymorphonuclear cell infiltration, macrophage, fibroblast, or neo-angiogenesis in our study set up. This is in contrast to the previous study which showed maximum polymorphonuclear cell infiltration, neovascularization and fibroblast proliferation in surgically created wounds [14]. This could probably be explained by the method by which we obtained granulation tissue. In our study, granulation tissue was obtained from foreign body material inserted in dead space created in groins of the rats. While they analyzed tissue obtained from wound margin and healthy skin.

There are several limitations in our study. The methods used for estimation of re-epithelialization in EW and hydroxyproline content in granulation tissue are relatively crude and less sensitive; hence, limit interpretation of the results. More sophisticated methods might have been used for this analysis, however, due to limited resources, it could not be performed in our setup.

## CONCLUSION

This study demonstrated that cow urine ark significantly enhances the collagen content and granulation tissue formation in diabetic wounds. Thus, it can be useful in accelerating wound healing in diabetic patients because of its property of enhancing granulation tissue formation. Further clinical trials in diabetic patients would be more helpful for its clinical application.

## ACKNOWLEDGMENT

We are thankful to Go-VigyanAnushandhanKendra, Nagpur, Maharashtra, India for providing cow urine ark for this study. We are also thankful to Department of Dental Diagnostic Science at The University of Texas Health Science Centre, San Antonio (UTHSCSA), Texas for developing the UTHSCSA image tool and making it freely available for research.

## REFERENCES

1. Verma R, Khanna P, Mehta B. National programme on prevention and control of diabetes in India: Need to focus. *Australas Med J* 2012;5:310-5.
2. Singer AJ, Clark RA. Cutaneous wound healing. *N Engl J Med* 1999;341:738-46.
3. Ramsey SD, Newton K, Blough D, McCulloch DK, Sandhu N, Reiber GE, *et al.* Incidence, outcomes, and cost of foot ulcers in patients with diabetes. *Diabetes Care* 1999;22:382-7.
4. Falanga V. Wound healing and its impairment in the diabetic foot. *Lancet* 2005;366:1736-43.
5. Traub O, Van Bibber R. Role of nitric oxide in insulin-dependent diabetes mellitus-related vascular complications. *West J Med* 1995;162:439-45.
6. Lan CC, Wu CS, Huang SM, Wu IH, Chen GS. High-glucose environment enhanced oxidative stress and increased interleukin-8 secretion from keratinocytes: New insights into impaired diabetic wound healing. *Diabetes* 2013;62:2530-8.
7. Dhama K, Chauhan RS, Singhal L. Anti-cancer activity of cow urine:

- Current status and future directions. *Int J Cow Sci* 2005;1:1-25.
8. Sathasivam A, Muthuselvam M, Rajendran R. Antimicrobial activities of cow urine distillate against some clinical pathogens. *Glob J Pharmacol* 2010;4:41-4.
  9. Randhawa GK. Cow urine distillate as bioenhancer. *J Ayurveda Integ Med* 2010;1:240-1.
  10. Gosavi DD, Sachdev D, Salwe K. Immunomodulatory and antioxidant effect of gomutraark in rats. *J Mahatma Gandhi Inst Med Sci* 2011;16:37-41.
  11. Sachdev DO, Gosavi DD, Salwe KJ. Evaluation of antidiabetic, antioxidant effect and safety profile of gomutra ark in wistar albino rats. *Anc Sci Life* 2012;31:84-9.
  12. Gururaja MP, Joshi AB, Joshi H, Sathyanarayana D, Subrahmanyam EV, Chandrashekhar KS. Antidiabetic potential of cow urine in streptozotocin induced diabetic rats. *Asian J Tradit Med* 2011;6:8-13.
  13. Sanganal JS, Jayakumar K, Jayaramu GM, TikareVP, Paniraj KL, Swetha R. Effect of cow urine on wound healing property in wistar Albino rats. *Vet World* 2011;4:317-21.
  14. Mishra R, Das LL, Sharma AK, Singh KK. Histomorphological evaluation of wound healing potential of cow urine in goats. *Indian J Vet Pathol* 2009;33:197-9.
  15. Ghori V, Mandavia DR, Patel TK, Tripathi CB. Effect of topical nitric oxide donor (0.2 % glyceryltrinitrate) on wound healing in diabetic wistar rats. *Int J Diabetes Dev Ctries* 2014;34:45-9.
  16. Morton JJ, Malone MH. Evaluation of vulnery activity by an open wound procedure in rats. *Arch Int Pharmacodyn Ther* 1972;196:117-26.
  17. Ehrlich HP, Hunt TK. The effects of cortisone and anabolic steroids on the tensile strength of healing wounds. *Ann Surg* 1969;170:203-6.
  18. Lee KH. Studies on the mechanism of action of salicylate. II. Retardation of wound healing by aspirin. *J Pharm Sci* 1968;57:1042-3.
  19. Woessner JF Jr. The determination of hydroxyproline in tissue and protein samples containing small proportions of this imino acid. *Arch Biochem Biophys* 1961;93:440-7.
  20. Dipasquale G, Meli A. Effect of body weight changes on the formation of cotton pellet-induced granuloma. *J Pharm Pharmacol* 1965;17:379-82.
  21. Abramov Y, Golden B, Sullivan M, Botros SM, Miller JJ, Alshahrour A, *et al.* Histologic characterization of vaginal vs. abdominal surgical wound healing in a rabbit model. *Wound Repair Regen* 2007; 15:80-6.
  22. Jarald E, Edwin S, Tiwari V, Garg R, Toppo E. Antioxidant and antimicrobial activities of cow urine. *Glob J Pharmacol* 2008;2:20-2.
  23. Krishnamurthi K, Dutta D, Sivanesan SD, Chakrabarti T. Protective effect of distillate and redistillate of cow's urine in human polymorphonuclear leukocytes challenged with established genotoxic chemicals. *Biomed Environ Sci* 2004;17:247-56.
  24. Sumi Y, Ishihara M, Kishimoto S, Takikawa M, Hattori H, Takikawa M, *et al.* Effective wound healing in streptozotocin-induced diabetic rats by adipose-derived stromal cell transplantation in plasma-gel containing fragmin/protamine microparticles. *Ann Plast Surg* 2014;72:113-20.
  25. Luo JD, Wang YY, Fu WL, Wu J, Chen AF. Gene therapy of endothelial nitric oxide synthase and manganese superoxide dismutase restores delayed wound healing in type 1 diabetic mice. *Circulation* 2004;110:2484-93.
  26. McMurry JF Jr. Wound healing with diabetes mellitus. Better glucose control for better wound healing in diabetes. *Surg Clin North Am* 1984;64:769-78.
  27. Schmidt AM, Hori O, Brett J, Yan SD, Wautier JL, Stern D. Cellular receptors for advanced glycation end products. Implications for induction of oxidant stress and cellular dysfunction in the pathogenesis of vascular lesions. *Arterioscler Thromb* 1994;14:1521-8.
  28. Sivik DA, Pagano PJ, Colucci WS. Oxidative stress regulates collagen synthesis and matrix metalloproteinase activity in cardiac fibroblasts. *Am J Physiol Cell Physiol* 2001;280:C53-60.
  29. Hirsch T, Spielmann M, Zuhaili B, Koehler T, Fossum M, Steinau HU, *et al.* Enhanced susceptibility to infections in a diabetic wound healing model. *BMC Surg* 2008;8:5.
  30. Doughty DR, Bonnie SD. Wound-healing physiology. EDs. In: Briant RA, Nix DP, editors. *Acute & Chronic Wounds; Current Management Concepts*. 3<sup>rd</sup> ed. USA: Mosby, Elsevier; 2007. p. 77.
  31. Shah CP, Patel DM, Dhami PD, Kakadia JA, Bhavsar DH, Vachhani UD, *et al.* *In vitro* screening of antibacterial activity of cow urine against pathogenic human bacterial strains. *Int J Curr Pharm Res* 2011;3:91-2.

© SAGEYA. This is an open access article licensed under the terms of the Creative Commons Attribution Non-Commercial License (<http://creativecommons.org/licenses/by-nc/3.0/>) which permits unrestricted, noncommercial use, distribution and reproduction in any medium, provided the work is properly cited.

Source of Support: Nil, Conflict of Interest: None declared.