

Postrenal acute kidney injury in a patient with unilateral ureteral obstruction caused by urolithiasis

A case report

Itsuro Kazama, MD, PhD^{a,*}, Toshiyuki Nakajima, MD, PhD^b

Abstract

Rationale: In patients with bilateral ureteral obstruction, the serum creatinine levels are often elevated, sometimes causing postrenal acute kidney injury (AKI). In contrast, those with unilateral ureteral obstruction present normal serum creatinine levels, as long as their contralateral kidneys are preserved intact. However, the unilateral obstruction of the ureter could affect the renal function, as it humorally influences the renal hemodynamics.

Patient concerns: A 66-year-old man with a past medical history of hypertension and diabetes mellitus came to our outpatient clinic because of right abdominal dullness.

Diagnoses: Unilateral ureteral obstruction caused by a radio-opaque calculus in the right upper ureter and a secondary renal dysfunction.

Interventions: As oral hydration and the use of calcium antagonists failed to allow the spontaneous stone passage, extracorporeal shock wave lithotripsy (ESWL) was performed.

Outcomes: Immediately after the passage of the stone, the number of red blood cells in the urine was dramatically decreased and the serum creatinine level almost returned to the normal range with the significant increase in glomerular filtration rate.

Lessons: Unilateral ureteral obstruction by the calculus, which caused reflex vascular constriction and ureteral spasm in the contralateral kidney, was thought to be responsible for the deteriorating renal function.

Abbreviations: AKI = postrenal acute kidney injury, EGF = epidermal growth factor, eGFR = estimated glomerular filtration rate, ESWL = extracorporeal shock wave lithotripsy, MCP-1 = monocyte chemoattractant protein-1, NSAIDs = nonsteroidal anti-inflammatory drugs.

Keywords: reflex vascular constriction, serum creatinine elevation, unilateral ureteral obstruction, ureteral spasm, urolithiasis

1. Introduction

Urinary tract obstruction is commonly caused by urolithiasis, transitional cell carcinoma and external compression by tumors, enlarged lymph nodes, and retroperitoneal fibrosis.^[1] Such patients are often asymptomatic, but abdominal dullness or the

flank pain is one of the typical clinical manifestations directly caused by the obstruction.^[1] Occasionally, such patients present additional symptoms or signs as a result of hydronephrosis, such as urinary tract infection, urine output changes, and hypertension.^[2–4] In patients with bilateral ureteral obstruction or bladder neck occlusion, the serum creatinine levels are often elevated, sometimes causing postrenal acute kidney injury (AKI).^[5] However, in patients with unilateral ureteral obstruction, the serum creatinine levels are usually normal, as long as their contralateral kidneys are preserved intact and have sufficient clearance capacity to excrete the nitrogenous wastes generated daily.^[6] In addition to postrenal causes, there are “prerenal” and “renal” causes of serum creatinine elevation, which account for the majority of causes leading to AKI.^[7] These include hypoperfusion in the renal vasculature and direct damage to the renal tubules or parenchyma, which are commonly triggered by dehydration, sepsis, or drugs. In previous studies, unilateral ureteral obstruction stimulated the renin secretion from the obstructed kidneys, and thus activated the renin-angiotensin system.^[4] This finding strongly suggested that mechanical obstruction of the ureter, which humorally influences the renal hemodynamics, could affect the renal function possibly by prerenal causes. Here, we report a case of unilateral urolithiasis complicated by a postrenal increase in the serum creatinine level. Unilateral ureteral obstruction by calculus, which caused reflex vascular constriction and ureteral spasm in the contralateral

Editor: Giuseppe Lucarelli.

Funding/support: This work was supported by MEXT KAKENHI Grant, No. 16K08484, and The Salt Science Research Foundation, No.1725 to IK.

The authors report no conflicts of interest.

^a Department of Physiology, Tohoku University Graduate School of Medicine, Seiryō-cho, Aoba-ku, ^b Internal Medicine, Iwakiri Hospital, Miyagino-ku, Sendai, Miyagi, Japan.

* Correspondence: Itsuro Kazama, Department of Physiology, Tohoku University Graduate School of Medicine, Seiryō-cho, Aoba-ku, Sendai, Miyagi 980-8575, Japan (e-mail: kazaitso@med.tohoku.ac.jp).

Copyright © 2017 the Author(s). Published by Wolters Kluwer Health, Inc. This is an open access article distributed under the terms of the Creative Commons Attribution-Non Commercial-No Derivatives License 4.0 (CCBY-NC-ND), where it is permissible to download and share the work provided it is properly cited. The work cannot be changed in any way or used commercially without permission from the journal.

Medicine (2017) 96:43(e8381)

Received: 2 August 2017 / Received in final form: 21 September 2017 /

Accepted: 3 October 2017

<http://dx.doi.org/10.1097/MD.00000000000008381>

kidney, was likely responsible for the deteriorating renal function.

2. Case presentation

A 66-year-old man came to our outpatient clinic because of abdominal dullness in the right flank region, which had persisted for a few days. He had a medical history of hypertension and diabetes mellitus, for which oral medications such as nifedipine, valsartan, sitagliptin, and voglibose had been prescribed for several years. Since several months before, microscopic hematuria on routine urinalysis had occasionally been pointed out. However, before his first visit to our clinic, the laboratory data kept showing the normal serum creatinine levels (Fig. 1), indicating the absence of chronic kidney disease caused by hypertension or diabetes mellitus. On physical examination, the patient was bending rightward because of the right abdominal dullness. His body temperature was 36.0°C, blood pressure was 146/90 mm Hg, and pulse rate was 72 beats/min. He weighed 72 kg and was 165 cm tall. He had right costovertebral angle tenderness without rebound pain or guarding, but there was no tenderness in the abdominal region. His bowel sounds were normal, and the liver and spleen were not palpable. Urinalysis showed gross hematuria with isomorphic red blood cells and pyuria. The dipstick test showed slight proteinuria and aciduria (urine pH 5.5), but there were no abnormal cast formations. Laboratory data showed an increase in the serum creatinine level (1.21 mg/dL) from his baseline level around 0.96 to 0.98 mg/dL (Fig. 1), indicating deteriorating renal function with the significant fall of the estimated glomerular filtration rate (eGFR) from 61.2 to 47.3 mL/min/1.73 m². However, other routine laboratory investigations, such as blood glucose level, electrolytes, and liver function tests, were normal. Ultrasound investigation of the kidneys showed unilateral hydronephrosis in the right kidney and dilatation of the ipsilateral urinary tract. The left kidney was intact without showing any signs of atrophy or swelling, indicating the absence of chronic renal insufficiency was absent. As the abdominal radiograph revealed the presence of a radio-opaque calculus in the upper portion of the right ureter (Fig. 2, arrow head), a diagnosis of urolithiasis caused by a right ureteral stone was made. From the physical findings, signs

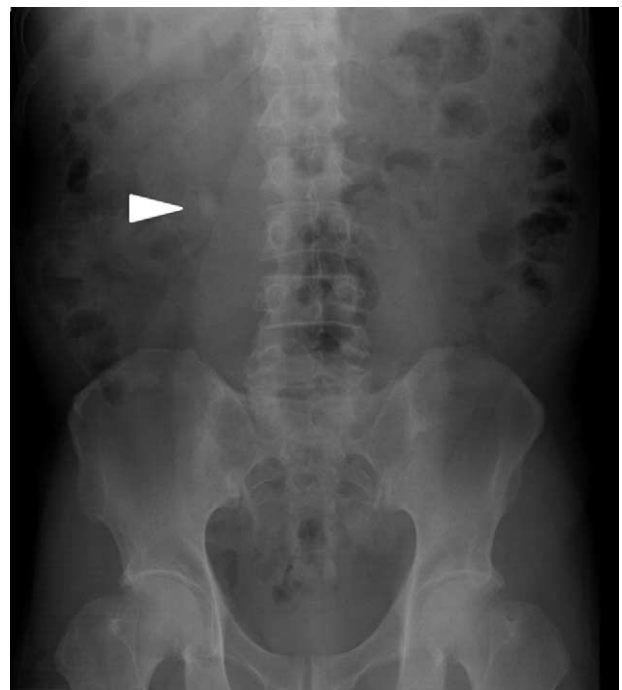

Figure 2. Abdominal radiograph on initial presentation. An abdominal radiograph of the patient on initial presentation showing a radio-opaque calculus with a longitudinal diameter larger than 10 mm in the upper portion of the right ureter (arrow head).

suggestive of dehydration were absent and there had been no recent use of additional drugs that could have caused renal tubular or parenchymal damage. Therefore, urolithiasis was most likely to be responsible for the increased serum creatinine level. Immediately after the diagnosis, the patient was referred to a urologist at a nearby clinic. Despite oral hydration and the use of calcium antagonists, the stone did not pass spontaneously. As the longitudinal diameter of the calculus was larger than 10 mm (Fig. 2), extracorporeal shock wave lithotripsy (ESWL) was performed (Fig. 1). After the procedure, the patient recognized the passage of the stone fragments into the urine for the next few days, during which the symptoms such as right abdominal dullness and gross hematuria completely disappeared. The fragments were later proven to be derived from a calcium oxalate calculus. In this case, we did not examine the urinary calcium or oxalate excretion. However, as he has a custom to eat much of foods that are rich in oxalate, such as spinach, nuts, chocolate, and tea, his urinary oxalate excretion was thought to be increased. Immediately after the passage of the stone, the number of red blood cells in the urine was dramatically decreased and the serum creatinine level almost returned to the normal range (Fig. 1), with the significant increase in eGFR (55.5 mL/min/1.73 m²). There was no recurrence of the symptoms or signs thereafter, indicating successful removal of the calculus and complete recovery from the deteriorating renal function.

This study was carried out in accordance with the principles of the Declaration of Helsinki and approved by the Ethics Committee of Iwakiri Hospital. Informed consent was obtained.

3. Discussion

Bilateral ureteral obstruction is a major cause of increased serum creatinine levels, sometimes leading to postrenal AKI. However,

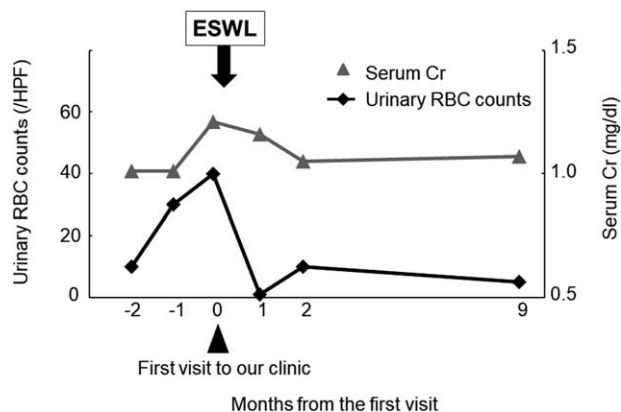


Figure 1. Changes in urinary red blood cell (RBC) counts and serum creatinine (Cr) level. After the passage of the stone by ESWL, the number of red blood cells in the urine was dramatically decreased and the serum creatinine level quickly returned to normal. There was no recurrence of the symptoms or signs thereafter indicating complete recovery from the deteriorating renal function. Cr = creatinine; ESWL = extracorporeal shock wave lithotripsy; RBC = red blood cell.

in patients with unilateral ureteral obstruction, the serum creatinine levels usually remained normal, as long as their contralateral kidneys are preserved intact.^[6] In the present case, although the obstruction of the ureter was unilateral, the patient showed a significant increase in the serum creatinine level (Fig. 1). However, there were no signs suggestive of dehydration and there were no recent uses of additional drugs that might have caused renal tubular parenchyma damage. As the patient's serum creatinine level returned to normal quickly after the removal of the calculus (Fig. 1), the unilateral ureteral obstruction was thought to be the primary cause of the deteriorating renal function. Previously, Maletz et al^[8] reported a rare case of reflex anuria and a decrease in renal function, which was caused by unilateral ureteral obstruction. According to a basic study using canine kidneys, the increased activities of the autonomic nervous system and the renin-angiotensin system were both responsible for the vascular and ureteral spasm in the contralateral kidneys.^[9] Later studies further revealed that nitric oxide contributed to the pre-glomerular or postglomerular vasoconstriction in reducing renal blood flow and ureteral pressure in the canine model of unilateral ureteral obstruction.^[10] In the present case, due to the long-term complication of diabetes mellitus, the patient's renal autonomic nervous system was thought to be overactivated.^[11] In addition, similar to the findings observed in unilateral renal artery stenosis,^[12] unilateral ureteral obstruction stimulates renin secretion from obstructed kidneys and thus activates the renin-angiotensin system.^[4] Consequently, in the present case, such neural and humoral abnormalities may have caused reflex vascular constriction and ureteral spasm in the contralateral kidneys. Such vasospastic phenomena could functionally lead to renal hypoperfusion and bilateral ureteral obstruction. This would deteriorate the renal function both "prerenally" and "postrenally," resulting in the elevation of the serum creatinine level in our patient.

Patients with urolithiasis are initially managed with pain medication and supportive hydration until the stone passes.^[13] In cases with large stones, drugs, such as calcium antagonists or α 1-adrenoreceptor blockers, are additionally required to facilitate spontaneous passage, or to reinforce the efficacy of lithotripsy.^[14] Using isolated ureteral tissues from humans or intact ureters from pigs, the previous studies have demonstrated that hyperpolarization in the smooth muscle cells inhibited the depolarization-induced Ca^{2+} entry, leading to relaxation of the ureters.^[15] In this regard, the use of the K^+ -channel openers, such as nicorandil and cromakalim, which hyperpolarize the cellular membrane,^[14,16] would ameliorate the ureteral spasm caused by the contralateral ureteral obstruction. On the contrary, vascular smooth muscle cells were shown to express voltage-dependent K^+ -channels, including Kv1.3 and Kv1.5, which play roles in the vasospastic constriction of the arteries.^[17,18] Using lymphocytes, our recent patch-clamp studies have demonstrated that drugs such as nonsteroidal anti-inflammatory drugs (NSAIDs), macrolide antibiotics, and statins effectively inhibit the Kv1.3-channels.^[19–21] Concerning such pharmacological properties, these commonly used drugs may be beneficial in ameliorating the renal vascular constriction caused by contralateral ureteral obstruction.

In basic studies, unilateral ureteral obstruction in neonatal or adult rat kidneys eventually lead to renal insufficiency later in life.^[22–24] In these studies, the relief of obstruction after 3 to 5 days temporarily attenuated the renal function, but progressively deteriorated renal vascular, glomerular, tubular, and interstitial injuries. It is well known that the recovery of renal function after

relief of ureteral obstruction depends on several factors including the location and duration of the obstruction, whether it is complete or partial, and the presence of infection. In particular, time before relief seems to be the most critical issue.^[25] Recently, Lucarelli et al^[26,27] demonstrated that the patients who were subjected to delayed relief of a ureteral obstruction had a long-term decrease in renal function and an increased risk of systemic hypertension. Regarding the pathophysiology of obstructive nephropathy, many studies have determined the molecular association in the development of tubulointerstitial injury.^[27] Among the molecules that are involved, the expression of monocyte chemotactic protein-1 (MCP-1) was increased in unilateral ureteral obstruction, but that of epidermal growth factor (EGF) was decreased.^[27] Therefore, reduced ratio of urinary EGF/MCP-1 has been considered to be a useful marker for obstructed nephropathy in humans. In the study of Lucarelli et al,^[26,27] the median ratio of urinary EGF/MCP1 was lower in patients who underwent delayed relief of the ureteral obstruction than those with more immediate relief. In addition, mercaptoacetyltriglycine clearance of the obstructed kidney and the EGF/MCP-1 ratio were directly correlated, while the urinary cytokine ratio and the time before relief were inversely correlated.^[26,27] In our patient, the ureteral obstruction was resolved immediately after the diagnosis was made. However, a careful observation will be necessary for the long-term development of renal damage and arterial hypertension.

4. Conclusion

We report a case of unilateral urolithiasis complicated by a postrenal increase in the serum creatinine level. Unilateral ureteral obstruction by the calculus, which caused the reflex vascular constriction and ureteral spasm in the contralateral kidney, was likely responsible for the deteriorating renal function.

Acknowledgment

We thank the staffs at Iwakiri Hospital for their assistance.

References

- [1] Klahr S. Urinary tract obstruction. *Semin Nephrol* 2001;21:133–45.
- [2] Klahr S. Pathophysiology of obstructive nephropathy. *Kidney Int* 1983;23:414–26.
- [3] Hwang SJ, Haas M, Harris HW Jr, et al. Transport defects of rabbit medullary thick ascending limb cells in obstructive nephropathy. *J Clin Invest* 1993;91:21–8.
- [4] Weidmann P, Beretta-Piccoli C, Hirsch D, et al. Curable hypertension with unilateral hydronephrosis. Studies on the role of circulating renin. *Ann Intern Med* 1977;87:437–40.
- [5] Meola M, Samoni S, Petrucci I, et al. Clinical scenarios in acute kidney injury: post-renal acute kidney injury. *Contrib Nephrol* 2016;188:64–8.
- [6] Gosmanova EO, Baumgarten DA, O'Neill WC. Acute kidney injury in a patient with unilateral ureteral obstruction. *Am J Kidney Dis* 2009;54:775–9.
- [7] Basile DP, Anderson MD, Sutton TA. Pathophysiology of acute kidney injury. *Compr Physiol* 2012;2:1303–53.
- [8] Maletz R, Berman D, Peelle K, et al. Reflex anuria and uremia from unilateral ureteral obstruction. *Am J Kidney Dis* 1993;22:870–3.
- [9] Francisco LL, Hoversten LG, DiBona GF. Renal nerves in the compensatory adaptation to ureteral occlusion. *Am J Physiol* 1980;238:F229–234.
- [10] Felsen D, Schulsinger D, Gross SS, et al. Renal hemodynamic and ureteral pressure changes in response to ureteral obstruction: the role of nitric oxide. *J Urol* 2003;169:373–6.

- [11] Salman IM, Ameer OZ, Sattar MA, et al. Renal sympathetic nervous system hyperactivity in early streptozotocin-induced diabetic kidney disease. *Neurorol Urodyn* 2011;30:438–46.
- [12] Covic A, Gusbeth-Tatomir P. The role of the renin-angiotensin-aldosterone system in renal artery stenosis, renovascular hypertension, and ischemic nephropathy: diagnostic implications. *Prog Cardiovasc Dis* 2009;52:204–8.
- [13] Miller NL, Lingeman JE. Management of kidney stones. *BMJ* 2007;334:468–72.
- [14] Canda AE, Turna B, Cinar GM, et al. Physiology and pharmacology of the human ureter: basis for current and future treatments. *Urol Int* 2007;78:289–98.
- [15] Quast U. Do the K⁺ channel openers relax smooth muscle by opening K⁺ channels? *Trends Pharmacol Sci* 1993;14:332–7.
- [16] Weiss R, Mevissen M, Hauser DS, et al. Inhibition of human and pig ureter motility in vitro and in vivo by the K⁽⁺⁾ channel openers PKF 217-744b and nicorandil. *J Pharmacol Exp Ther* 2002;302:651–8.
- [17] Cox RH, Folander K, Swanson R. Differential expression of voltage-gated K⁽⁺⁾ channel genes in arteries from spontaneously hypertensive and Wistar-Kyoto rats. *Hypertension* 2001;37:1315–22.
- [18] Novakovic A, Gojkovic-Bukarica L, Peric M, et al. The mechanism of endothelium-independent relaxation induced by the wine polyphenol resveratrol in human internal mammary artery. *J Pharmacol Sci* 2006;101:85–90.
- [19] Kazama I, Maruyama Y, Murata Y. Suppressive effects of nonsteroidal anti-inflammatory drugs diclofenac sodium, salicylate and indomethacin on delayed rectifier K⁺-channel currents in murine thymocytes. *Immunopharmacol Immunotoxicol* 2012;34:874–8.
- [20] Kazama I, Maruyama Y. Differential effects of clarithromycin and azithromycin on delayed rectifier K⁽⁺⁾-channel currents in murine thymocytes. *Pharm Biol* 2013;51:760–5.
- [21] Kazama I, Baba A, Maruyama Y. HMG-CoA reductase inhibitors pravastatin, lovastatin and simvastatin suppress delayed rectifier K⁽⁺⁾-channel currents in murine thymocytes. *Pharmacol Rep* 2014;66:712–7.
- [22] Chevalier RL, Kim A, Thornhill BA, et al. Recovery following relief of unilateral ureteral obstruction in the neonatal rat. *Kidney Int* 1999;55:793–807.
- [23] Chevalier RL, Thornhill BA, Chang AY. Unilateral ureteral obstruction in neonatal rats leads to renal insufficiency in adulthood. *Kidney Int* Nov 2000;58:1987–95.
- [24] Ito K, Chen J, El Chaar M, et al. Renal damage progresses despite improvement of renal function after relief of unilateral ureteral obstruction in adult rats. *Am J Physiol Renal Physiol* 2004;287:F1283–93.
- [25] Brandes S, Coburn M, Armenakas N, et al. Diagnosis and management of ureteric injury: an evidence-based analysis. *BJU Int* Aug 2004;94:277–89.
- [26] Lucarelli G, Ditunno P, Bettocchi C, et al. Delayed relief of ureteral obstruction is implicated in the long-term development of renal damage and arterial hypertension in patients with unilateral ureteral injury. *J Urol* 2013;189:960–5.
- [27] Lucarelli G, Mancini V, Galleggiante V, et al. Emerging urinary markers of renal injury in obstructive nephropathy. *BioMed Res Int* 2014;2014:303298.