



## Endoscopic management of gastric outlet obstruction of remnant stomach in a patient with Roux-en-Y gastric bypass

Vivek Kesar, MD,<sup>1</sup> John Magulick, MD,<sup>2</sup> Varun Kesar, MD,<sup>3</sup> Thiruvengadam Muniraj, MD, MRCP,<sup>2</sup> Harry R. Aslanian, MD<sup>2</sup>

Luminal stent placement for malignant gastric outlet obstruction is an efficacious alternative to surgical bypass in patients with advanced malignancy and limited life expectancy. Altered surgical anatomy, especially Roux-en-Y gastric bypass (RYGB) anatomy, can make endoscopic intervention challenging. EUS-guided access to the remnant stomach using a lumen-apposing metal stent (LAMS), recently termed gastric access temporary for endoscopy (GATE), has been used to perform endoscopic submucosal dissection, EUS-guided tissue sampling, and various pancreaticobiliary interventions. We present a case using a variant of the GATE technique to allow endoscopic palliation of malignant gastric outlet obstruction of the remnant stomach (Video 1, available online at [www.VideoGIE.org](http://www.VideoGIE.org)).

### INTRODUCTION

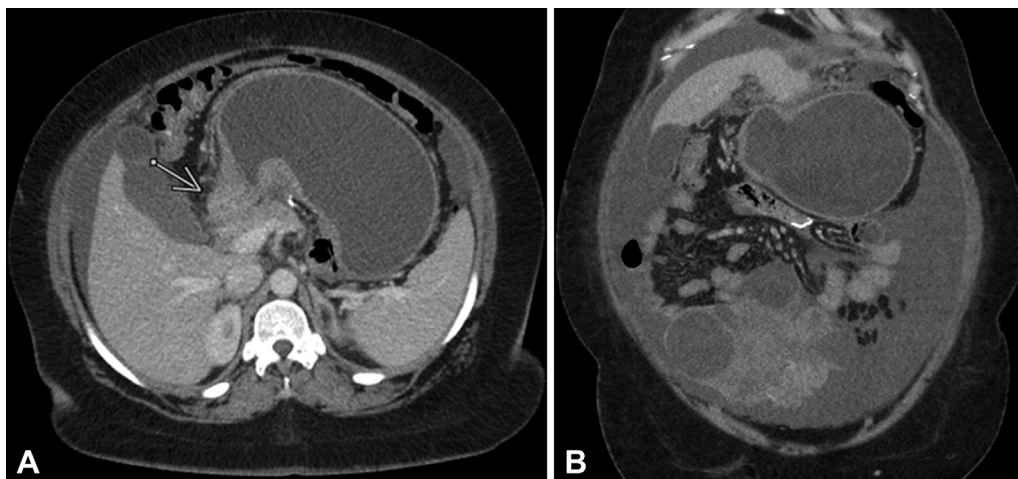
Management of malignant gastric outlet obstruction with luminal stents is a safe and efficacious alternative to surgical bypass in patients with limited life expectancy.<sup>1</sup> However, altered surgical anatomy, especially RYGB with long bypass limbs, makes endoscopic intervention for pancreaticobiliary disorders or other adverse events of malignancy challenging or impossible. Although it may be possible to access the

upper GI tract and pancreaticobiliary system using device-assisted enteroscopy, most conventional therapeutic accessories are not compatible with these endoscopes. Furthermore, these procedures are time consuming and have suboptimal technical success rates.<sup>2</sup>

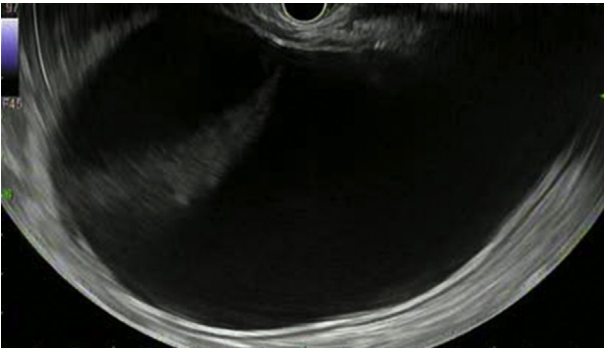
Given these limitations and the advent of the LAMSs, the EUS-directed transgastric ERCP technique was recently developed to allow access to the remnant stomach in patients with RYGB anatomy and to allow ERCP to be performed in the usual manner. This has resulted in high technical and clinical success with minimal adverse events and high rates of gastrogastic fistula closure.<sup>3-5</sup> EUS-guided access to the remnant stomach using a LAMS, recently termed GATE, has also been used to treat benign remnant outlet obstruction<sup>6</sup> and to perform endoscopic submucosal dissection<sup>7</sup> and EUS-guided tissue sampling.<sup>8</sup> We present a case in which a variant of the GATE technique allowed endoscopic palliation of malignant gastric outlet obstruction of the remnant stomach.

### CASE REPORT

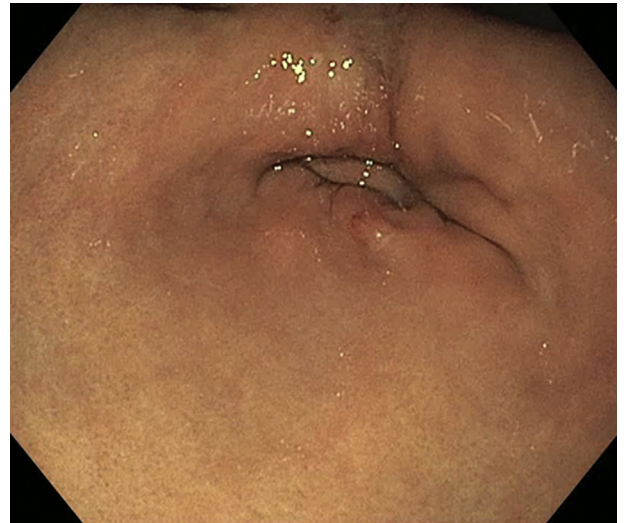
A 38-year-old woman with a history of RYGB for weight loss had been recently diagnosed with metastatic signet cell adenocarcinoma of GI origin after biopsy testing of a



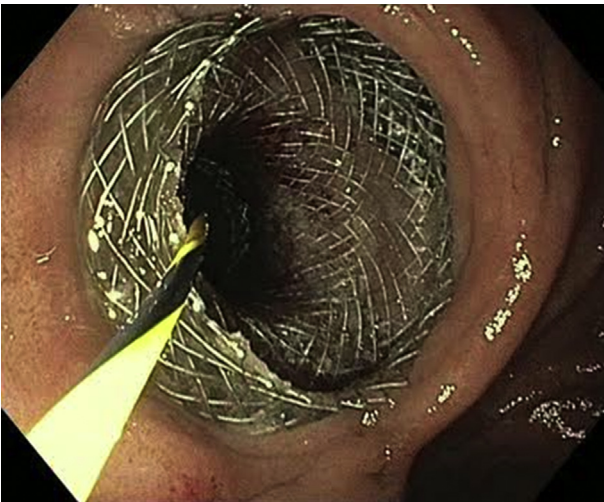
**Figure 1.** CT scan: axial (A) and coronal (B) view of gastric outlet obstruction.



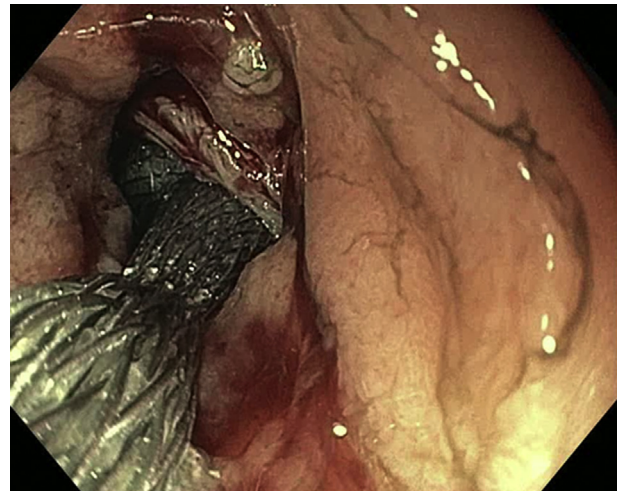
**Figure 2.** EUS view of dilated gastric remnant.



**Figure 4.** Pyloric stricture.



**Figure 3.** Lumen-apposing metal stent placement.



**Figure 5.** Lumen-apposing metal stent rescue.

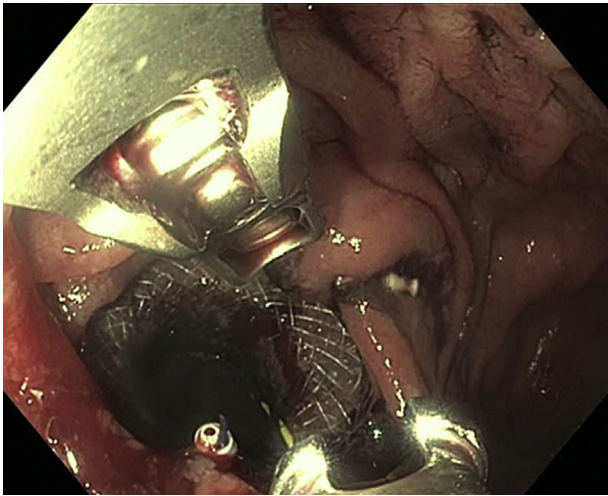
lytic bone lesion in the pelvis. She presented to our emergency department with abdominal pain, intractable nausea, and vomiting.

A CT scan on presentation (Fig. 1) revealed thickening of the duodenal bulb and pylorus with resultant obstruction of the gastric remnant. After a multidisciplinary discussion with surgical and medical oncology, she was not deemed to be a surgical candidate and was offered endoscopic therapy. EUS evaluation was performed from the gastric pouch, which revealed a dilated gastric remnant (Fig. 2).

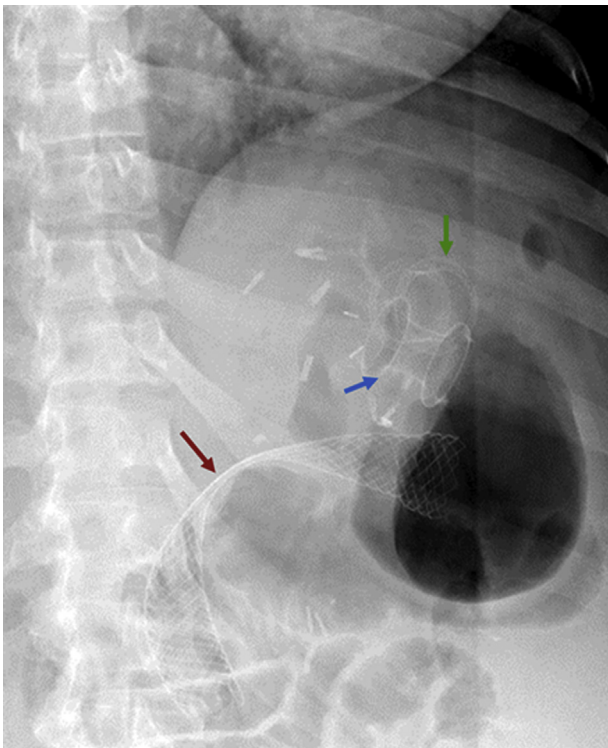
An EUS-guided gastrogastrostomy was created using a 20- × 10-mm electrocautery-enhanced LAMS (Hot-Axios; Boston Scientific, Boston, Mass, USA) (Fig. 3), and a 0.035-inch jagwire (Boston Scientific) was placed via the LAMS delivery system. The LAMS lumen was dilated to 15 mm with a CRE balloon (Boston Scientific). The remnant stomach was then evaluated with a therapeutic gastroscope, which revealed severe stenosis at the level of the pylorus (Fig. 4).

Because of the angulation required for evaluation of the pyloric stricture, the previously placed LAMS was noted to have migrated into the gastric remnant. An additional 20-mm LAMS was then deployed under endoscopic guidance over the guidewire and across the gastrogastrostomy (Fig. 5) and was secured in place using an over-stitch endoscopic suturing system (Apollo Endosurgery, Austin, Tex, USA) (Fig. 6). To prevent drainage of gastric contents into the gastric pouch only via the LAMS, which may increase risk of aspiration, and to provide additional palliation of nausea, we placed a 22- × 90-mm uncovered duodenal stent (Wall-Flex; Boston Scientific) across the stenosis (Fig. 7). The patient's abdominal discomfort and nausea improved immediately after the procedure, and she





**Figure 6.** Lumen-apposing metal stent suture.



**Figure 7.** Fluoroscopic image after duodenal stent deployment. *Green arrow*, dislodged lumen-apposing metal stent (LAMS). *Blue arrow*, secured LAMS. *Red arrow*, duodenal stent across the stricture.

had no signs of recurrent gastric outlet obstruction for the last 8 weeks of follow-up.

## CONCLUSION

This case illustrates the utility of the GATE technique in accessing the remnant stomach to allow palliation of malig-

nant gastric outlet obstruction. Adoption of this technique is likely to expand to other therapeutic indications for the excluded upper GI tract. Although this maneuver holds significant promise, our case also underscores the risk of LAMS migration if therapeutic endoscopy is undertaken during the index procedure, which has been reported in 15% of cases.<sup>5</sup> A recent case series addressed this challenge and demonstrated the effectiveness of stent fixation to prevent migration.<sup>9</sup> We recommend fixation of the LAMS with endoscopic suturing if therapy is planned at the time of gastrogastrostomy creation.

## DISCLOSURE

*All authors disclosed no financial relationships.*

*Abbreviations:* GATE, gastric access temporary for endoscopy; LAMS, lumen-apposing metal stents; RYGB, Roux-en-Y gastric bypass.

## REFERENCES

1. Jeurnink SM, van Eijck CH, Steyerberg EW, et al. Stent versus gastrojejunostomy for the palliation of gastric outlet obstruction: a systematic review. *BMC Gastroenterol* 2007;7:18.
2. Shah RJ, Smolkin M, Yen R, et al. A multicenter, U.S. experience of single-balloon, double-balloon, and rotational overtube-assisted enteroscopy ERCP in patients with surgically altered pancreaticobiliary anatomy (with video). *Gastrointest Endosc* 2013;77:593-600.
3. James TW, Baron TH. Endoscopic ultrasound-directed transgastric ERCP (EDGE): a single-center US experience with follow-up data on fistula closure. *Obes Surg* 2019;29:451-6.
4. Ngamruengphong S, Nieto J, Kunda R, et al. Endoscopic ultrasound-guided creation of a transgastric fistula for the management of hepatobiliary disease in patients with Roux-en-Y gastric bypass. *Endoscopy* 2017;49:549-52.
5. Tyberg A, Nieto J, Salgado S, et al. Endoscopic ultrasound (EUS)-directed transgastric endoscopic retrograde cholangiopancreatography or EUS: mid-term analysis of an emerging procedure. *Clin Endosc* 2017;50:185-90.
6. de Moura DTH, Bazarbashi AN, Schulman AR, et al. Multi-bypass with the use of lumen-apposing metal stents to maintain luminal continuity of the GI tract in a patient with altered anatomy. *VideoGIE* 2019;4:258-60.
7. Ge PS, Aihara H, Thompson CC, Ryou M. Duodenal endoscopic submucosal dissection and sutured defect closure across a lumen-apposing metal stent. *VideoGIE* 2018;4:172-5.
8. Lajin M, Catalano MF, Khan N, et al. EDGE Procedure to allow EUS/FNB of an uncinate process pancreatic mass in a patient with gastric-bypass anatomy using a 20-mm lumen-apposing metal stent. *VideoGIE* 2018;3:399-400.
9. Irani S, Yang J, Khashab MA. Mitigating lumen-apposing metal stent dislodgment and allowing safe, single-stage EUS-directed transgastric ERCP. *VideoGIE* 2018;3:322-4.

University of Massachusetts-Baystate Medical Center, Springfield, Massachusetts (1), Yale School of Medicine, New Haven, Connecticut (2), Virginia Tech University-Carilion Clinic, Blacksburg, Virginia (3).

If you would like to chat with an author of this article, you may contact Dr Kesar at [kesar.vivek@gmail.com](mailto:kesar.vivek@gmail.com).

Copyright © 2020 American Society for Gastrointestinal Endoscopy. Published by Elsevier Inc. This is an open access article under the CC BY-NC-ND license (<http://creativecommons.org/licenses/by-nc-nd/4.0/>).

<https://doi.org/10.1016/j.vgie.2020.06.018>