

# Successful treatment of unilateral neck pain with transforaminal epidural steroid injection on the left C3 nerve root: a case report

Journal of International Medical Research

48(11) 1–4



© The Author(s) 2020

Article reuse guidelines:

[sagepub.com/journals-permissions](https://sagepub.com/journals-permissions)

DOI: 10.1177/0300060520969538

[journals.sagepub.com/home/imr](https://journals.sagepub.com/home/imr)

Min Cheol Chang<sup>1</sup> ,  
Mathieu Boudier-Revéret<sup>2</sup> , Ming-Yen Hsiao<sup>3</sup>  
and Shaw-Gang Shyu<sup>3</sup>

## Abstract

In clinical practice, neck pain is one of the most common complaints. Although most of the cervical radicular pain is manifested in the neck and upper extremities, C3 or C4 radicular pain only results in neck pain. It does not produce upper extremity radiating pain. This case report describes a 70-year-old male that presented with a numeric rating scale score of 5 out of 10 for the left neck pain that he had been experiencing for the previous 1 month. Hyperalgesia was present on the left C3 dermatome. Foraminal stenosis at the left C2–C3 was observed on cervical magnetic resonance imaging. In order to manage the neck pain on the left side due to the foraminal stenosis at the left C2–C3, a transforaminal epidural steroid injection (TFESI) was undertaken on the left C3 nerve root. Thirty minutes after TFESI, the patient's neck pain had completely resolved. At the 1-month and 3-month follow-ups, no neck pain was evident. Clinicians should consider the possibility of C3 radicular pain as a cause of neck pain, especially when the neck pain presents as neuropathic pain combined with sensory deficits.

## Keywords

Neck pain, transforaminal epidural steroid injection, radicular pain, neuropathic pain

Date received: 22 June 2020; accepted: 8 October 2020

<sup>1</sup>Department of Physical Medicine and Rehabilitation, College of Medicine, Yeungnam University, Namku, Taegu, Republic of Korea

<sup>2</sup>Department of Physical Medicine and Rehabilitation, University of Montreal Health Centre, Montreal, Canada

<sup>3</sup>Department of Physical Medicine and Rehabilitation, National Taiwan University Hospital, College of Medicine, National Taiwan University, Taipei

### Corresponding author:

Mathieu Boudier-Revéret, Hôtel-Dieu du Centre hospitalier de l'Université de Montréal, 3840 Saint-Urbain Street, Montreal, QC, Canada H2W 1T8.

Email: [mathieu.boudier-reveret@umontreal.ca](mailto:mathieu.boudier-reveret@umontreal.ca)



## Introduction

In clinical practice, neck pain is one of the most common complaints. Over half of the general population experiences neck pain at some time in their life.<sup>1</sup> The origins of neck pain are various, including the intervertebral disc, cervical facet joint, atlanto-axial joint, ligament, neck muscle and cervical disc. Thus, a detailed evaluation in order to discover the precise source of the neck pain is essential for initiating the appropriate treatment.<sup>2-5</sup>

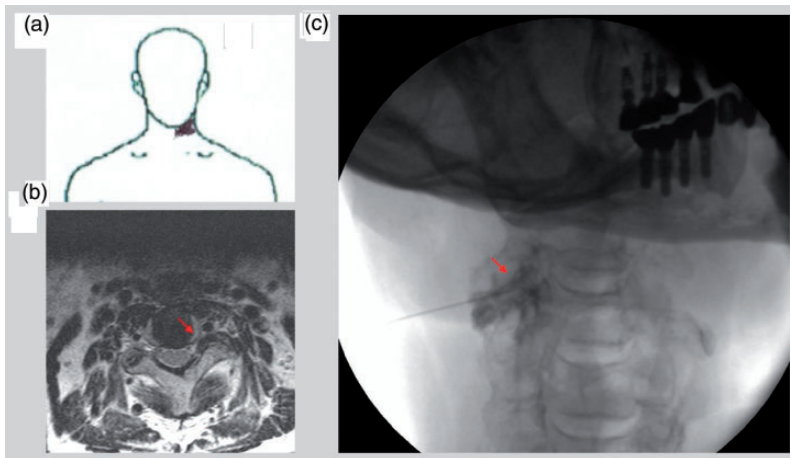
Regarding cervical radicular pain, the pain is present in the neck and upper extremities. However, the dermatomes of the high cervical levels (C3 or C4) are confined to the neck.<sup>6,7</sup> Therefore, C3 or C4 radicular pain does not result in upper extremity radiating pain and would cause only neck pain.

This case report presents a patient whose left neck pain was the result of foraminal stenosis at the left C2–C3 that was successfully managed by transforaminal epidural

steroid injection (TFESI) at the left C3 nerve root.

## Case report

A 70-year-old male attended the Department of Physical Medicine and Rehabilitation, College of Medicine, Yeungnam University, Namku, Taegu, Republic of Korea in September 2019 with left neck pain that had been present for the previous 1 month. He had tingling and piercing pain at his left anterior, lateral and posterior neck regions (Figure 1A). His pain was confined to his neck and did not present at the posterior scapular area or the upper limbs. The numeric rating scale pain score was 5 out of 10. On physical examination, the Spurling manoeuvre (left cervical lateroflexion with axial loading) greatly increased the patient's tingling and caused piercing left neck pain. Hyperalgesia was also present at the left C3 dermatome. No motor weakness or sensory deficits were



**Figure 1.** Representative imaging from a 70-year-old male that presented with left neck pain that had been present for the previous 1 month. (a) The area of pain was drawn by the patient before his treatment. (b) Axial T2-weighted cervical magnetic resonance imaging displayed foraminal stenosis at the left C2–C3 (arrow). (c) Fluoroscopy-guided transforaminal epidural steroid injection on the left C3 nerve root was performed, here shown in the antero-posterior view (a lateral view of the needle position was also required to confirm optimal localization, but not shown in this figure). The contrast material is seen spreading into the left C3 nerve root and the epidural space (arrow).

present in his upper limbs. Deep tendon reflexes were normal in all four limbs, with bilateral downward plantar responses. On cervical magnetic resonance imaging (MRI), foraminal stenosis at the left C2–C3 was revealed (Figure 1B).

The patient showed a positive response to a diagnostic fluoroscopy-guided left C3 selective nerve root block with 0.5 ml of 1% lidocaine. Therefore, it was confirmed that the patient's neck pain was the result of left C3 radiculopathy secondary to left C2–C3 foraminal stenosis. We therefore performed TFESI on the left C3 nerve root.

An aseptic technique was adopted for the TFESI procedure. The patient was placed in a supine position under C-arm fluoroscopy (Siemens, Erlangen, Germany). To focus the target, the C-arm was rotated toward the region and the cranial–caudal angle was controlled to focus on the C2–C3 intervertebral foramen. A 26-gauge 90 mm spinal needle was inserted into the skin and advanced to the anterior half of the superior articular process at the cervical spine. The depth of the needle tip was confirmed using the anterior–posterior view and lateral view of the C-arm. A test dose of contrast medium (0.2–0.3 ml) was injected to determine whether the needle tip was placed in the proper location. Further injection of the contrast medium was then completed under real-time fluoroscopic monitoring. Subsequently, 20 mg (0.5 mg) of dexamethasone mixed with 0.25 ml of 0.125% bupivacaine and 1.25 ml of normal saline were injected (Figure 1C). Thirty minutes after TFESI, the patient's neck pain had completely resolved. At the 1-month and 3-month follow-ups, no neck pain was evident.

## Discussion

This current case report described a patient with left neck pain that exhibited a successful response to TFESI on the left C3 nerve

root. This current patient's pain completely resolved for at least 3 months following the TFESI procedure.

When a patient complains of pain confined to the neck, clinicians usually consider facet-origin, muscle-origin or discogenic neck pain as potential aetiologies.<sup>2–5</sup> However, high cervical (C3 or C4) radicular pain that also appears in the form of neck pain does not radiate to the upper limbs.<sup>6,7</sup> As the incidence of high cervical radicular pain is much lower than radicular pain at the lower levels from C5 to C8, clinicians often do not consider high cervical radicular pain as the origin of neck pain.

It was our opinion that this current patient's pain was cervical radicular pain on the basis of the nature of his pain (tingling and piercing pain, suggesting a neuropathic character) and the findings of the physical examination (sensory deficit on C3 dermatome, positive Spurling manoeuvre). This diagnosis was confirmed as left C3 radicular pain with a cervical spine MRI and a selective nerve root block of the left C3 nerve root. This current case report is the first to show the successful treatment outcome of C3 radicular pain using TFESI.

The compression of the nerve root induces the expression of various inflammatory cytokines and chemokines. This is one of the main causes of the radicular pain due to cervical foraminal stenosis.<sup>8–10</sup> The steroid injected via the TFESI procedure reduces the production and release of inflammation-related mediators surrounding the cervical nerve root.<sup>8</sup> Decreased inflammation can also reduce oedema at the nerve root and/or the tissues surrounding the nerve root. This can produce space between the nerve root and the bony exit and reduce the degree of compression on the nerve root. In addition, steroids are known to inhibit neural transmission of pain signals through the nociceptive C-fibres.<sup>9</sup>

This current case report illustrates that pain confined to the neck can occur due to C3 radicular pain and it can be successfully managed using TFESI. Clinicians are recommended to consider the possibility of C3 radicular pain as the origin of neck pain, especially when the patient's neck pain presents as neuropathic pain combined with sensory deficits. TFESI is a useful therapeutic option for treating C3 radicular pain. Also, because the needle path during cervical TFESI can frequently overlap with a portion of the vertebral artery, the injection under the guidance of computed tomography is helpful to avoid inadvertent arterial puncture.

### Declaration of conflicting interest

The authors declare that there are no conflicts of interest.

### Funding

The authors disclosed receipt of the following financial support for the research, authorship, and/or publication of this article: The present study was supported by a National Research Foundation of Korea grant funded by the Government of South Korea (grant no. NRF-2019M3E5D1A02069399).

### ORCID iDs

Min Cheol Chang  <https://orcid.org/0000-0002-7629-7213>

Mathieu Boudier-Rev  ret  <https://orcid.org/0000-0003-0259-8520>

### References

- Childs JD, Cleland JA, Elliott JM, et al. Neck pain: Clinical practice guidelines linked to the International Classification of Functioning, Disability, and Health from the Orthopedic Section of the American Physical Therapy Association. *J Orthop Sports Phys Ther* 2008; 38: A1–A34.
- Cerezo-T  llez E, Torres-Lacomba M, Mayoral-Del Moral O, et al. Prevalence of Myofascial Pain Syndrome in Chronic Non-Specific Neck Pain: A Population-Based Cross-Sectional Descriptive Study. *Pain Med* 2016; 17: 2369–2377.
- Kwak SY and Chang MC. Effect of intradiscal pulsed radiofrequency on refractory chronic discogenic neck pain: A case report. *Medicine (Baltimore)* 2018; 97: e0509.
- Lim JW, Cho YW, Lee DG, et al. Comparison of Intraarticular Pulsed Radiofrequency and Intraarticular Corticosteroid Injection for Management of Cervical Facet Joint Pain. *Pain Physician* 2017; 20: E961–E967.
- Shin SM, Kwak SG, Lee DG, et al. Clinical Effectiveness of Intra-articular Pulsed Radiofrequency Compared to Intra-articular Corticosteroid Injection for Management of Atlanto-occipital Joint Pain: A Prospective Randomized Controlled Pilot Study. *Spine (Phila Pa 1976)* 2018; 43: 741–746.
- Poletti CE. C2 and C3 pain dermatomes in man. *Cephalalgia* 1991; 11: 155–159.
- Ross DA and Ross MN. Diagnosis and Treatment of C4 Radiculopathy. *Spine (Phila Pa 1976)* 2016; 41: 1790–1794.
- Nahm FS, Lee PB, Choe GY, et al. Therapeutic effect of epidural hyaluronic acid in a rat model of foraminal stenosis. *J Pain Res* 2017; 10: 241–248.
- Olmarker K, Byrod G, Cornefjord M, et al. Effects of methylprednisolone on nucleus pulposus-induced nerve root injury. *Spine (Phila Pa 1976)* 1994; 19: 1803–1808.
- Olmarker K, Rydevik B, Holm S, et al. Effects of experimental graded compression on blood flow in spinal nerve roots. A vital microscopic study on the porcine cauda equina. *J Orthop Res* 1989; 7: 817–823.