



Received: 2016.06.21  
Accepted: 2016.08.31  
Published: 2017.04.28

**Authors' Contribution:**

- A** Study Design
- B** Data Collection
- C** Statistical Analysis
- D** Data Interpretation
- E** Manuscript Preparation
- F** Literature Search
- G** Funds Collection

## A Novel Triage Tool: Optic Nerve Sheath Diameter in Traumatic Brain Injury and its Correlation to Rotterdam Computed Tomography (CT) Scoring

Sudha Kiran Das<sup>ABCDEF</sup>, Sachin P. Shetty<sup>ABCDEF</sup>, Kamal Kumar Sen<sup>DEF</sup>

Department of Radiodiagnosis and Imaging, JSS Medical College and Hospital (JSS University), Mysore, Karnataka, India

**Author's address:** Sudha Kiran Das, Department of Radiodiagnosis and Imaging, JSS Medical College and Hospital (JSS University), M G Road, Mysore 570004 Karnataka, India, e-mail: sudha7492@gmail.com

**Background:**

Optic nerve sheath diameter (ONSD) evaluated in CT imaging as well as Rotterdam CT Score (RCTS) are proven independent predictors of outcome in patients with traumatic brain injury (TBI). To date, no study has correlated ONSD on admission CT scan with RCTS.

**Material/Methods:**

Retrospective cohort study comprised of consecutive patients undergoing CT imaging for traumatic brain injury recruited between January and October 2015. Bilateral ONSD was measured 3 mm behind the eyeball in axial and sagittal planes and mean value was calculated. RCTS was assessed on the same CT images, bias was eliminated by blinding RCTS to ONSD measurement.

**Results:**

150 patients were included; mean age in the group was  $42.94 \pm 16.7$  years. ONSD in mild TBI, RCTS 2 and 3 were 3.3 mm (SD 0.39 mm) and 4.1 mm (0.047 mm), respectively. Mean ONSD in moderate and severe TBI (RCTS score 4 and above) was 4.83 mm and above, SD 0.4 mm. Mean ONSD correlated with occurrence of diffuse cerebral oedema, presence of subdural and extradural hematoma; however in isolation there was no statistical significance.

**Conclusions:**

Higher ONSD was observed in patients with moderate and severe TBI, correlating with admission RCTS of 4 and above. Subsequent increase in ONSD was also found with increase in RCTS. ONSD could serve as an initial triage tool in the emergency department as well as a method of determining the need for sequential CT in patients with mild TBI.

**MeSH Keywords:**

Brain Injuries • Optic Nerve • Tomography, Spiral Computed

**PDF file:**

<http://www.polradiol.com/abstract/index/idArt/900196>

### Background

Traumatic brain injuries (TBIs) are the leading cause of morbidity, mortality, disability and socioeconomic losses in India and other developing countries. It is estimated that nearly 1.5 to 2 million persons are injured and 1 million succumb to death every year in India. Road traffic injuries are the leading cause (60%) of TBIs followed by falls (20–25%) and violence (10%) [1–3].

Over the decades, neuroimaging techniques have explored radiological markers assessing the severity of traumatic brain injury, which could be suitable for prognostication. Two main classification systems evolved, the Marshall CT classification and Rotterdam CT classification score [RCTS].

Marshall Classification did not take into consideration epidural and subdural lesions separately nor did it include traumatic subarachnoid haemorrhage in the prognostication. Rotterdam CT Scoring System, however, did address some of the inherent limitations of Marshall Classification. Validated by numerous studies, RCTS proved to be an independent predictor of outcome in TBI [4,6–8].

Evaluation of elevated intracranial pressure (eICP) is pivotal to management of TBI, as it can be potentially fatal in the event of non-intervention [5]. Timely diagnosis and intervention have a positive impact on morbidity and mortality. The gold standard for diagnosis of eICP, an external ventricular device (EVD), is highly invasive, unavailable in the initial assessment, and may be contraindicated in

patients with coagulopathies. Measurement of optic nerve sheath diameter (ONSD) recently emerged as an alternative non-invasive method of monitoring intracranial pressure (ICP) [11,12].

Estimates of raised ICP by sonographic or CT ONSD allow rapid detection of significant intracranial hypertension. The optic nerve sheath is continuous with the dura mater, and its contents are continuous with the subarachnoid space. In the anterior part of the optic nerve, the sheath is distensible and can expand in response to raised cerebrospinal fluid pressure, leading to an increase in the optic nerve sheath diameter [9,10]. When eICP is suspected, but invasive ICP monitoring cannot be used or is not clearly recommended, ONSD estimation of raised ICP is of great clinical value, aiding in early intervention.

Sonographic measurements of ONSD have been shown correlate well with CT measurements of ONSD in healthy subjects, although CT scans tended to overestimate ONSD by 10% compared to ultrasound measurements. This was also demonstrated in patients with raised ICP, where CT scan-based ONSD measurements had higher cut off values, i.e. 6.5 mm compared to 5.4 mm in ultrasound examination [13–15].

ONSD measured on CT imaging has the advantage of objectivity and simplicity, and most importantly, remains the only existing tool for taking objective, retrospective measurements of ICP in patients for whom real-time ICP observations are not available; however it is limited by cost and cumulative radiation dose.

This study aimed to correlate optic nerve sheath diameter to RCTS on thin slice CT scan in patients with traumatic brain injury, in order to assess for linear correlation on admission CT.

## Material and Methods

Retrospective cohort study comprised all consecutive patients undergoing CT imaging for traumatic brain injury from January to October 2015. The study was conducted at JSS Medical College and Hospital which is a tertiary care centre with a dedicated trauma and neurosurgical unit.

All patients who had undergone CT scanning (128-Slice, Philips ingenuity) were included into the study based on convenience consecutive sampling; a total of 150 were included into the study regardless of age and gender. Patients with incomplete data or those with unilateral or bilateral orbital injury precluding ONSD measurements were excluded from the study. All admission CT scans were assessed for ONSD and RCTS, and double blinded to eliminate bias.

### Measurements of ONSD and RCTS

Admission brain CTs of all patients were reviewed using Picture Archiving and Communication Software (PACS) and the individual diameter of each optic nerve exactly 3 mm behind the posterior limit of the eyeball was measured on 3 mm-thick slices in both axial and sagittal planes. Diameters of both optic nerves were measured and a mean

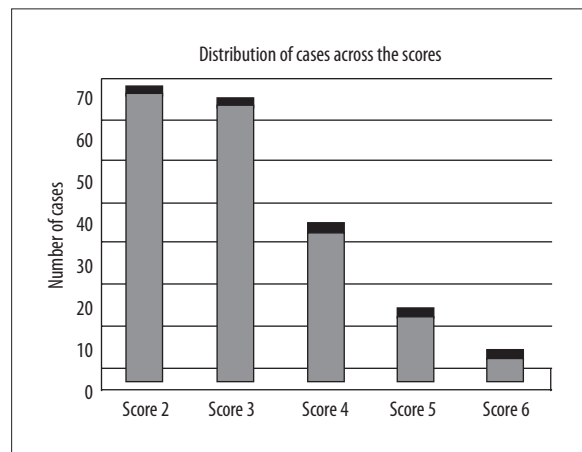


Figure 1. Distribution of cases across the Rotterdam CT Scores.

was obtained for each patient (Figure 1). Preoperative brain CT scan of each patient was also scored according to the Rotterdam CT Scoring (RCTS) as described by the original authors; the scoring was performed on a different occasion as to eliminate bias [8–10].

### Analysis

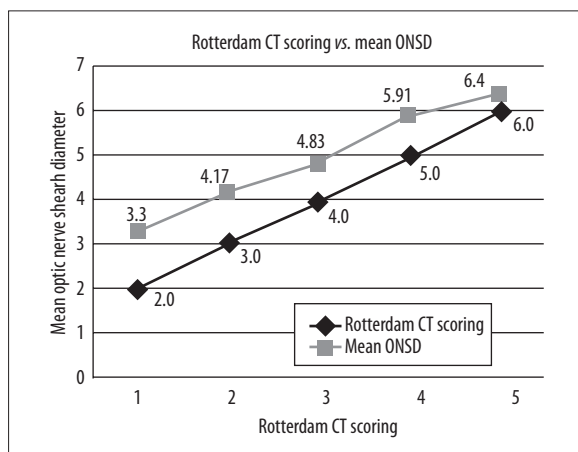
Data were analysed using SPSS v. 19. Means and standard deviations were calculated for continuous variables with normal distributions. Patients were divided into two groups, i.e., mild and severe TBI (RCTS score of 2 & 3 indicating mild TBI and 4 and above – severe TBI). Correlation of RCTS with ONSD documented on admission CT was calculated. In the Spearman's Rho test, the value of R was 1 and p value in the two tailed test was 0; these values are statistically significant rendering an association between the two variables as significant.

## Results

One hundred and fifty patients fulfilled the inclusion criteria and were included in the study. The majority of patients were male, i.e. 121 (81%). Mean age was  $42.94 \pm 16.7$  years. The most common causes of head trauma were: motor vehicle accident followed by a fall from height and assault. All patients underwent a brain CT scan within two hours from presentation to the ER. Distribution of cases across the groups based on RCTS is depicted in Figure 1.

The mean ONSD on CT imaging vs. RCTS is depicted in Figure 2. The graph also highlights a steady increase in the mean ONSD with an increase in RCTS this association being statistically significant with p value of Pearson's R equal to 0.00001. Receiver operator curve analysis [ROC] for critical Rotterdam Score vs. with Optic Nerve Sheath diameter was performed, demonstrating statistical significance for the area under the curve for critical RCTS vs. ONSD: 0.914 [95% CI: 0.907–0.974], as depicted in Figure 3.

The mean ONSD documented with RCTS 2 and 3 was found to be in a normal range as documented in the literature, whilst that of RCTS 4, 5 and 6 were of values 5.2 mm and higher, indicating raised ICP. Mean ONSD values among different groups divided depending on radiological features of



**Figure 2.** Line diagram depicting mean ONSD across Rotterdam CT Score.

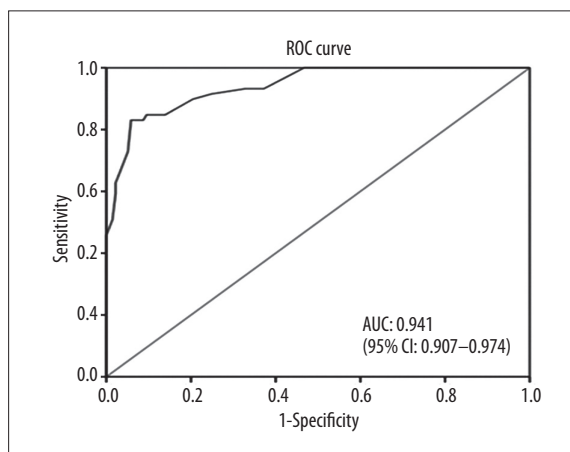
midline shift, epidural hematoma, subdural hematoma or subarachnoid haemorrhage evaluated in isolation did not show significant statistical correlation.

## Discussion

To date, both the Rotterdam CT score and ONSD have been evaluated as independent predictors of outcome among patients with traumatic brain injury. Worsening Rotterdam CT scores as well as elevated ONSD were identified as independent predictors of poor outcome. To the best of our knowledge, no study performed to date attempted to correlate ONSD and Rotterdam CT scores. This is a pioneer study regarding the correlation of RCTS vs. ONSD. In this cohort of patients, non-critical Rotterdam Score corresponded to normal ONSD. Worsening Rotterdam scores were consistent with an incremental increase in ONSD. The higher the ONSD, greater is the severity of traumatic brain injury, ONSD >5.8 mm being indicative of critical TBI.

The breakthrough IMPACT trial has established the CT characteristics on admission as some of the most powerful independent prognostic factors for prediction of unfavourable outcomes at six months from TBI [15]. Subsequent analysis by Maas et al. highlighted the pitfalls of Marshall Classification and re-introduced a new CT-based scoring system i.e., Rotterdam CT Scoring [19]. RCTS, which is expressed in numerical values from one to six, has also been evaluated as a potential radiological tool for predicting outcome and validated in several recent studies [16,17].

Optic nerve sheath diameter (ONSD) measured using ultrasound was used in critical care units to estimate the fluctuations in ICP and its usefulness was validated in several studies, including a meta-analysis [12]. Karakitsos et al. looked at ocular sonography in patients with severe head injury with documented Glasgow Coma Scale score <8 [19]. According to this study, an ONSD greater than 5 mm indicated 96% probability of raised ICP, while the probability was only 9% if the diameter was less than 5 mm. ONSD of 5.8 mm is the cut-off value for ICP greater than 20 mmHg and is characterized by a 90% probability of correct diagnosis. Several studies have validated ONSD as an independent predictor of morbidity and mortality in TBI [18].



**Figure 3.** ROC analysis for critical Rotterdam Score demonstrates its relationship with Optic Nerve Sheath diameter. Areas under curve are given in the bottom right corner. Diagonal segments are produced by ties.

ONSD measured on thin slice brain CT scan is more objective and reproducible compared to sonographic ONSD. Simultaneous measurements of ONSD on CT and ICP were strongly correlated; ONSD was discriminative for intracranial hypertension. ONSD was characterized by greater predictive value for ICP than other CT features. With a cut off value of 6.0 mm, ONSD demonstrated sensitivity of 97%, specificity of 42%, positive predictive value of 67%, and a negative predictive value of 92% [19,21].

Waqas et al. [20] analysed the Rotterdam CT scores and ONSD as predictors of outcome in patients requiring decompressive craniectomy. Area under the curve (AUC) for bilateral mean ONSD as a predictor of mortality was not significantly different between survivors and non-survivors. RCTS was a significant predictor of 30-day mortality; thus, they inferred that high values of admission ONSD do not predict mortality or unfavourable outcomes in decompressive craniectomy patients, as opposed to RCTS.

Disadvantages of using CT imaging include lack of real-time measurements and difficulty obtaining repeated measurements, both in terms of logistics, radiation exposure and cost. This study, to the best of our knowledge, is the first paper that incorporates ONSD as a measurement tool in association with RCTS. We propose that ONSD should be documented in the admission CT report, to allow sequential ONSD monitoring using ultrasound in order to assess changes in ICP from the baseline. This implies that a sequential increase in ONSD, which is indicative of eICP, is also suggestive of increased RCT score, warranting a repeated CT examination.

However, our study does not challenge invasive ICP monitoring as the standard of care in hospitals where it is available and routinely performed. The method in question has higher clinical relevance in developing countries, where ICP monitors are either not available, or too expensive to be used routinely. No other study has explored the possible correlation of ONSD and RCTS and given the absence of literature data, it is difficult to compare our results.

There are, however, several limitations to our study. The data were collected retrospectively and could have been corroborated on patients who underwent sequential CT's with rising RCT scores. No correlation was performed with neurological outcomes. No comparison to a control group for estimation of normal ONSD was performed. Since all measurements were performed by the same co-investigator, the inter- and intra-observer variability of the method could not be assessed. Despite these limitations, we believe that the study provides useful information and sets the precedence for more studies pertaining to this in correlation to outcomes, i.e. documenting ONSD in patients undergoing sequential CT scans as part of imaging protocol in traumatic brain injury.

## Conclusions

In conclusion, this study documents sequential increase in ONSD with an increase in Rotterdam CT score and is

indicative of elevated intracranial pressure. Thus, ONSD measured on CT can be translated into sequential sonographic ONSD, particularly in patients with mild TBI who are under observation, to determine the timing of sequential CT imaging and limit radiation exposure. ONSD can be used as a triage tool in high prevalence or low prevalence populations; in the former ONSD is an excellent tool to rule in the diagnosis of raised ICP, while in low prevalence population it rules out elevated ICP.

## Disclosure of interest

The authors declare that they have no conflicts of interest.

## Acknowledgements

Department of Neurosurgery, JSS Medical College and Hospital.

## References:

- Samabasivan M: Epidemiology of neurotrauma. *Neurology and prevention*. *Neurol India (Supl)*, 1991; 43: 9–15
- World Health Organization. *Projections of Mortality and Burden of Disease to 2030: Death by Income group*. 12/01/06, Geneva, 2002
- Gururaj G: Epidemiology of traumatic brain injuries: Indian scenario. *Neurol Res*, 2002; 24: 24–26
- Becker D, Miller J, Ward J: The outcome from severe head injury with early diagnosis and intensive management. *J Neurosurg*, 1977; 47: 491–502
- Miller MT, Pasquale M, Kurek S: Initial head computed tomographic scan characteristics have a linear relationship with initial intracranial pressure after trauma. *J Trauma*, 2004; 56: 967–72
- Hukkelhoven CW, Steyerberg EW, Habbema JD et al: Predicting outcome after traumatic brain injury: Development and validation of a prognostic score based on admission characteristics. *J Neurotrauma*, 2005; 22: 1025–39
- Marshall LF, Marshall SB, Klauber MR et al: A new classification of head injury based on computerized tomography. *Spec Suppl*, 1991; 75: S14–20
- Huang YH, Deng YH, Lee TC, Chen WF: Rotterdam computed tomography score as a prognosticator in head-injured patients undergoing decompressive craniectomy. *Neurosurgery*, 2012; 71: 80–85
- Hansen HC, Helmke K: The subarachnoid space surrounding the optic nerves: An ultrasound study of the optic nerve sheath. *Surg Radiol Anat*, 1996; 18: 323–28
- Hansen HC, Helmke K, Kunze K: Optic nerve sheath enlargement in acute intracranial hypertension. *Neuro-Ophthalmology*, 1994; 14: 345–54
- Tayal VS, Neulander M, Norton HJ et al: Emergency department sonographic measurement of optic nerve sheath diameter to detect findings of increased intracranial pressure in adult head injury patients. *Ann Emerg Med*, 2007; 49: 508–14
- Dubourg J, Javouhey E, Geeraerts T et al: Ultrasonography of optic nerve sheath diameter for detection of raised intracranial pressure: A systematic review and meta-analysis. *Intensive Care Med*, 2011; 37: 1059–68
- Goel RS, Goyal NK, Dharap SB et al: Utility of optic nerve ultrasonography in head injury. *Injury*, 2008; 39: 519–24
- Legrand A, Jeanjean P, Delanghe F et al: Estimation of optic nerve sheath diameter on an initial brain computed tomography scan can contribute prognostic information in traumatic brain injury patients. *Crit Care*, 2013; 17: R61
- Rajajee V, Vanaman M, Fletcher JJ, Jacobs TL: Optic nerve ultrasound for the detection of raised intracranial pressure. *Neurocrit Care*, 2011; 15: 506–15
- Murray GD, Butcher I, McHugh GS et al: Multivariable prognostic analysis in traumatic brain injury: results from the IMPACT study. *J Neurotrauma*, 2007; 24: 329–37
- Maas AI, Steyerberg EW, Butcher I et al: Prognostic value of computerized tomography scan characteristics in traumatic brain injury: results from the IMPACT study. *J Neurotrauma*, 2007; 24: 303–14
- Karakitsos D, Soldatos T, Gouliamos A et al: Transorbital sonographic monitoring of optic nerve diameter in patients with severe brain injury. *Transplant Proc*, 2006; 38: 3700–6
- Maas AI, Hukkelhoven CW, Marshall LF, Steyerberg EW: Prediction of outcome in traumatic brain injury with computed tomographic characteristics: A comparison between the computed tomographic classification and combinations of computed tomographic predictors. *Neurosurgery*, 2005; 57: 1173–82
- Waqasa M, Bakhshia SK, Shamima MS et al: Radiological prognostication in patients with head trauma requiring decompressive craniectomy: Analysis of optic nerve sheath diameter and Rotterdam CT Scoring System. *J Neuroradiol*, 2016; 43: 25–30
- Sekhona MS, Griesdale DE, Robba C et al: Optic nerve sheath diameter on computed tomography is correlated with simultaneously measured intracranial pressure in patients with severe traumatic brain injury. *Intensive Care Med*, 2014; 40(9): 1267–74