

Chapter 9

Therapeutic Strategies for DLI: How Should DLI Be Treated?

Sakae Homma

Abstract The lungs are vulnerable to toxins because of their large surface area and act as a metabolic site for some substances. Drugs may induce specific respiratory reactions, or the lungs may be affected as part of a generalized response. Drug-induced lung injury (DLI) can involve the airways, lung parenchyma, mediastinum, pleura, pulmonary vasculature, and/or the neuromuscular system. The most common form of DLI is drug-induced interstitial lung disease. There are no disease types specific to DLI, and DLIs are diagnosed on the basis of clinical findings, chest CT images, and histopathologic findings. The first principle of management of DLI is early detection and cessation of treatment with the suspected drug. Response to corticosteroid therapy depends on the histopathologic pattern of drug-induced interstitial lung disease. Prognosis depends on the specific drug and underlying clinical, physiologic, and pathologic severity of lung disease. To minimize DLI morbidity and mortality, all health-care providers should be familiar with the possible adverse effects of medications they prescribe. Individual variability in drug response is an important concern in clinical practice and drug development. Such variability is multifactorial and includes extrinsic factors such as environmental features and genetic and intrinsic factors that affect the pharmacokinetics and pharmacodynamics of drugs.

Keywords Therapeutic strategy • Drug-induced lung injury (DLI) • Drug-induced interstitial lung disease (DILD) • Treatment

S. Homma

Department of Respiratory Medicine, Toho University Omori Medical Center,
6-11-1 Omori-Nishi, Ota-ku, Tokyo 143-8541, Japan
e-mail: sahomma@med.toho-u.ac.jp

9.1 Introduction

The number of drugs that cause lung disease will continue to increase with the development of new agents, such as biologics and immune checkpoint inhibitors [1–4]. Drug-induced lung injuries (DLIs) can affect the airways, lung parenchyma, mediastinum, pleura, pulmonary vasculature, and/or neuromuscular system. The most common form of DLI is drug-induced interstitial lung disease (DILD). Orally and parenterally administered drugs are the most frequent causes of DLI; however, nebulized and intrathecal agents have also been implicated. DLI may result from a direct or indirect drug effect; direct effects may be idiosyncratic or caused by a toxic reaction to the drug or one of its metabolites.

Diagnosis of DLI is difficult because the clinical, radiologic, and histologic findings are nonspecific. The connection with drug use and the development of related inflammatory damage or idiosyncratic toxicities is hard to recognize and quantify, especially in patients using multiple drugs [5].

9.2 Disease Types and Characteristics

There are no disease types specific to DLIs, and DLIs are diagnosed on the basis of clinical features, chest computed tomography (CT) images, and histopathologic findings. The pulmonary lesions, disease types, and corresponding histopathologic findings of DLIs are shown in Table 9.1 [6].

9.2.1 *DLI Disease Types and Major Causative Drugs*

Representative drugs reported to cause DLIs are listed in Table 9.2 [7].

9.2.1.1 DILD

DILD must be differentiated from diffuse lung diseases, including idiopathic interstitial pneumonias (IIPs), interstitial pneumonia associated with connective tissue disease, acute and chronic hypersensitivity pneumonia (HP), eosinophilic pneumonia (EP), acute lung injury (ALI)/acute respiratory distress syndrome, and *Pneumocystis jiroveci* pneumonia (PCP). However, it is particularly difficult to determine whether a new shadow detected in a diagnostic image of the lungs is attributable to primary disease or a drug.

Drugs reported to induce diffuse alveolar disease (DAD), organizing pneumonia (OP), nonspecific interstitial pneumonia (NSIP), and HP include amiodarone, cyclophosphamide (CPA), gefitinib, erlotinib, cetuximab, panitumumab, methotrexate

Table 9.1 Pulmonary lesions, disease types, and histopathological findings of DLIs [6]

Pulmonary lesions	Disease types	Histopathological findings
1. Alveolar and interstitial lesions	Acute respiratory distress syndrome/ acute lung injury (ARDS/ALI)	Diffuse alveolar damage (DAD) (clinically severe)
	Acute interstitial pneumonia (AIP)	Diffuse alveolar damage (DAD) (clinically severe)
	Idiopathic pulmonary fibrosis (IPF)	Usual interstitial pneumonia (UIP)
	Nonspecific interstitial pneumonia (NSIP)	Nonspecific interstitial pneumonia (NSIP)
	Desquamative interstitial pneumonia (DIP)	Desquamative interstitial pneumonia (DIP)
	Cryptogenic organizing pneumonia (COP)	Organizing pneumonia (OP)
	Lymphocytic interstitial pneumonia (LIP)	Lymphocytic interstitial pneumonia (LIP)
	Eosinophilic pneumonia (EP)	Eosinophilic pneumonia (EP)
	Hypersensitivity pneumonia (HP)	Hypersensitivity pneumonia (HP)
	Granulomatous interstitial lung diseases	Granulomatous interstitial pneumonia
	Pulmonary edema	Pulmonary edema
	Capillary leak syndrome	Pulmonary edema
	Pulmonary alveolar proteinosis	Alveolar proteinosis
Diffuse alveolar hemorrhage	Alveolar hemorrhage	
2. Airway	Bronchial asthma	Bronchial asthma
	Bronchiolitis obliterans syndrome (BOS)	Constrictive bronchiolitis obliterans (CBO)
3. Blood vessels	Vasculitis	Vasculitis
	Pulmonary hypertension	Pulmonary hypertension
	Pulmonary veno-occlusive disease	Pulmonary veno-occlusive disease
4. Pleura	Pleuritis	Pleuritis

(MTX), bleomycin (BLM), gold drugs, salazosulfapyridine (SASP), penicillamine, hydralazine, beta-blockers, azathioprine, busulfan, procarbazine, and nitrofurantoin, among others.

9.2.1.2 Eosinophilic Pneumonia (EP)

Drug-induced EP is a collective term for diseases with respiratory manifestations—including dyspnea—that develop as a consequence of lung tissue damage caused by eosinophilic infiltration during drug treatment. Drugs that have been reported to induce EP include loxoprofen, acetylsalicylic acid, acetaminophen, MTX, penicillins, levofloxacin, phenytoin, imipramine, hydralazine, amiodarone, *shosaikoto*, and others [8, 9].

Table 9.2 Pulmonary lesions and causative drugs of DLIs [7]

Pattern of DLIs	Causative drugs
Diffuse alveolar damage (DAD)	Amiodarone, cyclophosphamide (CPA), gefitinib, erlotinib, cetuximab, panitumumab, methotrexate (MTX), and others
Organizing pneumonia (OP)	Bleomycin (BLM), MTX, CPA, gold drugs, amiodarone, salazosulfapyridine (SASP), penicillamine, and others
Nonspecific interstitial pneumonia (NSIP)	Amiodarone, MTX, penicillamine, gold drugs, hydralazine, and others
Hypersensitivity pneumonia (HP)	Beta-blockers, azathioprine, busulfan, procarbazine, nitrofurantoin, and others
Eosinophilic pneumonia (EP)	Loxoprofen, acetylsalicylic acid, acetaminophen, MTX, penicillins, levofloxacin, phenytoin, imipramine, hydralazine, amiodarone, shosaikoto, and others
Pulmonary edema (NCPE)	Cytarabine arabinoside (Ara-C), gemcitabine (GEM), MTX, amphotericin B (AMPH-B), acetazolamide, aspirin, morphine, and others
Bronchial asthma	Beta-blockers, NSAIDs, aspirin, and others
Bronchiolitis obliterans	Penicillamine, ampicillin, salazosulfapyridine, sauropus androgynus, and others
Pulmonary thromboembolism	Estrogen preparations, contraceptives, olanzapine, risperidone, and others
Alveolar hemorrhage	Heparin sodium, rivaroxaban, dabigatran etexilate, aspirin, clopidogrel sulfate, propylthiouracil, and others
Pulmonary hypertension	Aminorex, cocaine, methamphetamine, and others
Pleuritis	Amiodarone, procarbazine, methotrexate, infliximab, and others

9.2.1.3 Pulmonary Edema

Drug-induced pulmonary edema is typically non-cardiogenic pulmonary edema (NCPE). However, if the causative drug has a direct effect on the cardiovascular system that leads to decreased left ventricular function, the pathology is similar to cardiogenic pulmonary edema. Drugs reported to induce NCPE include cytarabine arabinoside (Ara-C), gemcitabine (GEM), MTX, amphotericin B (AMPH-B), acetazolamide, aspirin, morphine, and others [10, 11].

9.2.1.4 Airway Lesions

Drug-induced asthma or bronchospasm is broadly divided into three disease types, according to the causative agent, as follows: disease induced by beta-blockers; disease induced by nonsteroidal anti-inflammatory drugs, as in aspirin-induced asthma; and disease induced by inhalation of powdery substances, as in occupational asthma [7]. Bronchiolitis obliterans is induced by penicillamine, ampicillin, salazosulfapyridine, and *Sauropus androgynus*, among other drugs [12–14].

9.2.1.5 Pulmonary Vessel Lesions

Pulmonary Thromboembolism

Because estrogen preparations and oral contraceptives promote blood coagulation, their use is considered a risk factor for pulmonary thromboembolism. Numerous studies have reported that the use of psychotropic drugs to treat psychiatric disorders, including schizophrenia, was associated with pulmonary thromboembolism development [15].

Alveolar Hemorrhage

Drug-induced alveolar hemorrhage occasionally occurs during the use of antithrombotic drugs, such as anticoagulant, antiplatelet, and thrombolytic drugs, or as a complication of vasculitis related to antineutrophil cytoplasmic antibodies, which are typically present in patients treated with antithyroid drugs [16].

Drugs reported to induce alveolar hemorrhage include heparin sodium, rivaroxaban, dabigatran etexilate, aspirin, clopidogrel sulfate, and propylthiouracil, and others.

Pulmonary Hypertension (PH)

Drug-induced PH is reported to account for approximately 10% of all PAH cases and is induced by aminorex, cocaine, and methamphetamine, among other drugs [17].

9.2.1.6 Pleural Lesions

Drug-induced pleural lesions are rare. To date, over 40 drugs have been reported to induce pleural lesions, including amiodarone, procarbazine, methotrexate, infliximab, etanercept, and others [18, 19].

9.3 Current Status of and Response to DLI Treatment

9.3.1 *Current Status of Treatment*

The first principle of management for DLIs is early detection and cessation of treatment with the suspected drug. The primary goal of treatment is suppression of the inflammatory response and prevention of lung fibrosis.

Table 9.3 Disease severity and treatment strategy for DLIs [6]

Degree of severity	PaO ₂ (room air)	Treatment strategy
Mild	≥80 Torr	Discontinuation of the suspected drug
Moderate	60 to <80 Torr	Discontinuation of the suspected drug Corticosteroid therapy
Severe	<60 Torr (PaO ₂ / FiO ₂ < 300)	Discontinuation of the suspected drug. mPSL pulse therapy for 3 days and then continuous corticosteroid therapy

Acute episodes of DLIs usually resolve within 24–48 h after drug discontinuation, but chronic syndromes take longer. Because hypoxemia is common in DLIs, supplemental oxygen therapy is often provided. If a cytotoxic DLI is severe or appears to progress despite drug discontinuation, empirical administration of corticosteroids is advisable.

If continued treatment is necessary, the suspected drug should be replaced by a drug that is less likely to induce DLIs. Antineoplastic drugs therapy, however, should not be resumed until the injury has resolved. Recent evidence indicates that treatment approaches for everolimus- or temsirolimus-induced interstitial pulmonary disease and immune-related adverse events should be based on disease severity (Table 9.3) or grade (Table 9.4).

Patients with a moderate DLI should be treated with corticosteroids at a dose equivalent to 0.5–1.0 mg/kg/day of prednisolone (PSL), depending on the suspected drug and condition of the patient, in addition to discontinuation of the suspected drug. Treatment at the initial dose should be continued for 2–4 weeks and then gradually tapered. Patients with a severe DLI should be treated with methylprednisolone (mPSL) pulse therapy consisting of an mPSL dose equivalent of 500–1000 mg/day for 3 days, followed by treatment with corticosteroids at a dose equivalent to 0.5–1.0 mg/kg/day of PSL for 2–4 weeks, which is then tapered. If lung injury and hypoxemia resolve immediately, corticosteroid therapy can be ceased after 1–2 months (Fig. 9.1).

Recent research on the side effects of the immune checkpoint inhibitor nivolumab showed that DILD was less frequent in patients with melanoma (approximately 2–5%) than in those with renal cancer or non-small cell lung cancer (NSCLC) (approximately 5%). Treatment-related deaths from DILD have been reported, and the frequencies of such deaths were similar in melanoma and NSCLC patients receiving pembrolizumab. Ipilimumab monotherapy results in pneumonitis in up to 5% of patients, although the percentages of patients with dyspnea and cough are higher. Combination administration of ipilimumab and nivolumab is associated with the highest rate of ILD (5–10% for any grade and 2% for grade 3/grade 4) [4, 20–26].

Observation and continued treatment with the suspected drug are acceptable for patients with asymptomatic DILD; however, development of symptoms warrants interruption of immune checkpoint delivery and initiation of corticosteroid treatment (Table 9.4).

Table 9.4 Management of DILD caused by immune checkpoint inhibitors [4]

Grade 1 (mild)	Grade 2 (moderate)	Grade 3 (severe)	Grade 4 (life threatening)
<p>Asymptomatic; clinical or diagnostic observations; no intervention needed: delay drug administration.</p> <p>Consider steroids (e.g., prednisone 1 mg/kg/day PO or methylprednisolone 1 mg/kg/day IV).</p> <p>Follow-up: reassess management after 3 weeks—if completely resolved or non-drug-related continue treatment. If worsens treat as grade 2 or grade 3/grade 4</p>	<p>Symptomatic; medical intervention indicated; limits instrumental ADLs: delay drug administration.</p> <p>Consider hospitalization, daily monitoring of symptoms. Steroids recommended (e.g., prednisone 1–2 mg/kg/day PO or methylprednisolone 1–2 mg/kg/day IV).</p> <p>Consider empiric antibiotics (if suspicious for concurrent infections).</p> <p>Follow-up: reassess management every 1–3 days. If improving, taper steroids and continue treatment if symptoms resolve completely. If it worsens treat as grade 3/grade 4</p>	<p>Severe symptoms; limits self-care ADLs; oxygen indicated: discontinue drug administration. Hospitalization.</p> <p>High-dose steroids with methylprednisolone (e.g., 1 g/day IV). Add prophylactic antibiotics for opportunistic infections. Consider bronchoscopy with biopsy. Reassess management daily. If not improving after 48 h or worsening, administer additional immunosuppressive therapy (e.g., infliximab, mycophenolate, immunoglobulins). If improving, taper steroids. Discontinue treatment permanently</p>	<p>Life-threatening respiratory compromise; urgent intervention indicated (e.g., intubation): as per grade 3. Intensive care support required</p>

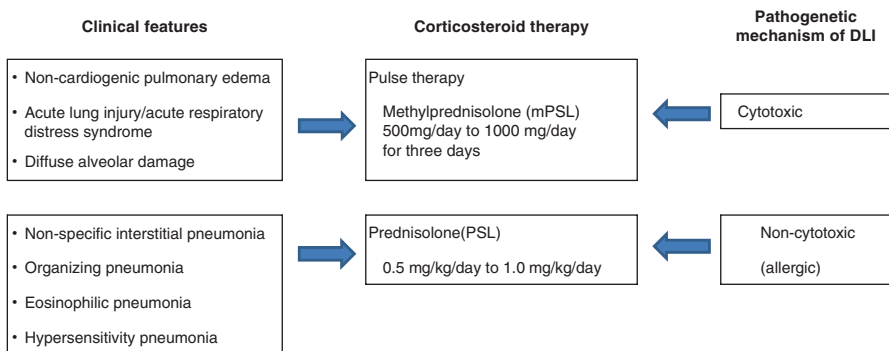


Fig. 9.1 Treatment strategy for DLIs [6]

9.3.2 Responses to Treatment

The response to corticosteroid therapy depends on the histopathologic pattern of DILD. Histopathologic changes for most drug reactions are nonspecific, but some drugs (e.g., amiodarone) have a characteristic histopathologic pattern of involvement that enables almost instant recognition of the causative agent. Methotrexate, for example, causes acute granulomatous DILD, which mimics an opportunistic infection [27].

Drugs can produce nearly all histopathologic patterns of interstitial pneumonia, including HP, OP, DAD, nonspecific interstitial pneumonia (NSIP), EP, pulmonary hemorrhage, and granulomatous pneumonitis. Most drugs in a comparable class induce a similar pattern of pulmonary involvement, which suggests a common cytopathic mechanism. However, some drugs produce more than one pattern of histopathologic involvement in the same patient. These reactions may be acute, subacute, or chronic (Table 9.2).

DLIs caused by allergic reactions and EP, HP, cellular NSIP, and OP associated with DILD generally respond to corticosteroids. However, DAD caused by cytotoxic mechanisms may not respond to corticosteroids. With respect to histopathologic findings, the following types of DLI cases will likely respond to corticosteroids: (1) cases in which histopathologic findings indicate inflammation characterized by lymphocyte infiltration or development of granulomatous lesions with no, or very limited, tissue damage or fibrosis and (2) cases in which histopathologic findings suggest EP or organic changes in alveoli. However, cases of DAD and those involving advanced fibrosis are unlikely to respond to corticosteroids.

Patients with OP, EP, or HP and normal serum KL-6 levels respond to corticosteroids; thus, those with DLIs and normal KL-6 levels are also likely to respond to corticosteroids, as long as the injury corresponds to any of the OP or HP clinical disease types for DLIs [28].

Treatment planning must carefully consider the severity of DLI and the morbidity associated with failure to treat the underlying disease. Alternative agents, if available, should be used. Because many patients with DILD are treated with immunosuppressive medications, which modestly increase the risk of infection, patients with DILD should receive the pneumococcal vaccine and yearly influenza virus vaccine. Furthermore, the incidence of tuberculosis is highly associated with antitumor necrosis factor monoclonal antibody therapy. The increased risk associated with early antitumor necrosis factor treatment and lack of an optimal chemopreventive treatment favor reactivation of latent tuberculosis.

9.4 Prognosis

Prognosis is favorable when acute DLIs are diagnosed early, and complete recovery can be expected in such cases. However, undiagnosed DLIs are associated with substantial morbidity and mortality. Prognosis depends on the specific drug and underlying clinical, physiologic, and pathologic severity of lung disease. Typical

complications of DLIs are pulmonary fibrosis and respiratory failure requiring mechanical ventilation. Unfortunately, if the initial injury or abnormal repair of injury is not stopped, progressive tissue damage can lead to worsening physiologic impairment and even death.

The prognosis for DILD varies in relation to the frequency of the DAD pattern. Thus, it is important to determine whether the presenting DILD has a DAD pattern. Histopathologic examination is required for diagnosis. However, patients often present in serious condition, when it is difficult to perform a lung biopsy. In such cases, high-resolution CT is helpful in determining the DILD pattern. In general, the suspected drug should be immediately discontinued and re-administration avoided.

9.5 Conclusions

DLIs can involve the airways, lung parenchyma, mediastinum, pleura, pulmonary vasculature, and/or the neuromuscular system. The first principle of management of DLIs is early detection and cessation of treatment with the suspected drug. Response to corticosteroid therapy depends on the histopathologic pattern of DILD. Prognosis depends on the specific drug and underlying clinical, physiologic, and pathologic severity of lung disease. In addition, the clinical and radiographic features of DILD are often difficult to distinguish from those of other causes of DILD (e.g., infections, lung involvement of an underlying disease, pulmonary edema, connective tissue disease), and no signs, symptoms, or laboratory or radiologic findings are considered pathognomonic. Therefore, it is essential for physicians to be familiar with iatrogenic diseases that may affect their patients. In addition, clinical and genetic risk stratification may improve prevention of DILD in the future.

References

1. Koike T, Harigai M, Inokuma S, Ishiguro N, Ryu J, Takeuchi T, et al. Postmarketing surveillance of tocilizumab for rheumatoid arthritis in Japan: interim analysis of 3881 patients. *Ann Rheum Dis.* 2011;70:2148–51.
2. Koike T, Harigai M, Inokuma S, Inoue K, Ishiguro N, Ryu J, et al. Postmarketing surveillance of the safety and effectiveness of etanercept in Japan. *J Rheumatol.* 2009;36:898–906.
3. Takeuchi T, Tatsuki Y, Nogami Y, Ishiguro N, Tanaka Y, Yamanaka H, et al. Postmarketing surveillance of the safety profile of infliximab in 5000 Japanese patients with rheumatoid arthritis. *Ann Rheum Dis.* 2008;67:189–94.
4. Naidoo J, Wang X, Woo KM, Iyriboz T, Halpenny D, Cunningham J, et al. Pneumonitis in patients treated with anti-programmed death-1/programmed death ligand 1 therapy. *J Clin Oncol.* 2016;34:JCO682005. doi:10.1200/JCO.2016.68.2005.
5. Nemery B, Bast A, Behr J, Bormz PJA, Bourke SJ, Camus P, et al. Interstitial lung disease induced by exogenous agents: factors governing susceptibility. *Eur Respir J.* 2001;18(Suppl 32):30s–42s.

6. Kubo K, Azuma A, Kanazawa M, Kameda H, Kusumoto M, The Japanese Respiratory Society Committee for formulation of Consensus statement for the diagnosis and treatment of drug-induced lung injuries. Guideline and Statement Consensus statement for the diagnosis and treatment of drug-induced lung injuries. *Respir Invest*. 2013;51:260–77.
7. A consensus statement first published as Consensus statement for the diagnosis and treatment of drug-induced lung injuries by the Japanese Respiratory Society in Japanese, 1st ed. Tokyo: Medical Review; 2012.
8. Camus P, Fanton A, Bonniaud P, et al. Interstitial lung disease induced by drugs and radiation. *Respiration*. 2004;71:301–26.
9. Solomon J, Schwarz M. Drug-, toxin-, and radiation therapy induced eosinophilic pneumonia. *Semin Respir Crit Care Med*. 2006;27:192–7.
10. Briasoulis E, Pavilidis N. Noncardiogenic pulmonary edema: an unusual and serious complication of anticancer therapy. *Oncologist*. 2001;6:153–61.
11. Lee-Chiong T Jr, Matthay RA. Drug-induced pulmonary edema and acute respiratory distress syndrome. *Clin Chest Med*. 2004;25:95–104.
12. Sugino K, Hebisawa A, Uekusa T, Hatanaka K, Abe H, Homma S. Bronchiolitis obliterans associated with Stevens-Johnson Syndrome: histopathological bronchial reconstruction of the whole lung and immunohistochemical study. *Diagn Pathol*. 2013;8:134–40.
13. Lai RS, Chiang AA, MT W, Wang JS, Lai NS, JY L, et al. Outbreak of bronchiolitis obliterans associated with consumption of *Sauropus androgynus* in Taiwan. *Lancet*. 1996;348:83–5.
14. Onakahara K, Higashimoto I, Arimura K, et al. Clinical characteristics of drug-induced lung diseases, including bronchiolitis obliterans associated with consumption of *Sauropus androgynus*. *Kokyu*. 2004;23:540–5. (Japanese)
15. Liperoti R, Pedone C, Lapane KL, et al. Venous thromboembolism among elderly patients treated with atypical and conventional antipsychotic agents. *Arch Intern Med*. 2005;165:2677–2.
16. Nakayama M, Bando M, Kobayashi A, Hosono T, Tshuita A, Yamasawa H, et al. Case of myeloperoxidase-antineutrophil cytoplasmic antibody-associated pulmonary alveolar hemorrhage caused by propylthiouracil. *Nihon Kokyuki Gakkai Zasshi*. 2007;45:508–13. (Japanese)
17. Simonneau G, Robbins IM, Beghetti M, et al. Updated clinical classification of pulmonary hypertension. *J Am Coll Cardiol*. 2009;54:S43–54.
18. Higgins JT, Sahn SA. Drug-induced pleural disease. *Clin Chest Med*. 2004;25:141–53.
19. Katz U, Zandman-Goddard G. Drug-induced lupus: an update. *Autoimmune Rev*. 2010;10:46–50.
20. Weber JS, D'Angelo SP, Minor D, Hodi FS, Gutzmer R, Neyns B, et al. Nivolumab versus chemotherapy in patients with advanced melanoma who progressed after anti-CTLA-4 treatment (CheckMate 037): a randomised, controlled, openlabel, phase 3 trial. *Lancet Oncol*. 2015;16:375–84.
21. Larkin J, Chiarion-Sileni V, Gonzalez R, Grob JJ, Cowey CL, Lao CD, et al. Combined nivolumab and ipilimumab or monotherapy in untreated melanoma. *N Engl J Med*. 2015;373:23–34.
22. Rizvi NA, Mazieres J, Planchard D, Stinchcombe TE, Dy GK, Antonia SJ, et al. Activity and safety of nivolumab, an anti-PD-1 immune checkpoint inhibitor, for patients with advanced, refractory squamous non-small-cell lung cancer (CheckMate 063): a phase 2, single-arm trial. *Lancet Oncol*. 2015;16:257–65.
23. Gettinger SN, Horn L, Gandhi L, Spigel DR, Antonia SJ, Rizvi NA, et al. Overall survival and long-term safety of nivolumab (anti-programmed death 1 antibody, BMS-936558, ONO-4538) in patients with previously treated advanced non-small-cell lung cancer. *J Clin Oncol*. 2015;33:2004–12.
24. Herbst RS, Baas P, Kim DW, Felip E, Perez-Gracia JL, Han JY, et al. Pembrolizumab versus docetaxel for previously treated, PD-L1-positive, advanced non-small-cell lung cancer (KEYNOTE-010): a randomized controlled trial. *Lancet*. 2015;373:1627–39.

25. Borghaei H, Paz-Ares L, Horn L, Spigel DR, Steins M, Ready NE, et al. Nivolumab versus docetaxel in advanced nonsquamous non-small-cell lung cancer. *N Engl J Med*. 2015;373:1627–39.
26. Calabro L, Morra A, Fonsatti E, Cutaia O, Amato G, Giannarelli D, et al. Tremelimumab for patients with chemotherapy-resistant advanced malignant mesothelioma: an open-label, single-arm, phase 2 trial. *Lancet Oncol*. 2013;14(11):1104.
27. Schwaiblmair M, Behr W, Haeckel T, Markl B, Foerg W, Berghaus T. Drug induced interstitial lung disease. *Open Respir Med J*. 2012;6:63–74.
28. Ohnishi H, Yokoyama A, Yasuhara Y, Watanabe A, Naka T, Hamada H, et al. Circulating KL-6 levels in patients with drug induced pneumonitis. *Thorax*. 2003;58:872–5.