

Successful Secure High-definition Streaming Telecytology for Remote Cytologic Evaluation

Sahussapont Joseph Sirintrapun¹, Dorota Rudomina¹, Allix Mazzella¹, Rusmir Feratovic¹, Oscar Lin¹

¹Department of Pathology, Memorial Sloan Kettering Cancer Center, New York, USA

Received: 20 February 2017

Accepted: 04 July 2017

Published: 07 September 2017

Abstract

Background: The use of minimally invasive procedures to obtain material for diagnostic purposes has become more prevalent in recent years. As such, there is increased demand for immediate cytologic adequacy assessment of minimally invasive procedures. The array of different locations in which rapid on-site evaluation (ROSE) is expected requires an ever-increasing number of cytology personnel to provide support for adequacy assessment. In our study, we describe the implementation process of a telecytology (TC) system in a high case volume setting and evaluate the performance of this activity. **Methods:** We performed retrospectively an analysis of all consecutive remote TC ROSE evaluations obtained for 15 months. The specimens were evaluated using a TC system. The ROSE adequacy assessment obtained at the time of the procedure was compared to the final cytopathologist-rendered adequacy assessment when all the material was available for review, including the alcohol-fixed preparations. **Results:** A total of 8106 distinct cases were analyzed. TC-assisted preliminary adequacy assessment was highly concordant with the final cytopathologist-rendered adequacy assessment. Perfect concordance or accuracy was at 93.1% (7547/8106). The adequacy upgrade rate (inadequate specimen became adequate) was 6.8% (551/8106), and the initial adequacy downgrade (adequate specimen became inadequate) was <0.1% (8/8106). **Conclusions:** The TC outcome demonstrates high concordance between the initial adequacy assessment and final cytopathologist-rendered adequacy assessment. Adequacy upgrades were minor but, more importantly, our results demonstrate a minimal adequacy downgrade. The process implemented effectively eliminated the need for an attending pathologist to be physically present onsite during a biopsy procedure.

Keywords: Cytologic adequacy, live streaming, nonrobotic dynamic, rapid on-site adequacy evaluation, telecytology, telepathology

INTRODUCTION

The use of minimally invasive procedures to obtain material for diagnostic purposes has become more prevalent in recent years. This has increased demand for immediate cytologic adequacy assessment of fine-needle aspirations (FNAs) and touch imprints of core biopsies (CBs). The immediate cytologic adequacy assessment guides the person performing the procedure in deciding whether to stop or to obtain additional tissue. For instance with lung carcinomas, interventional radiologists are prompted through immediate cytologic adequacy assessment to perform additional passes for immunohistochemistry and molecular studies and/or obtain CBs. With lymphomas, immediate cytologic adequacy assessments are critical in determining sufficient tissue for flow cytometry and molecular studies in addition to obtaining CBs.

FNAs and CBs are often performed in different locations within a single institution. For instance, endobronchial ultrasound-guided (EBUS) biopsies are commonly performed in dedicated operating room suites whereas FNA biopsies of deep organs are typically done in radiology suites. These locations are not always located in adjacent areas and it is not uncommon that they are located in different buildings or even campuses. The array of different locations in which rapid on-site adequacy

Address for correspondence: Dr. Sahussapont Joseph Sirintrapun, Memorial Sloan Kettering Cancer Center, 1275 York Avenue A515, New York 10065, USA.
E-mail: sirintrs@mskcc.org

This is an open access article distributed under the terms of the Creative Commons Attribution-NonCommercial-ShareAlike 3.0 License, which allows others to remix, tweak, and build upon the work non-commercially, as long as the author is credited and the new creations are licensed under the identical terms.

For reprints contact: reprints@medknow.com

How to cite this article: Sirintrapun SJ, Rudomina D, Mazzella A, Feratovic R, Lin O. Successful secure high-definition streaming telecytology for remote cytologic evaluation. *J Pathol Inform* 2017;8:33.

Available FREE in open access from: <http://www.jpathinformatics.org/text.asp?2017/8/1/33/214163>

Access this article online

Quick Response Code:



Website:
www.jpathinformatics.org

DOI:
10.4103/jpi.jpi_18_17

evaluation (ROSE) is expected requires an ever-increasing number of cytology personnel to provide support for adequacy assessment.

The increased complexity of the cases biopsied and the need for immediate diagnostic feedback for clinical management and ancillary study triage, have led to the inclusion of a cytopathologist in this activity even though cytotechnologists (CTs) in many institutions can perform adequacy assessments independently with satisfactory results. Having cytopathologist involvement for ROSE provides the value-added benefit of triaging of specimens for the ancillary studies required to better manage patients. An operational evaluation of resources in our institution demonstrated that although CTs could be made available at each location for ROSE, it was not feasible or cost-effective to allocate a cytopathologist to each location that offered these procedures. The requirement for a cytopathologist to access microscopic images in real time without being physically present at the procedure site prompted the evaluation of telecytology (TC) as a solution.

As a new process, TC required identification of the proper equipment and validation studies as stressed by the American Telemedicine Association for any implementation of telepathology.^[1] In our study, we describe the implementation process of a TC system in a high case volume setting and evaluate the performance of this activity through analysis of the concordance rate between the ROSE result given at the time of the procedure and the final cytologic interpretation.

METHODS

We performed retrospectively an analysis of all consecutive remote TC ROSE evaluations obtained for 15 months after a period of validation with twenty cases by each individual involved in this activity. The specimens were evaluated for cellular content and diagnostic adequacy on FNAs and touch preparations of CBs using a telepathology system offered by the Remote Medical Technologies (RMT). Patient age and sex data were collected along with the number of cases at each facility in which adequacy assessment was provided. Cellular content and adequacy were determined based on clinical-radiological findings available at the time of the procedure. A determination of adequacy at the time of procedure means not only getting to a diagnosis of malignancy but also that sufficient tissue is available for diagnostic evaluation performed later to render the final cytologic interpretation. This diagnostic evaluation includes sufficient tissue availability to perform the necessary immunohistochemistry, molecular, and flow cytometric studies. A determination of adequacy at the time of procedure translates into a prompt halt to further procedural attempts in obtaining tissue.

Adequacy was recorded in paper form and the information was transferred to the final cytology report. No deferrals were issued and the specimens were either considered adequate or inadequate. Only adequacy assessments and not preliminary diagnoses are officially provided onsite. There are, however,

ongoing physician-to-physician discussions during the procedure potentially discussing unofficially hypothetical preliminary differentials.

The ROSE adequacy assessment obtained at the time of the procedure was then compared to the final cytopathologist-rendered adequacy assessment when all the material obtained during the procedure was available for review, including the alcohol-fixed preparations. Concordance was defined as correlation between the preliminary adequacy assessment and the final cytopathologist-rendered adequacy assessment (either adequate or inadequate). A perfect concordance would be when both the preliminary adequacy assessment and the final cytopathologist-rendered adequacy assessment are the same (either both adequate or both inadequate). Because adequacy determination at the time of procedure did not include officially preliminary diagnoses, concordance meant that the appropriate level of ancillary testing could be performed to enable a more definitive final cytologic interpretation.

An adequacy upgrade occurred when the preliminary adequacy assessment was considered inadequate but the final cytopathologist-rendered adequacy assessment was determined to be adequate. An adequacy downgrade occurs when preliminary adequacy assessment was deemed adequate, but the final cytopathologist-rendered adequacy assessment was determined to be inadequate.

Technical description

RMT is a secure dynamic streaming TC system used in this study. Figure 1a provides an overview of the RMT architecture, which is based on a spoke and hub-networked client-server concept. The focal point of this system is the scope center, which is comprised a Linux server. Termed a “multiprotocol appliance” (MPA), this server coordinates the broadcast of live images captured through high-definition (HD) video cameras. The system is coupled with either Optronics MICROCAST[®] HD 3CCD HD video cameras or Lumenera[®] HD cameras that generate video at 60 frames/s. The captured digital HD images are converted into signals that are eventually routed to the MPA through intermediary devices called “iServe-M-Encoders.” These intermediaries are directly connected to the HD cameras and communicate with the MPA securely through an Internet Protocol connection. 28” HD LED Samsung[™] U28D590D monitors or Apple iPad[®] tablets were used for remote viewing. The live image stream is broadcast at 1920 × 1080 and is contained behind the institutional firewall. Remote viewing is web browser-based; utilizing any browser with Adobe Flash capability. Our institutional intranet connection speeds at the time of the study were at 1 Gigabit per second. Figure 1b is a screenshot of the web browser-based viewer interface.

Our TC implementation includes both stationary systems and mobile cart systems. The mobile cart systems are customized builds mounted on standard audiovisual carts and comprise a mounted microscope and its own RMT system including “iServe-M-Encoder” and MPA server. One difference between the mobile cart systems and the stationary systems is the size

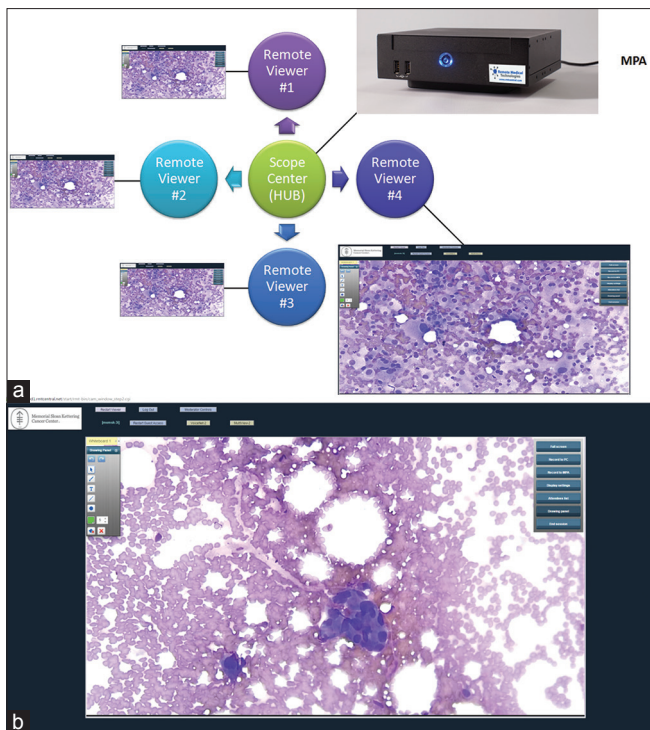


Figure 1: (a) An overview of the Remote Medical Technologies architecture, which is based on a spoke and hub-networked client-server concept. (b) A screenshot of the web-based interface in viewing a cytologic adequacy evaluation

of the monitor attached to the RMT system. Instead of a large monitor with the stationary systems, a 10-inch monitor is used on the mobile cart systems to review the images being transmitted. Furthermore, the mobile cart systems contain a backup battery to the RMT system; to avoid any damage to the equipment if the system is mistakenly disconnected.

Process workflow

The workflow employed for the implementation of TC was the following: the CT is informed when a biopsy procedure is about to begin and alerts the cytology attending, who proceeds to access the on-site camera through the web browser. The CT prepares slides onsite, all of which Diff-Quik stained, and also reviews the slides onsite at the time of the procedure. The CT selects the appropriate region(s) of interest then s/he notifies the attending cytopathologist based at the main hospital building that the specimen is ready for evaluation. The CT and cytopathologist communicate verbally and securely through a Vocera communications platform. ROSE is then performed using TC.

RESULTS

A total of 8106 distinct cases were analyzed with distribution of lesion locations illustrated in Figure 2. Lung, lymph nodes, and liver comprised the majority of lesion locations. With lung specimens, EBUS comprised 79.0% of the procedures. The mean patient age was 64 with a range of 3–98 years and there was a slight male predominance. Table 1 provides information on remote

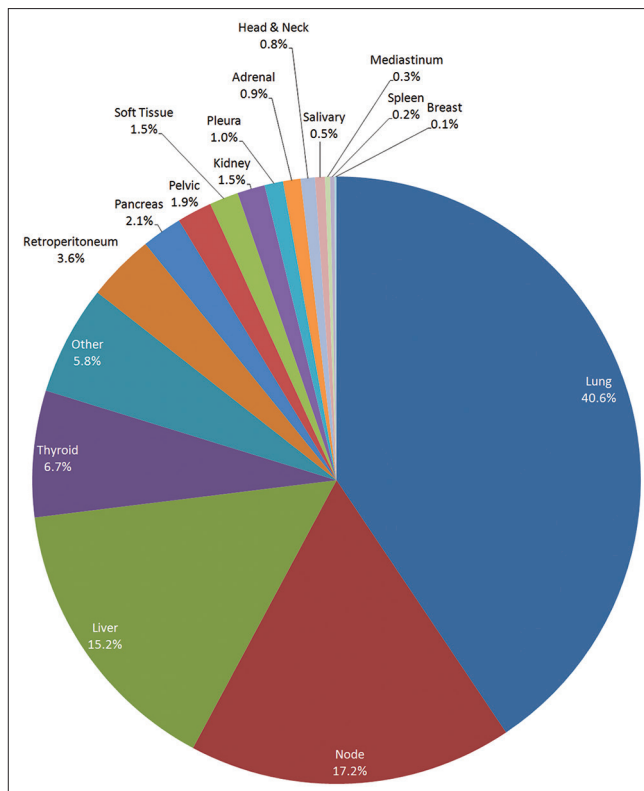


Figure 2: The distribution of lesion locations

Table 1: Information on remote location and cytologic evaluation

TC cases (n=8106)	Cytologic evaluation		Total (%)
	Touch preparation (%)	FNA (%)	
Remote locations			
Interventional radiology (2 locations)	61.3	18.4	79.7
Ultrasound suites (2 locations)	0.7	14.3	15.0
Endoscopy suites (1 location)	0.2	4.7	4.9
Operating rooms (1 location)	0	0.5	0.5
Total	62.2	37.8	

TC: Telecytology, FNA: Fine-needle aspiration

location and cytologic evaluation. The vast majority of procedures was performed in interventional radiology and ultrasound suites. Table 2 is a matrix comparing adequacy between the TC adequacy assessment and the final cytopathologist-rendered adequacy assessment. The adequacy upgrade rate (inadequate specimen became adequate) was 6.8% (551/8106), and the initial adequacy downgrade (adequate specimen became inadequate) was initially calculated as 0.3% (21/8106). A list of these cases is outlined in Supplementary Table 1.

A rereview however with knowledge of the subsequent radiological and histological findings demonstrated that the

Table 2: Matrix comparing adequacy between the telecytology adequacy assessment and the final evaluation

Comparison between the TC adequacy assessment and final assessment

TC adequacy assessment	Final assessment		Total
	Adequate	Inadequate	
Adequate	6731	8*	6739
Inadequate	551	816	1367
Total	7282	824	8106

*Downgraded cases (adequate initially on TC, inadequate on final assessment). TC: Telecytology

Table 3: Information on the cytologic evaluation and site of the 8 cases for which there was an adequacy downgrade

Cytologic evaluation	Site
Touch preparation	Liver
Touch preparation	Lung
Touch preparation	Peritoneum
Touch preparation	Soft tissue
FNA	Liver
FNA	Liver
FNA	Thyroid
FNA	Kidney

FNA: Fine-needle aspiration

downgrade rate was actually <0.1% (8/8106). Table 3 provides information on the cytologic evaluation and site of the eight cases for which actual adequacy downgrades happened due to misinterpretation. Our study shows that TC-assisted preliminary adequacy assessment was highly concordant with the final cytopathologist-rendered adequacy assessment. Perfect concordance or accuracy was at 93.1% (7547/8106).

DISCUSSION

Our study demonstrates the experience of large cancer center in the use of TC for ROSE and represents the largest evaluation of TC to date ($n = 8106$). As a comparison, other larger assessments of digitized scanned slides have a sample size of up to 600 cases.^[2] Effectiveness of our TC implementation was demonstrated through the diagnostic concordance analysis between the images seen through TC and final cytopathologist-rendered adequacy assessment when all material was available for evaluation. In our series, perfect concordance or accuracy was at 93.1%. This was comparable to our prior conventional physical on-site evaluation rates as well as previous reports, which have demonstrated an 80% to 95% concordance rate for TC and 66.7% to 97% for conventional on-site methods.^[3-8] The adequacy upgrade rate in which lesions initially designated as inadequate became adequate on the evaluation of the entire specimen was low (6.8%). These adequacy upgrades are not unexpected as not all diagnostic material may be available at the time of ROSE. Furthermore, most upgraded cases were represented by soft-tissue lesions or lesions associated with

marked fibrosis. Smears and touch preparations of such lesions frequently yield a very limited number of cells on adequacy assessment. Diagnostic cells only became appreciable when the biopsy was submitted to histologic evaluation.

Although the concordance rate was relatively high in this study, there was also a minimal initial adequacy downgrade rate in which lesions considered adequate at the time of ROSE were later deemed inadequate at the time of the final sign out. In the initial set of downgraded cases provided in Supplementary Table 1, many were actually vascular lesions, inflammatory lesions, or low-grade spindle lesions that had been misinterpreted by the cytopathologist issuing the final interpretation. A more in-depth review of these downgraded cases with knowledge of the subsequent clinical and/or histological findings showed that the actual downgrade was actually <0.1%.

An adequacy downgrade is considered a critical metric due to its clinical implications. A preliminary adequacy assessment that is incorrectly designated as adequate will lead to end the procedure without sampling of the lesion, resulting in either delay of diagnosis or need for a repeat procedure. The leading cause of downgraded cases listed in Table 3 is misinterpretation of benign cells as malignant cells. Examples of such cases include misinterpretation of reactive hepatocytes as carcinoma cells, renal tubular cells as neoplastic renal cortical cells, or cases in which clusters of lymphocytes were misinterpreted as thyroid follicular cells.

These concordance rates are important as threshold benchmarks for user competency are ill-defined in TC. A prior TC study proposed a benchmark interobserver/intraobserver passing rate of 90%,^[9] but sample size was limited with only ten cases used for validation.^[10] For whole images, it has been suggested that at least 60 cases be utilized for validation. In TC, where whole slide images scanning have not been widely used, there are no official recommendations for validation sample size.^[11] Nonetheless, a larger number of cases is optimal as it allows laboratory managers to better analyze the technology's functionality when case volume is high.^[2]

Several factors contributed to the relative high concordance rate in this study, including particularly CT diagnostic skills, TC equipment, and workflow. In regards to CT diagnostic skills, the CTs in our institution were familiar with the process as they provided independent adequacy assessment before introduction of TC in our institution. ROSE training for CTs in our institution involves shadowing an experienced CT for at least 3 months and encompasses graduated performance of ROSE under supervision. CTs in our institution would only start performing ROSE independently after being considered proficient in the task. As part of our QA process, CTs would review completed cases with the cytopathologists and address any issues that arise. Thus, with the ROSE training and experience, CTs at our institution are quite proficient at showing regions of interest.

The ability of the person onsite to show regions of interest is critical for this TC activity using this platform as the cytopathologist is not able to move the slide. In addition, the TC system and workflow implemented for this activity were important in this high-volume setting. During the planning period for this activity, it was established that the minimum requirements for the TC equipment would be user friendliness for both CTs and cytopathologists, secure remote access, and excellent image quality. An intuitive product was an imperative due to the varying levels of technological knowledge and comfort among our staff. After evaluating the different solutions available on the market, the selected TC equipment demonstrated to be the most effective option for a large-scale implementation. The images could be accessed inside the institution's firewall through any computer with an internet browser and required only the input of the user's identification, password, and remote location where the biopsy was to occur by the pathologist providing the adequacy assessment. The first two steps could be automated; therefore, access to the image required only two clicks by the pathologist if the browser was already open. The remote access to the on-site camera was critical to the workflow as it would enable CTs to share images with cytopathologists with minimal delays or effort from their part. CTs could then focus on screening the slide instead of spending time and effort facilitating the image-sharing process. Another advantage of the system is that the images can be seen on mobile devices such as tablets and smartphones, as long as they are inside the institution firewall. The cytopathologists are able to view the images on iPads and Microsoft Surface tablets with very low decrease in image quality (their monitors are not ultra-high definition) while away from their offices. Other solutions explored, including WebEx® system and digital scanners did not meet our requirements. The WebEx system entailed a number of manual steps for both system configuration and image access. Initiating a WebEx session included starting the TWAIN driver for the camera and logging into the on-site computer. The CTs would need to send an invitation by E-mail to the cytopathologist, who would then need to click the link provided to access the on-site monitor. This process can take at least 45–60 s, even for an expert-level user. On the other hand, with the system adopted in our workflow, the CTs spend no time initiating the image-sharing process and the cytopathologist also obtains access to the camera images within seconds. Digital slide scanning technology was investigated, however, the extended time required to scan and screen the slides prevented their adoption to our workflow.

Another advantage of the system adopted was the excellent image quality provided as it uses a high streaming resolution at 1920 × 1080 pixels. In comparison, WebEx streams at 1280 × 1024 pixels and MicroSuite5 software with NetCam feature (Olympus) streams at 800 × 600 pixels.^[12] Although Nikon and Olympus offer network image streaming applications as a component of their hardware, these products lack the built-in level of security and authentication mechanisms. Low-cost

or even free mobile applications such as Apple's FaceTime have also been described as TC options.^[13,14] The required level of security mandated by our institution made it difficult to use such applications. Voice conversations and streamed images are routed to outside proprietary servers without institutional oversight and control. Although solutions that share desktop screens with captured live images (i.e., TeamViewer and Skype) have proven effective in small-scale telepathology implementations,^[15] institutional regulatory issues, and high case volume prevented an effective use. Similar to FaceTime, such applications create outbound streams to proprietary servers outside the institutional firewall. Since the entire desktop screen is shared, open electronic patient records and captured live images introduce the risk of patient privacy exposure. On the other hand, RMT additive logins and authentication layered within our institutional firewall can effectively prevent external attacks and unauthorized sharing. The images cannot be seen by anyone outside our institutional firewall including RMT staff.

CONCLUSION

In summary, TC outcome measures in our institution demonstrate high concordance between the initial adequacy assessment and final cytopathologist-rendered adequacy assessment. Adequacy upgrades were minor but, more importantly, our results demonstrate a minimal adequacy downgrade. The skill level of the CTs in our institution and the technology employed enabled the scalability of the TC for rapid on-site adequacy assessment by allowing a seamless and effortless view of the images seen at the on-site microscope, effectively eliminating the need for an attending pathologist to be physically present onsite during a biopsy procedure.

Financial support and sponsorship

This study was financially supported by MSK Cancer Center Support Grant/Core Grant (P30 CA008748).

Conflicts of interest

There are no conflicts of interest.

REFERENCES

1. Pantanowitz L, Dickinson K, Evans AJ, Hassell LA, Henricks WH, Lennerz JK, *et al.* American Telemedicine Association clinical guidelines for telepathology. *J Pathol Inform.* 2014;5:39.
2. Li X, Gong E, McNutt MA, Liu J, Li F, Li T, *et al.* Assessment of diagnostic accuracy and feasibility of dynamic telepathology in China. *Hum Pathol* 2008;39:236-42.
3. Briscoe D, Adair CF, Thompson LD, Tellado MV, Buckner SB, Rosenthal DL, *et al.* Telecytologic diagnosis of breast fine needle aspiration biopsies. Intraobserver concordance. *Acta Cytol* 2000;44:175-80.
4. Cai G, Teot LA, Khalbuss WE, Yu J, Monaco SE, Jukic DM, *et al.* Cytologic evaluation of image-guided fine needle aspiration biopsies via robotic microscopy: A validation study. *J Pathol Inform* 2010;1.
5. Galvez J, Howell L, Costa MJ, Davis R. Diagnostic concordance of telecytology and conventional cytology for evaluating breast aspirates. *Acta Cytol* 1998;42:663-7.
6. Heimann A, Maini G, Hwang S, Shroyer KR, Singh M. Use of telecytology for the immediate assessment of CT guided and endoscopic FNA cytology: Diagnostic accuracy, advantages, and pitfalls. *Diagn*

- Cytopathol 2012;40:575-81.
7. Khurana KK, Rong R, Wang D, Roy A. Dynamic telecytopathology for on-site preliminary diagnosis of endoscopic ultrasound-guided fine needle aspiration of pancreatic masses. *J Telemed Telecare* 2012;18:253-9.
 8. Raab SS, Zaleski MS, Thomas PA, Niemann TH, Isacson C, Jensen CS, *et al.* Telecytology: Diagnostic accuracy in cervical-vaginal smears. *Am J Clin Pathol* 1996;105:599-603.
 9. McCarthy EE, McMahon RQ, Das K, Stewart J 3rd. Internal validation testing for new technologies: Bringing telecytopathology into the mainstream. *Diagn Cytopathol* 2015;43:3-7.
 10. Monaco SE, Pantanowitz L. Telecytology value and validation: Developing a validation and competency tool for telecytology. *Diagn Cytopathol* 2015;43:1-2.
 11. Pantanowitz L, Sinard JH, Henricks WH, Fatheree LA, Carter AB, Contis L, *et al.* Validating whole slide imaging for diagnostic purposes in pathology: Guideline from the College of American Pathologists Pathology and Laboratory Quality Center. *Arch Pathol Lab Med* 2013;137:1710-22.
 12. Buxbaum JL, Eloubeidi MA, Lane CJ, Varadarajulu S, Linder A, Crowe AE, *et al.* Dynamic telecytology compares favorably to rapid onsite evaluation of endoscopic ultrasound fine needle aspirates. *Dig Dis Sci* 2012;57:3092-7.
 13. Agarwal S, Zhao L, Zhang R, Hassell L. FaceTime validation study: Low-cost streaming video for cytology adequacy assessment. *Cancer Cytopathol* 2016;124:213-20.
 14. Dudas R, VandenBussche C, Baras A, Ali SZ, Olson MT. Inexpensive telecytology solutions that use the Raspberry Pi and the iPhone. *J Am Soc Cytopathol* 2014;3:49-55.
 15. Sirintrapun SJ, Cimic A. Dynamic nonrobotic telemicroscopy via skype: A cost effective solution to teleconsultation. *J Pathol Inform* 2012;3:28.

Supplementary Table 1: The initial set of 21 downgraded cases; which on further review 13 cases were discovered to have the wrong final assessment and were actually concordant with the telecytology adequacy assessment

Cytologic evaluation	Site	
Touch preparation	Bone	Iliac
Touch preparation	Bone	Sternum
Touch preparation	Kidney	
Touch preparation	Liver	
Touch preparation	Lung	
Touch preparation	Lung	
Touch preparation	Peritoneum	
Touch preparation	Soft tissue	Retropharyngeal
Touch preparation	Soft tissue	Supraclavicular mass
Touch preparation	Soft tissue	Thigh
Touch preparation	Soft tissue	Thigh
FNA	Head and neck	Cheek mass
FNA	Kidney	
FNA	Knee	
FNA	Liver	
FNA	Liver	
FNA	Lymph node	L5
FNA	Lymph node	Submandibular
FNA	Stomach	
FNA	Thyroid	
FNA	Thyroid	

FNA: Fine-needle aspiration