

## CASE REPORT

# Putting a new spin: MRI monitoring of hepatic artery and portal vein flow for response to bevacizumab in hereditary hemorrhagic telangiectasia

Numan Kutaiba<sup>1</sup>, Paul J. Gow<sup>2</sup>, Janine French<sup>2</sup> & Ruth P. Lim<sup>1</sup>

<sup>1</sup>Radiology, Austin Health, Melbourne, Victoria, Australia

<sup>2</sup>Liver Transplant Unit, Austin Hospital, Melbourne, Victoria, Australia

### Correspondence

Numan Kutaiba, Radiology, Austin Health, Melbourne, Victoria, Australia.

Tel: +61 3 9496 5431;

Fax: +61 3 9496 2456;

E-mail: nkutaiba@gmail.com

### Funding Information

No funding information provided.

Received: 13 May 2014; Accepted: 2 August 2014

*Clinical Case Reports* 2015; 3(1): 32–33

doi: 10.1002/ccr3.141

## To the Editor

Hereditary hemorrhagic telangiectasia (HHT) (Rendu–Osler–Weber syndrome) is an autosomal dominant disorder with estimated prevalence of 10–20/100,000 [1]. The principal pathology is telangiectasia of postcapillary dilated venules, which merge with arterioles without the interposed capillary bed, forming direct arteriovenous communications. Hepatic involvement is seen in 67–84% [2], with hepatic shunting causing increased cardiac preload, decreased peripheral vascular resistance, and adaptive increase in cardiac output. Recently, bevacizumab, a vascular endothelial growth factor inhibitor, has been proposed for treatment of symptomatic hepatic involvement in HHT [3]. We present a case where quantitative magnetic resonance imaging (MRI) was used for treatment monitoring.

## Case Report

A 55-year-old female with known hepatic HHT deteriorated rapidly over a 6-month period evidenced by portal hypertensive GI bleeding, anemia, ascites, and cachexia.

Baseline MRI was performed, comprising anatomic evaluation using contrast-enhanced 3D T1-weighted MR

### Key Clinical Message

Our case report demonstrates the use of phase contrast magnetic resonance imaging (MRI) in monitoring the functional status of liver vasculature in a patient with hereditary hemorrhagic telangiectasia (HHT) who was treated with bevacizumab. Our report provides additional information that can be further utilized in clinical settings and research.

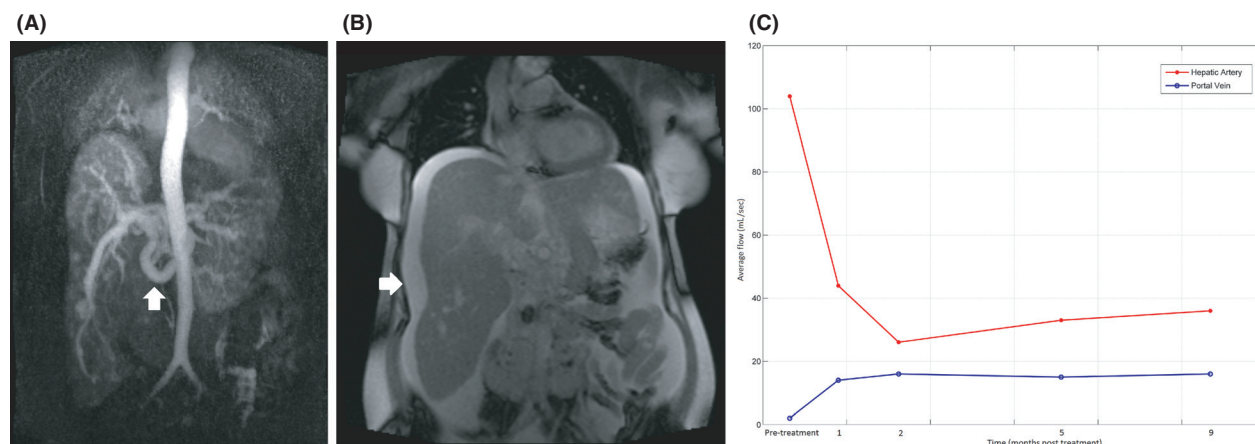
### Keywords

Angiogenesis inhibitors, blood flow velocity, hepatic artery, hereditary hemorrhagic telangiectasia, magnetic resonance imaging.

angiography and rapid T2-weighted imaging, followed by quantitation of hepatic artery (HA) and portal vein (PV) flow using phase contrast MRI. Hepatosplenomegaly was demonstrated. The proper HA was tortuous and dilated (1.6 cm diameter), with tortuous, dilated lobar, and corkscrew segmental branches (Fig 1A and B). The main PV was also dilated (2 cm diameter), with moderate volume ascites and small gastro-oesophageal varices consistent with portal hypertension.

Bevacizumab (5 mg/kg) was commenced, twice weekly for 12 weeks, then 12 weekly as a maintenance infusion. Serial MRI over the ensuing 9 months was performed, which demonstrated initial dramatic reduction in HA flow (104 to 24 mL/sec) and increase in PV flow (2–16 mL/sec), commensurate with clinical improvement, with cessation of GI bleeding, resolution of ascites, and weight gain.

From 6 months post initiation of therapy, recurrent symptoms developed approximately 10 weeks after each infusion, including intermittent melena, mild anemia, and ascites, with concurrent gradual deterioration in MRI-derived blood flow parameters (Fig 1C). After 9 months, infusion frequency was increased from 12 weekly to 10 weekly, with good clinical response.



**Figure 1.** Arterial appearance: dilated tortuous hepatic artery (HA) (arrow) (A); hepatomegaly (29 cm craniocaudal length) and ascites (arrow) (B); average flow of HA versus portal vein (PV) following treatment (C).

## Discussion

This is the first report using MRI to provide anatomic and functional monitoring of bevacizumab treatment for HHT. Historically, liver transplantation was the only option available for HHT patients with life-threatening high output cardiac and/or liver failure. Bevacizumab therapy for HHT was first proposed in 2008 [4], with an open label phase 2 study recently describing significant decrease in cardiac output, the primary outcome measure. While initial reports of bevacizumab are encouraging, Young et al. highlight the need for further evaluation with longitudinal randomized controlled trials, and evaluation of specific impact on hepatic abnormalities [5].

Color Doppler ultrasound has been shown to be a suitable first-line hepatic imaging modality in the general HHT population. However, it has acoustic window limitations and depends on operator experience and patient breath-holding ability. Functional MRI using phase contrast imaging has not previously been applied to HHT. Phase contrast MRI is a commercially available sequence traditionally used to quantify hemodynamics for cardiovascular applications [6]. It entails application of gradient pulses to induce phase shifts in moving protons that can be measured for quantitation of blood velocity and flow. It does not require injected contrast and can be acquired in less than 3 min per acquisition with a free breathing approach. Applied anecdotally to our case, serial HA and PV flow quantification enabled objective assessment of response to bevacizumab, in addition to standard morphologic assessment. Cardiac output can also potentially be measured with breath-hold phase contrast MRI through the aortic root at the

same examination. In conclusion, we suggest MRI as a potential objective, noninvasive means of titrating and monitoring bevacizumab therapy in the setting of hepatic HHT.

## Conflict of Interest

None declared.

## References

- Guttmacher, A. E., D. A. Marchuk, and R. I. White. 1995. Hereditary hemorrhagic telangiectasia. *N. Engl. J. Med.* 333:918–924.
- Sabba, C., and M. Pompili. 2008. Review article: the hepatic manifestations of hereditary haemorrhagic telangiectasia. *Aliment. Pharmacol. Ther.* 28: 523–533.
- Dupuis-Girod, S., I. Ginon, J. C. Saurin, D. Marion, E. Guillot, E. Decullier, et al. 2012. Bevacizumab in patients with hereditary hemorrhagic telangiectasia and severe hepatic vascular malformations and high cardiac output. *JAMA* 307:948–955.
- Mitchell, A., L. A. Adams, G. MacQuillan, J. Tibballs, R. Driesen vanden, and L. Delriviere. 2008. Bevacizumab reverses need for liver transplantation in hereditary hemorrhagic telangiectasia. *Liver Transpl.* 14:210–213.
- Young, L. H., K. J. Henderson, R. I. White, and G. Garcia-Tsao. 2013. Bevacizumab: finding its niche in the treatment of heart failure secondary to liver vascular malformations in hereditary hemorrhagic telangiectasia. *Hepatology* 58:442–445.
- Srichai, M. B., R. P. Lim, S. Wong, and V. S. Lee. 2009. Cardiovascular applications of phase-contrast MRI. *AJR Am. J. Roentgenol.* 192:662–675.