

CASE REPORT

Two cases of ceftriaxone-induced encephalopathy treated by hemoperfusion in hemodialysis patients

Chikao Onogi¹ | Akinori Osada² | Kentaro Imai² | Tetsushi Mimura¹ |
Yosuke Saka¹ | Yoshimichi Urahama² | Hideto Oishi² | Tomohiko Naruse¹

¹Department of Nephrology, Kasugai Municipal Hospital, Kasugai, Japan

²Department of Nephrology, Komaki City Hospital, Komaki, Japan

Correspondence

Chikao Onogi, Department of Nephrology, Kasugai Municipal Hospital, Takaki-cho 1-1-1, Kasugai, Aichi 486-8510, Japan.
Email: chikao.onogi@gmail.com

Funding information

This work was not supported by any funding agencies in the public, commercial, or nonprofit sectors.

Abstract

Ceftriaxone is a third-generation cephalosporin commonly used to treat infection. However, encephalopathy is an emerging adverse effect of ceftriaxone infusion. These patients present with various symptoms, including those of neurotoxicity, that typically resolve 1 week after discontinuation of ceftriaxone. We experienced two cases of ceftriaxone-induced encephalopathy that were successfully treated by rapid removal of ceftriaxone by hemoperfusion.

KEYWORDS

antibiotic-associated encephalopathy, ceftriaxone, ceftriaxone-induced encephalopathy, hemoperfusion

INTRODUCTION

Ceftriaxone is a third-generation cephalosporin commonly used in the treatment of infection.¹ It is not usually necessary to adjust the dose of ceftriaxone in patients with mild abnormal kidney function because approximately half of the ceftriaxone is excreted via the biliary system. However, ceftriaxone clearance is impaired in patients with end-stage kidney disease (ESKD).^{2,3} Several recent cases of encephalopathy as an adverse effect of ceftriaxone have been reported in patients with ESKD. Neurotoxicity due to high serum and cerebrospinal fluid (CSF) ceftriaxone concentrations is known to occur in ESKD patients.^{4,5} Here, we present two cases of ceftriaxone-induced encephalopathy in patients with ESKD in whom successful treatment was achieved by hemoperfusion. It is difficult to eliminate serum ceftriaxone by hemodialysis because of the high binding rate of ceftriaxone with serum albumin (90%–95%).⁶ Hemoperfusion can be used to eliminate toxic agents that have a

large molecular weight or a high protein binding rate,⁷ and is expected to be an effective method for treating ceftriaxone-induced encephalopathy. To the best of our knowledge, this is the first case report of hemoperfusion treatment for ceftriaxone-induced encephalopathy.

CASE PRESENTATION**Case 1**

A 78-year-old man on maintenance hemodialysis was admitted to our hospital with bacteremia caused by a urinary tract infection. His medical history included hypertension, ischemic stroke, type 2 diabetes mellitus, and ESKD due to diabetic nephropathy. Intravenous ceftriaxone was administered at a dosage of 2 g daily for 10 days (days 1–10). His level of consciousness began to deteriorate on day 8, and he had a Glasgow coma scale (GCS)

score of 5 points (E2V2M1) on day 11. Vital signs and physical examination showed no specific findings. A neurological examination found myoclonic jerks in the legs.

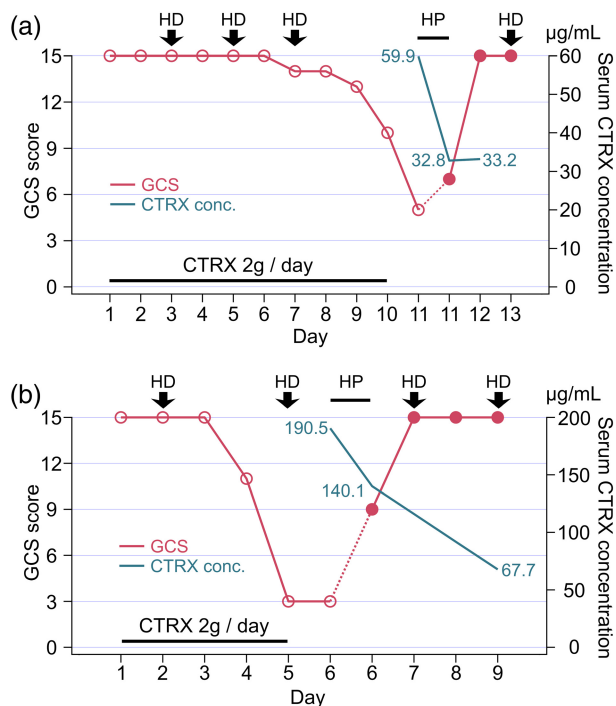


FIGURE 1 Clinical course in Case 1 (a) and Case 2 (b). CTRX conc., serum ceftriaxone concentration; CTRX, ceftriaxone; GCS, Glasgow coma scale; HD, hemodialysis; HP, hemoperfusion

Laboratory data, head computed tomography (CT), and magnetic resonance imaging (MRI) showed no evidence of acute stroke or other disorders causing the impaired consciousness. CSF analysis revealed no abnormalities. As there were no suspected drugs other than ceftriaxone, we changed ceftriaxone to levofloxacin (0.25 g alternate daily) on day 11. Also, on day 11, the patient underwent hemoperfusion (blood flow rate, 100 ml/min, Hemosorba CHS-350; Asahi Kasei; total throughput, 18 L). Following hemoperfusion, the patient's GCS score recovered immediately to 7, and then to 15 on day 12 (Figure 1a). Subsequently, we found that his serum ceftriaxone concentration was 59.9 µg/ml at pre hemoperfusion and 32.8 µg/ml at post hemoperfusion treatment. No exacerbation was observed after substitution of the antibiotics, which was indicative of ceftriaxone-induced encephalopathy as a diagnosis. The patient characteristics are listed in Table 1.

Case 2

A 38-year-old man on maintenance hemodialysis was admitted to our hospital with non-occlusive mesenteric ischemia and enteritis. His medical history included Leriche syndrome, intestinal malrotation, cholecystitis, and ESKD due to chronic glomerulonephritis. Ceftriaxone was administered at a dosage of 2 g daily for 5 days (days 1–5). The patient had an altered mental state and a GCS score of 11 (E3V3M4) with myoclonic leg movements on day 4. He had delirium due to severe abdominal pain and his

TABLE 1 Patient profiles and clinical summary

Characteristic	Case 1	Case 2
Age (year), sex	78, male	38, male
BW (kg), BMI (kg/m ²)	55.0, 21.8	51.2, 20.5
Primary cause of ESKD	Diabetic nephropathy	Chronic glomerulonephritis
Dialysis vintage	2 years 7 months	4 years 11 months
Dialysis prescription	4 h HD Polysulfone, 2.1 m ² Qb: 200 ml/min Qd: 500 ml/min	4 h HD Polysulfone, 2.1 m ² Qb: 200 ml/min Qd: 500 ml/min
Indication for CTRX	Urinary tract infection	Enteritis
Dosage of CTRX (g/day)	2 (days 1–10)	2 (days 1–5)
Serum concentration of CTRX (µg/ml)	59.9 (day 11, pre HP) 32.8 (day 11, post HP) 33.2 (day 12)	190.5 (day 6, pre HP) 140.1 (day 6, post HP) 67.7 (day 9)
CSF concentration of CTRX (µg/ml)	–	6.6 (day 6, pre HP)
Elimination half-life of CTRX (hours)	3.5 (HP phase)	9.0 (HP phase) 64.8 (post HP, days 6–9)

Abbreviations: BMI, body mass index; BW, body weight; CSF, cerebrospinal fluid; CTRX, ceftriaxone; ESKD, end stage kidney disease; HP, hemoperfusion; Qb, blood flow rate; Qd, dialysate flow rate.

symptoms showed no improvement despite treatment with haloperidol (5 mg). Laboratory and CT examinations revealed no specific findings. A CSF analysis revealed no abnormalities. Electroencephalography (EEG) revealed triphasic waves indicating metabolic or drug-induced encephalopathy. Considering the clinical course, ceftriaxone-induced encephalopathy was suspected; ceftriaxone was discontinued and changed to Meropenem (0.5 g daily). On day 6, the patient underwent hemoperfusion (blood flow rate, 100 ml/min, Hemosorba CHS-350; Asahi Kasei; total throughput, 24 L). With hemoperfusion treatment, his GCS score recovered immediately to 9, and was 15 points at day 7 after hemoperfusion (Figure 1b). Subsequent analysis of serum samples revealed high concentrations of ceftriaxone (190.5 µg/ml at pre hemoperfusion and 140.1 µg/ml at post hemoperfusion treatment). The ceftriaxone concentration in the CSF sample was 6.6 µg/ml. The patient characteristics are listed in Table 1.

DISCUSSION

Ceftriaxone-induced encephalopathy generally manifests within about 1 week after administration of ceftriaxone, and the encephalopathy shows resolution one or 2 weeks after discontinuation of ceftriaxone.⁸ Most of the clinical features are neurotoxic symptoms such as psychosis, seizure, myoclonus, and choreoathetosis that show no abnormalities in laboratory investigations, CT, or MRI. However, EEG shows slow and generalized periodic discharge with triphasic morphology.⁹

According to a previous report, the peak and trough concentrations of a 2 g daily dose of ceftriaxone administered to patients with normal kidney function were 236–284 and 8.8–21.2 µg/ml, respectively.¹⁰ The concentrations observed in the present cases were higher than the troughs of these reported values, which suggests that these two patients were exposed to high concentrations of ceftriaxone. In Case 2, the concentration of ceftriaxone in a CSF sample was 6.6 µg/ml, which is much higher than that of 0.18–1.04 µg/ml reported previously in the CSF of patients with uninflamed meninges.¹¹

The present results clearly indicate correlations of high concentrations of ceftriaxone in the serum and CSF samples with ceftriaxone neurotoxicity. Resolution of the neurotoxicity requires approximately 1 week with conservative treatment, which delays treatment of the infection. In the present cases, we used hemoperfusion as an aggressive treatment for ceftriaxone-induced encephalopathy. Hemodialysis is suitable for the removal of toxic agents with low molecular weight, low distribution volume, and low protein binding rate.¹² However, extraction of serum ceftriaxone is not enhanced during the hemodialysis procedure because

ceftriaxone has a high serum protein binding rate (90%–95%).^{6,13} Therefore, we performed hemoperfusion. In both patients, the consciousness level recovered remarkably during hemoperfusion, and returned to a normal state on the following day. Each patient showed remarkable improvements over time in the GCS score and serum ceftriaxone concentration in the hemoperfusion phase.

We applied a 1-compartment model ($C_p = C_0 * e^{-k*t}$, where C_p is serum ceftriaxone concentration, C_0 is initial serum ceftriaxone concentration, k is elimination rate constant, and t is time) to the change in serum ceftriaxone concentration to estimate the elimination half-life. In Case 1, the calculated half-life with hemoperfusion was 3.5 h, which is shorter than the elimination half-life of serum ceftriaxone concentration reported in healthy adults with normal kidney function (5.8–8.7 h).¹⁴ Removal of ceftriaxone during hemoperfusion (half-life: 9.0 h) was slower in Case 2 than Case 1. However, the half-life was far shorter with hemoperfusion than without hemoperfusion (64.8 h), which is the case in conservative treatment.

The present analysis clearly showed that hemoperfusion accelerated the elimination of serum ceftriaxone. Hemoperfusion treatment reduces the time of recovery to consciousness to within hours in patients with ceftriaxone-induced encephalopathy, whereas recovery requires approximately 1 week with conservative treatment. A prompt recovery enables treatment of infection to proceed and prevents complications. Although previous studies have reported hemoperfusion therapy for the elimination of toxic agents such as carbamazepine, disopyramide, and phenobarbital,^{15–17} few have discussed the application of extracorporeal removal techniques for antibiotics associated with encephalopathy, and none have mentioned the application of hemoperfusion to ceftriaxone-induced encephalopathy.

CONCLUSION

We experienced two cases of ceftriaxone-induced encephalopathy in patients with kidney impairment who were successfully treated by hemoperfusion. Considering the protein binding rate, hemoperfusion is preferable to hemodialysis for directly eliminating serum ceftriaxone.

ACKNOWLEDGMENTS

The authors would like to thank the patients for their contribution to this publication. Written informed consent was obtained from each patient.

CONFLICT OF INTEREST

The authors declare that they have no competing financial interests.

REFERENCES

1. Beam TR. Ceftriaxone: a beta-lactamase-stable, broad-spectrum cephalosporin with an extended half-life. *Pharmacotherapy*. 1985;5(5):237–53.
2. Goto K, Sato Y, Yasuda N, Hidaka S, Suzuki Y, Tanaka R, et al. Pharmacokinetics of ceftriaxone in patients undergoing continuous renal replacement therapy. *J Basic Clin Physiol Pharmacol*. 2016;27(6):625–31.
3. Simon N, Dussol B, Sampol E, Purgus R, Brunet P, Lacarelle B, et al. Population pharmacokinetics of ceftriaxone and pharmacodynamic considerations in haemodialysed patients. *Clin Pharmacokinet*. 2006;45(5):493–501.
4. Inoue Y, Doi Y, Arisato T, Sugioka S, Koga K, Nishioka K, et al. Three cases of hemodialysis patients receiving high-dose ceftriaxone: serum concentrations and its neurotoxicity. *Kidney Int Rep*. 2017;2(5):984–7.
5. Suzuki S, Naito S, Numasawa Y, Asada M, Shoji N, Zeniya M, et al. Encephalopathy induced by high plasma and cerebrospinal fluid ceftriaxone concentrations in a hemodialysis patient. *Internal Med*. 2019;58(12):1775–9.
6. Popick AC, Crouthamel WG, Bekersky I. Plasma protein binding of ceftriaxone. *Xenobiotica*. 1987;17(10):1139–45.
7. Holubek WJ, Hoffman RS, Goldfarb DS, Nelson LS. Use of hemodialysis and hemoperfusion in poisoned patients. *Kidney Int*. 2008;74(10):1327–34.
8. Bhattacharyya S, Darby RR, Raibagkar P, Gonzalez Castro LN, Berkowitz AL. Antibiotic-associated encephalopathy. *Neurology*. 2016;86(10):963–71.
9. Grill MF, Maganti R. Cephalosporin-induced neurotoxicity: clinical manifestations, potential pathogenic mechanisms, and the role of electroencephalographic monitoring. *Ann Pharmacother*. 2008;42(12):1843–50.
10. Pollock AA, Tee PE, Patel IH, Spicehandler J, Simberkoff MS, Rahal JJ. Pharmacokinetic characteristics of intravenous ceftriaxone in normal adults. *Antimicrob Agents Chemother*. 1982;22(5):816–23.
11. Nau R, Prange HW, Muth P, Mahr G, Menck S, Kolenda H, et al. Passage of cefotaxime and ceftriaxone into cerebrospinal fluid of patients with uninflamed meninges. *Antimicrob Agents Chemother*. 1993;37(7):1518–24.
12. Garella S. Extracorporeal techniques in the treatment of exogenous intoxications. *Kidney Int*. 1988;33(3):735–54.
13. Cohen D, Appel GB, Neu HC. Pharmacokinetics of ceftriaxone in patients with renal failure and in those undergoing hemodialysis. *Antimicrob Agents Chemother*. 1983;24(4):529–32.
14. Patel IH, Kaplan SA. Pharmacokinetic profile of ceftriaxone in man. *Am J Med*. 1984;77(4C):17–25.
15. Ghannoum M, Yates C, Galvao TF, Sowinski KM, Vo THV, Coogan A, et al. Extracorporeal treatment for carbamazepine poisoning: systematic review and recommendations from the EXTRIP workgroup. *Clin Toxicol(Phila)*. 2014;52(10):993–1004.
16. Iguchi S, Yamaguchi N, Takami H, Komatsu T, Ookubo H, Sekii H, et al. Higher efficacy of hemoperfusion using coated activated charcoal column for disopyramide poisoning: a case report. *Medicine*. 2017;96(49):e8755.
17. Mizushima S, Hirose Y, Yuzawa H, Kimura T, Oguchi M, Morito T, et al. Efficacy of direct hemoperfusion for the removal of phenobarbital through blood concentration analysis. *Acute Med Surg*. 2020;7(1):e601.

How to cite this article: Onogi C, Osada A, Imai K, Mimura T, Saka Y, Urahama Y, et al. Two cases of ceftriaxone-induced encephalopathy treated by hemoperfusion in hemodialysis patients. *Hemodialysis International*. 2022;26:E27–30. <https://doi.org/10.1111/hdi.13018>