



Case Report

Ebstein's anomaly with pericardial effusion in a 55-year-old lady: A case report

Priyanka Poudel^b, Sujan Pathak^{b,*}, Nishan Bhattarai^a^a Cardiology Unit, Department of Internal Medicine, Kathmandu University School of Medical Sciences, Dhulikhel Hospital, Dhulikhel, 45210, Nepal^b Kathmandu University School of Medical Sciences, Dhulikhel Hospital, Dhulikhel, 45210, Nepal

ARTICLE INFO

Keywords:

Case report
Ebstein's anomaly
Pericardial effusion

ABSTRACT

Introduction: and importance: Ebstein's anomaly (EA) is a rare congenital heart disease characterized by apical displacement of the tricuspid valve associated with atrialization of the right ventricle. Most of the cases are diagnosed in childhood but asymptomatic cases may remain undiagnosed and survive until old age.

Case presentation: We present a rare case of Ebstein's Anomaly with pericardial effusion which was diagnosed for the first time in her mid-fifties when she developed atrial fibrillation and right heart failure with severe tricuspid regurgitation, which was managed medically.

Clinical discussion: The patient with Ebstein's anomaly can be found even at an older age with variable presentation and the association with pericardial effusion although very rare can present in such patients.

Conclusion: Ebstein's anomaly despite being a rare congenital condition can present clinically even beyond the age of fifty without any previous diagnosis and surgical intervention for the condition. It usually presents with features of heart failure and arrhythmia but can also have a rare association like pericardial effusion.

1. Introduction

Ebstein's anomaly (EA) is a rare congenital heart disease that causes tricuspid valve malformation and atrialization of the right ventricle [1]. This condition has an incidence of 1 in 200,000 live births [2]. The mean age of diagnosis in adult patients is 23.9 ± 10.4 years according to a study [3]. Here, we present a rare case of a 55-year-old lady with an Ebstein's anomaly, in an unoperated condition till now which was also associated with pericardial effusion, a rare co-existence with Ebstein's anomaly.

This case report has been reported in accordance with the SCARE criteria [4].

2. Case details

A 55-year-old lady presented to the emergency department of our hospital via ambulance with complaints of central chest pain and palpitation for four days. She had no history of hypertension, hyperlipidemia, diabetes mellitus, and thyroid diseases. On examination, she was tachycardic with an irregularly irregular pulse, her blood pressure was 70/50 mm of Hg and her JVP was raised. Pedal edema was present.

However, cyanosis and clubbing were absent. On auscultation, first and second heart sounds were audible along with systolic murmur.

Routine investigations were done with chest X-ray, electrocardiography (ECG), and echocardiography (echo). Chest X-ray showed huge cardiomegaly (Fig. 1) ECG suggested atrial fibrillation (AF), right ventricular hypertrophy, and right bundle branch block as shown in Fig. 2. Echocardiography revealed a huge right atrium, atrialization of the right ventricle, severe tricuspid regurgitation, mild mitral regurgitation, moderate pericardial effusion, and displacement of tricuspid valve septal leaflet 15.04 per meter square as shown in Fig. 3. The interatrial septum was intact and there was an absence of patent ductus arteriosus. The patient was diagnosed with EA with atrial fibrillation and moderate pericardial effusion.

The patient was managed medically for atrial fibrillation, pericardial effusion, and heart failure. A prophylactic anticoagulant was given as she had a high risk of thromboembolism. After four days of close monitoring and treatment, the patient improved clinically and her vitals were stable. She was discharged with amiloride, metoprolol, and oral anticoagulants. She was called on follow-up after two weeks to discuss surgical treatment of EA.

On her follow-up, the patient was counseled about surgical treatment

* Corresponding author.

E-mail addresses: drpriyankapoudel@gmail.com (P. Poudel), drsujanpathak@gmail.com (S. Pathak), nishanbhattarai0213@gmail.com (N. Bhattarai).<https://doi.org/10.1016/j.amsu.2022.104821>

Received 22 July 2022; Received in revised form 27 September 2022; Accepted 30 October 2022

Available online 5 November 2022

2049-0801/© 2022 The Authors. Published by Elsevier Ltd on behalf of IJS Publishing Group Ltd. This is an open access article under the CC BY-NC-ND license (<http://creativecommons.org/licenses/by-nc-nd/4.0/>).

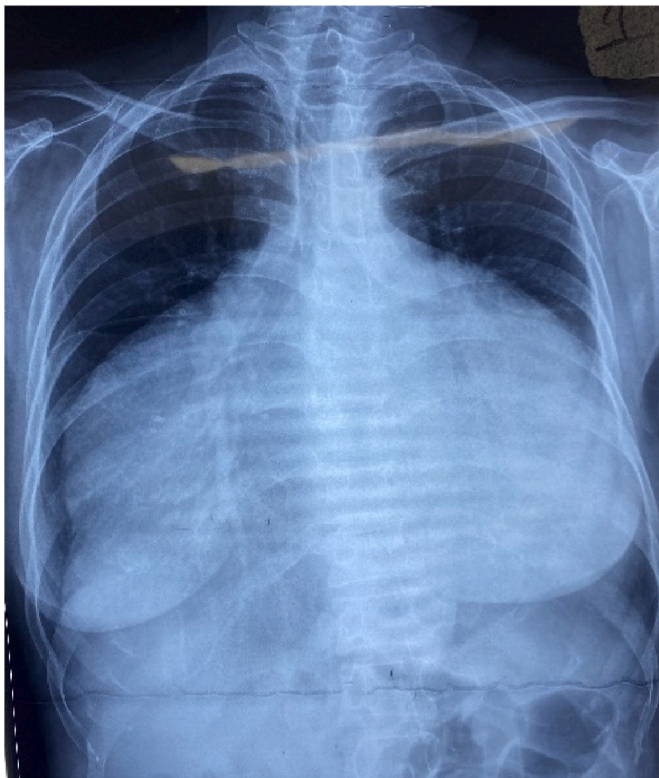


Fig. 1. Chest X-ray shows an increase in the cardiothoracic ratio and right atrial and ventricular hypertrophy.

modalities but she wanted to get medical management only. She is continuing on her medications currently.

The patient is on regular follow-up every month at our hospital. ECG, echo and Chest X-ray is done to access the condition monthly. The condition of the patient is not improving however she is not deteriorating either.

3. Discussion

Ebstein's anomaly is a congenital heart disease characterized by a typical degree of apical displacement of the septal tricuspid leaflet more than or equal to 8 mm per meter square [1]. Most cases are presented and diagnosed in early childhood [2]. It is present since birth and rarely may remain asymptomatic till adulthood as in our case [1].

EA is associated with genetic, reproductive, and environmental risk

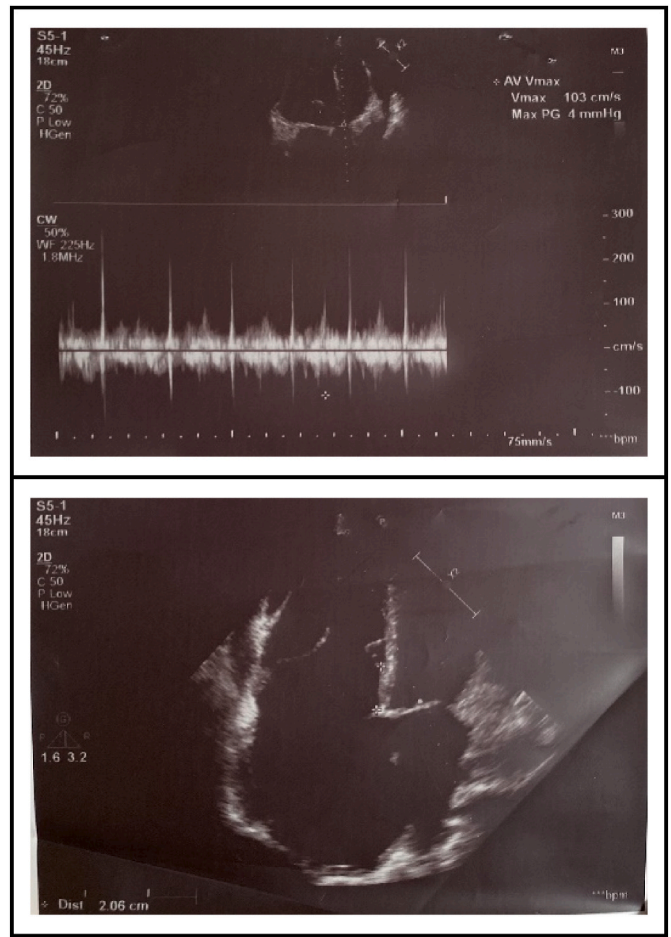


Fig. 3. ECHO shows a huge right atrium, atrialization of the right ventricle, severe tricuspid regurgitation, mild mitral regurgitation, AF rhythm, and moderate pericardial effusion.

factors like family history of congenital heart disease, twins, and maternal benzodiazepines or lithium intake [2].

During the development of the heart, tricuspid valve leaflets are formed equally from the myocardium and endocardial cushions by delamination of the inner layers of the inlet zone of ventricles [2]. The failure of delamination of tricuspid valve leaflets from the ventricular myocardium causes adherence of leaflets to the underlying myocardium resulting in EA [2].

Patients with EA present with variable clinical features like cyanosis

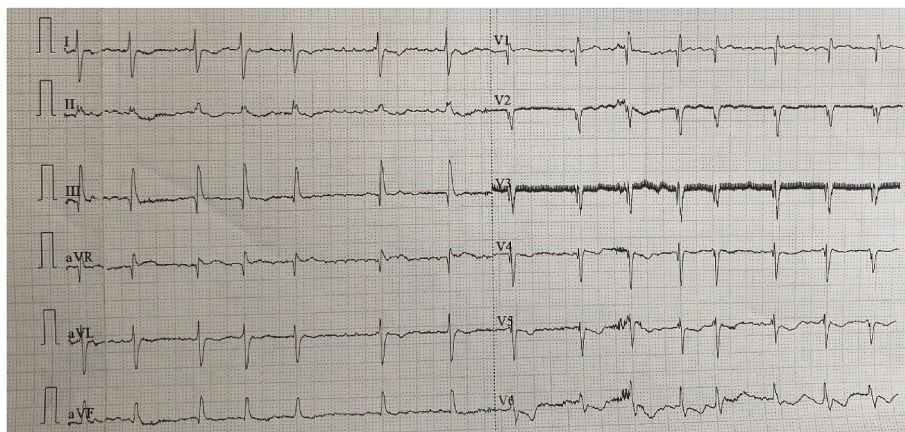


Fig. 2. ECG shows atrial fibrillation (AF), right ventricular hypertrophy, and right bundle branch block.

and right-sided heart failure in pediatric populations and arrhythmia in adult groups [2]. In our case, patients presented with features of arrhythmia and heart failure in the mid-fifties.

In order to diagnose EA, Chest X-ray, ECG and echo can be used while transthoracic echo is the standard imaging modality [1]. Chest radiograph shows a globular appearance of the heart due to right atrial enlargement [1]. ECG typically shows tall P waves, PR interval prolongation, and degree of right bundle branch block (RBBB) [1]. Sometimes patients also present with atrial fibrillation or flutter or ectopic atrial tachycardia or atrioventricular nodal reentrant tachycardia [1]. In our case, the Chest radiograph showed cardiomegaly with right atrial and ventricular hypertrophy. ECG was suggestive of atrial fibrillation.

Transthoracic echocardiography is used to assess the right side of the heart in terms of anatomy and its function [1]. The co-existence of Ebstein's anomaly and pericardial effusion is very rare [5]. In our patient, echo revealed a huge right atrium, atrialization of the right ventricle, severe tricuspid regurgitation, with an intact interatrial septum. It also showed moderate pericardial effusion, which is a rare presentation in Ebstein's anomaly.

Definitive management of EA is the surgical correction of the right side of the heart including the tricuspid valve. However, asymptomatic patients can be managed with medical treatment for several years until the patient starts symptoms on exercise or develops right ventricular dysfunction [1]. Only less than five percent of patients with EA survive beyond 50 years of age without any operative intervention [6]. In our case, the patient was diagnosed with EA associated with pericardial effusion at the age of 55 having features of arrhythmia and heart failure. So, medical management was done for the same and the patient was counseled about surgical treatment modalities but she refused to undergo the operative procedure, so she is currently under medical management. Although Ebstein's anomaly needs surgical management, we may encounter cases where the surgery isn't possible, the patient is reluctant to surgery or, Risk-Benefit ratio is unfavorable for surgery. In such conditions, medical management remains the only option to manage the complications and maintain the adequate day-to-day activities of the patient. In response to these findings and work, research on outcome assessment, impact on daily life activities, mental health, and financial toxicity should be done in the future.

4. Conclusion

Although being a rare presentation, a previously undiagnosed case of Ebstein's anomaly can present clinically even in the older age group as in our case, beyond the fifties. Works of literature have shown very less documentation of pericardial effusion associated with Ebstein's anomaly but our case is an example of such a condition. EA at old age with associated pericardial effusion, though very rare, can present clinically.

Ethical approval

As the case report contains information on the retrospective period, we obtained an exemption for ethical approval from the Institutional ethical committee.

Sources of funding

None.

Authors' contribution

Dr. Nishan Bhattarai contributed to clinical management, patient

care and manuscript editing.

Sujan Pathak and Priyanka Poudel wrote and edited the manuscript.

Registration of research studies

1. Name of the registry: N/A
2. Unique identifying number or registration ID: N/A
3. Hyperlink to your specific registration (must be publicly accessible and will be checked): N/A

Guarantor

The Guarantor is the one or more people who accept full responsibility for the work and/or the conduct of the study, had access to the data, and controlled the decision to publish.

Consent

Written informed consent was obtained from the patient for publication of this case report and accompanying images. A copy of the written consent is available for review by the Editor-in-Chief of this journal on request.

Availability of supporting data

All supporting documents are submitted along with the case report.

Provenance and peer review

Not commissioned, externally peer reviewed.

Declaration of competing interest

There are no conflicts of interest.

Acknowledgment

N/A.

Appendix A. Supplementary data

Supplementary data to this article can be found online at <https://doi.org/10.1016/j.amsu.2022.104821>.

References

- [1] K.A. Holst, H.M. Connolly, J.A. Dearani, Ebstein's anomaly, *Methodist Debaque Cardiovasc. J* 15 (2) (Apr. 2019) 138–144.
- [2] C.H. Attenhofer Jost, H.M. Connolly, J.A. Dearani, W.D. Edwards, G.K. Danielson, Ebstein's anomaly, *Circulation* 115 (2) (Jan. 2007) 277–285.
- [3] F. Attie, et al., The adult patient with Ebstein anomaly. Outcome in 72 unoperated patients, *Medicine* 79 (1) (Jan. 2000) 27–36.
- [4] R.A. Agha, et al., The SCARE 2020 guideline: updating consensus surgical CAse REport (SCARE) guidelines, *Int. J. Surg.* 84 (2020) 226–230, <https://doi.org/10.1016/j.ijssu.2020.10.034>.
- [5] G. Llamas-Esperón, R. Alemán-Villalobos, A. Zamora-Muciño, L. Delgado-Leal, A. Jiménez-Serrano, S. González-Romero, [Ebstein's anomaly related with significant pericardial effusion. Report and analysis of a case], *Gac. Med. Mex.* 134 (4) (Jul. 1998) 479–486.
- [6] S. Aoyagi, K. Yoshitake, A. Matsuo, K.-I. Tayama, S. Hida, T. Mito, Ebstein's anomaly in adult patients over 50 years of age, *Kurume Med. J.* 60 (3.4) (2014) 115–117, <https://doi.org/10.2739/kurumedj.ms63007>.