


# Inferior vena cava filter misplacement in the right atrium and migration to the right ventricle followed by successful removal using the endovascular technique: A case report and review of the literature

SAGE Open Medical Case Reports  
3: 2050313X15595833  
© The Author(s) 2015  
Reprints and permissions:  
sagepub.co.uk/journalsPermissions.nav  
DOI: 10.1177/2050313X15595833  
sco.sagepub.com  


Yasushi Wakabayashi<sup>1,2</sup>, Wataru Takeuchi<sup>1</sup> and Kyohei Yamazaki<sup>1</sup>

## Abstract

Inferior vena cava filters are effective for preventing the passage of thrombi into the pulmonary arteries in patients with pulmonary embolism and deep vein thrombosis. These filters are indicated in patients with contraindications to anticoagulant therapy or in patients with recurrent acute pulmonary embolism despite the administration of anticoagulant therapy. However, the occurrence of filter-related complications, such as filter migration to the heart, has been increasing. Herein, we report a case of OptEase inferior vena cava filter misplacement in the right atrium. Although the filter migrated to the right ventricle, it was successfully removed and repositioned in the inferior vena cava using endovascular techniques. Unfortunately, moderate tricuspid regurgitation developed, due to the damage to the tricuspid valve that was caused by the procedure. We have also reviewed the relevant literature and discussed the possible strategies for managing cases of filter migration to the heart and preventing filter misplacement.

## Keywords

Inferior vena cava filter, pulmonary embolism, deep vein thrombosis, filter migration, endovascular technique

Date received: 2 February 2015; accepted: 21 June 2015

## Case report

Our institution does not require ethics approval for reporting individual cases. However, we obtained written informed consent from the patient for the publication of this report.

A 72-year-old man was admitted to our hospital with dyspnea on exertion and was diagnosed with acute pulmonary embolism (PE) and deep vein thrombosis in the left popliteal vein. Although anticoagulant therapy was administered, he experienced recurrence of the PE. Therefore, we implanted an OptEase inferior vena cava (IVC) filter (Cordis Corp., Miami Lakes, FL).

We selected the right cubital venous approach to place the filter. A 6-Fr-long sheath was inserted with the accompanying dilator up to the level of the renal vein, the dilator was removed, and the filter was inserted into the sheath and pushed into the tip of the sheath using the dilator. However, we found that the tip of the sheath had accidentally become lodged in the right renal vein. Therefore, we pulled the system up to the right atrium (RA) to change the direction of

the tip while leaving the filter in the sheath because the OptEase filter in the sheath could not be pulled back. Unfortunately, we inadvertently pushed the dilator that had been left in the sheath, which caused the filter to drop out of the sheath in the RA, and the filter subsequently migrated into the right ventricle (RV). Repeated ventricular tachycardia with syncope occurred due to the filter's stimulation, and we considered adopting a surgical approach via sternotomy. However, facilities for cardiovascular surgery were not available at our institution, and it would have required

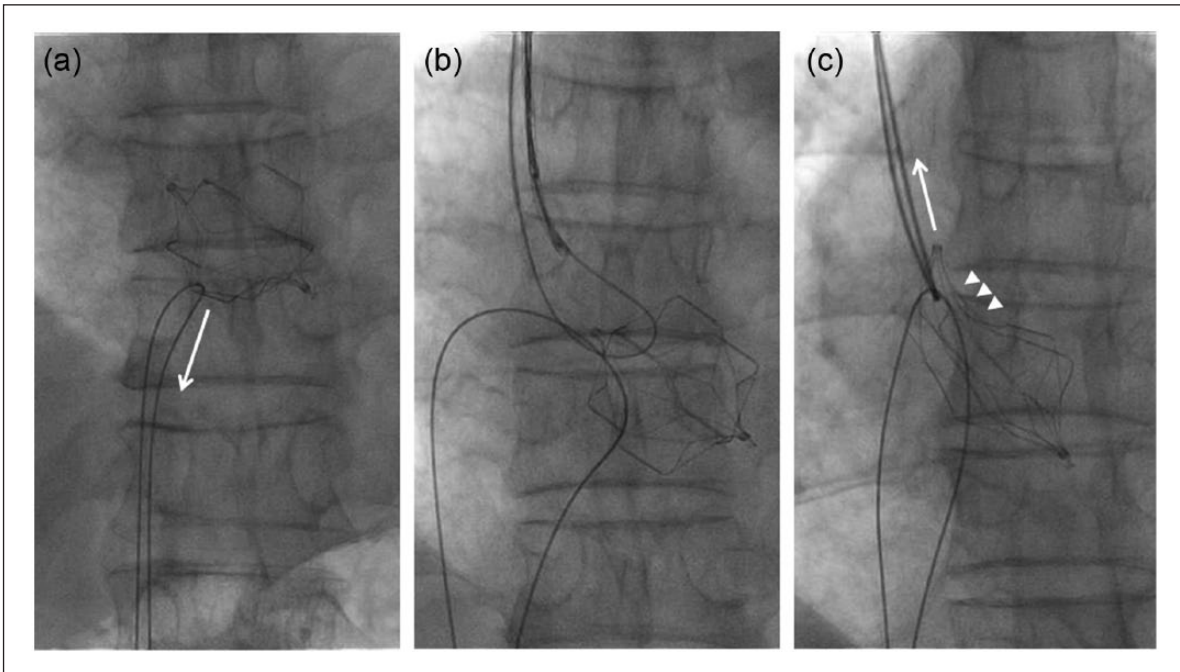
<sup>1</sup>Department of Cardiovascular Medicine, Nagano Prefectural Kiso Hospital, Nagano, Japan

<sup>2</sup>Department of Cardiovascular Medicine, Saitama Medical Center, Jichi Medical University, Saitama, Japan

## Corresponding Author:

Yasushi Wakabayashi, Department of Cardiovascular Medicine, Saitama Medical Center, Jichi Medical University, 1-847 Amanuma, Omiya-ku, Saitama City, Saitama 330-8503, Japan.  
Email: 99098yw@jichi.ac.jp





**Figure 1.** (a) The inferior vena cava filter in the right ventricle was pulled from the right and left femoral veins using a guide wire, although the filter was lodged in the tricuspid valve and could not be removed. (b) The filter in the right ventricle was pulled cranially from the right cubital and internal jugular veins using the jugular or cubital wire loop. (c) The filter was passed through the tricuspid valve. The arrows indicate the direction of the force applied by the guide wire, and the arrowheads indicate the deformed structure of the filter.

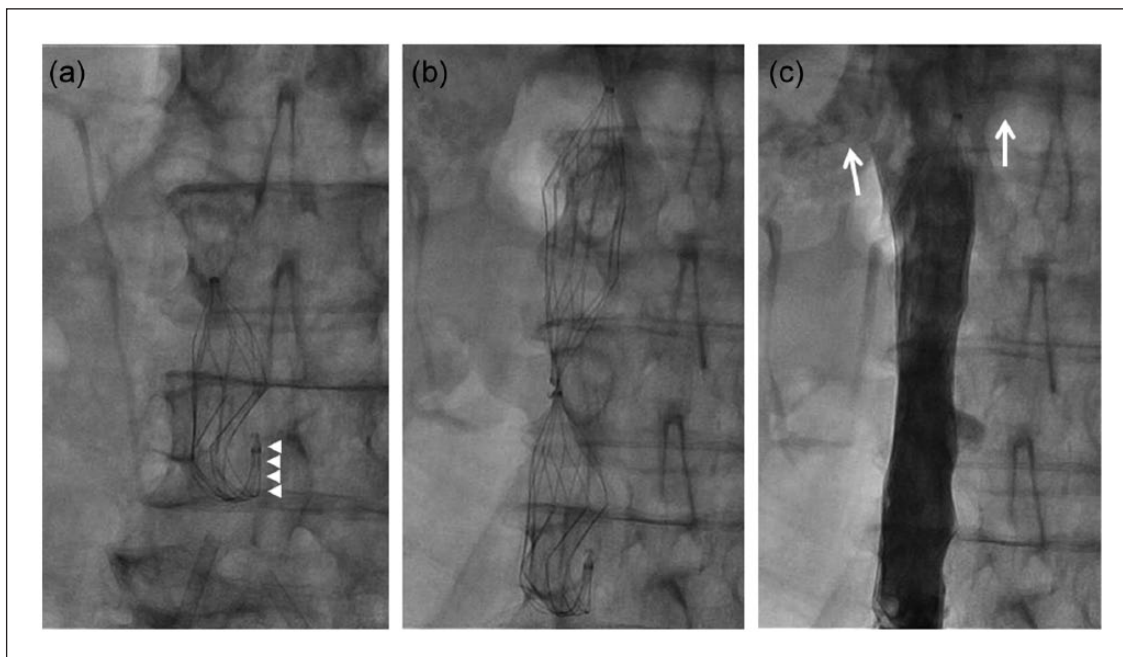
more than 2 h to transport the patient to a hospital with cardiovascular surgery facilities. Therefore, we selected percutaneous retrieval of the filter as the therapeutic approach.

Our original plan was to capture the filter using a snare, remove it from the RV, draw it to the IVC, and retrieve it. We initially attempted to capture the filter using an En Snare (SHEEN MAN Corp., Osaka, Japan) and various 6-Fr guide catheters from the right femoral vein, although we could not capture the filter because its hook was oriented in the direction of the right ventricular apex. Therefore, we inserted a 0.035 Radifocus stiff guide wire (Terumo Corp., Tokyo, Japan) using a 4-Fr multipurpose catheter (Medikit Corp., Tokyo, Japan) from the left femoral vein and passed the guide wire through the filter. We then inserted the En Snare using a 6-Fr Judkins Left 4.0 guide catheter (Medikit Corp.) from the right femoral vein and held the guide wire using the En Snare device. Next, we attempted to remove the filter by pulling the Radifocus guide wire and the system from the femoral veins. However, the filter was lodged in the tricuspid valve, and we failed to remove the filter from the RV (Figure 1(a)). Therefore, we passed another 0.035 Radifocus stiff guide wire through the filter using a 4-Fr pig tail catheter (St. Jude Medical Corp., St. Paul, MN) from the right cubital vein. We also inserted an Amplatz Goose Neck Snare (Covidien plc., Dublin, Ireland) using a 6-Fr Mach 1 Femoral Curved Right 4.0 guide catheter (Boston Scientific Corp., Natick, MA) from the right internal jugular vein and held the guide wire using the Goose Neck Snare (Figure 1(b)). The filter was pulled cranially using the jugular or cubital wire loop, which

successfully removed it from the RV, although this action deformed the filter (Figure 1(c)). In addition, we felt considerable resistance while pulling the Radifocus stiff guide wire and the system, which suggested that the filter had become entangled in the tricuspid valve. We then pulled the filter from the femoral veins using the original Radifocus stiff guide wire, and the filter subsequently became positioned in the lower IVC immediately above the iliac venous confluence (Figure 2(a)). However, we could not retrieve the filter because it was deformed, especially around the hook (Figure 2(a)). Therefore, we implanted a second filter between the renal veins and the first filter to prevent recurrent PE (Figure 2(b) and (c)). We used 120 mL of contrast media, and the total fluoroscopy time was 72 min. Transthoracic echocardiography revealed the occurrence of new moderate tricuspid regurgitation (TR) due to the damage caused by the traumatic extraction, although the patient did not complain of any symptoms. He did not experience infection or any other complications, and we confirmed that the filters remained in place after 6 months using abdominal radiography.

## Discussion

Intracardiac migration of IVC filters is an uncommon and potentially life-threatening event. However, the reported occurrence of filter migration to the heart has been increasing,<sup>1</sup> Owens et al. have reviewed publications regarding intracardiac migration of IVC filters and reported 98 cases between 1977 and 2008. They reported that this complication often



**Figure 2.** (a) The deformed inferior vena cava filter was located above the common iliac vein bifurcation. (b) A second filter was implanted over the deformed filter to prevent recurrent pulmonary embolism. (c) A venography revealed that the second filter was located below the renal veins. The arrows indicate the bilateral renal veins, and the arrowheads indicate the deformed structure around the hook of the filter.

**Table 1.** Reported cases of successful percutaneous removal of IVC filter from the RV.

Case	Reference	Age/sex	Filter	Arrhythmia	Device for extraction	New TR
A	Arjomand et al. <sup>4</sup>	55/male	GF	Unclear	Basket catheter	Unclear
B	Kuo et al. <sup>5</sup>	63/male	G2	VT	Snare	Unclear
C	Bui et al. <sup>6</sup>	61/male	G2	Unclear	Snare	(-)
D	Veerapong et al. <sup>7</sup>	31/male	GT	VT, RBBB	Snare	(-)
E	Peters et al. <sup>3</sup>	69/male	OptE	VT	Guide catheter and wire	(+)
Present case	Wakabayashi et al.	72/male	OptE	VT	Guide wire	(+)

GF: Greenfield; GT: Günther-Tulip; IVC: inferior vena cava; OptE: OptEase; RBBB: right bundle branch block; RV: right ventricle; TR: tricuspid regurgitation; VT: ventricular tachycardia.

induced arrhythmia symptoms, such as chest pain, dyspnea, and syncope, and myocardial perforation and/or injuries that included damage to the chordae tendineae and/or the tricuspid valve. The causes of filter migration included operator error, failure of the filter legs to open, fracture, sail effect induced by a large-burden clot trapped within the filter, and/or mega cava. Owens et al. also reported that the majority of filters had migrated to the RA, and only approximately 20% of the migrated filters (20/98) were located in the RV. In addition, only four of eight percutaneous attempts to remove filters from the RV were successful, and these were all retrievals of conical filters.<sup>2</sup> To our knowledge, only one case involving endovascular removal of an OptEase IVC filter from the RV has been reported,<sup>3</sup> and this filter has a trapezoidal shape that is different from the conical shape.

The details of previous cases involving endovascular removal of filters from the RV and the present case are shown

in Table 1.<sup>3-7</sup> In case A, the operator captured the filter using a basket catheter and pulled the filter from the RV, although it was not clear whether TR occurred after the procedure. In contrast, in cases B, C, and D, the filters were removed using snares. In cases B and C, the operators captured the filter head directly using the snares and pulled the filter as the head of the filter crossed the tricuspid valve. In case D, the operator captured one of the filter's legs using a snare and removed it from the RV without resistance. After the procedure, TR was absent in cases C and D, although it was unclear whether TR occurred in case B. In case E, which involved an OptEase filter, the operator advanced a guide wire and 6-Fr guide catheter through the filter, looped the wire and catheter, snared the other side of the wire, and pulled the filter slowly using the catheter and wire from the femoral vein. However, the operator felt considerable resistance during the withdrawal and observed that new severe TR had developed due to the tricuspid valve damage.

In the present case, we attempted to capture the OptEase filter using the En Snare, although we were not successful. Our technique was similar to that used in case E, although the guide catheter was not advanced through the filter and the femoral approach failed. In the present case, we also could have removed the filter from the RV using the internal jugular and cubital approach. This approach might have facilitated the smooth passage of the devices through the tricuspid valve and provided an appropriate vector for withdrawing the devices and filter because the tricuspid valve is oriented cranially. Although we were accustomed to puncturing the femoral vein and selected the femoral approach for the initial procedure, an approach from a cranial site (e.g. the internal jugular vein) may be more appropriate for the endovascular removal of a filter in the RV. We also felt resistance during the withdrawal and observed the development of new moderate TR after the procedure. We had advanced two guide wires and entangled these wires with the filter and subsequently pulled one wire from the two femoral veins and the other wire from the cubital and jugular veins. This bi-route approach (i.e. right cubital–right jugular veins or right femoral–left femoral veins) may be a technically easy procedure as separate guide catheters are used to manipulate the guide wire and snare. However, the bi-route approach or two-wire technique may have increased the possibility of the chordae becoming entangled with the looped guide wires and subsequently induced the chordae rupture and new TR. Furthermore, if we had used a large-bored long sheath, as in a previous report,<sup>5</sup> we might have been able to capture the hook of the filter via the snare, pull the filter from the RV without resistance, and avoid the filter deformation and the new TR. We might also have been able to fit the barbs or struts of the filter into the large-bored sheath's lumen, in order to prevent the tricuspid valve damage and subsequently retrieve the filter from the vein.

The cause of filter migration in the present case was operator error, which was likely induced by the cubital approach. This approach uses a long, curved, and twisted course to reach the infrarenal IVC and can easily cause malpositioning of a long sheath tip. Furthermore, the cubital or jugular approach can complicate the prompt re-capturing or re-positioning of the OptEase filter once it is implanted in the IVC because its hook is oriented in opposite to the end of the sheath in these approaches. Based on these considerations, we should have selected the femoral approach for the filter implantation. In addition, inferior vena cavography should have been performed before the filter insertion, which would have identified the malpositioned sheath and allowed re-positioning of the tip to the infrarenal IVC. In this context, inferior vena cavography before filter insertion is especially important when using OptEase filters because the filter cannot be pulled back once it is inserted in the sheath. Furthermore, cavography can be used to measure the diameter of the IVC and to determine the size of the filter.

There is no definite consensus regarding the optimal management for patients with filter migration to the heart because there is only limited evidence available. According to Owens et al.'s<sup>2</sup> review, several migrated filters in the heart were left in place, and the patients subsequently remained in good

health, asymptomatic, and/or alive. However, we believe that the filters should be removed from the heart, because the intracardiac filter migration is often life-threatening.<sup>8</sup> Open heart surgery is suggested as the gold standard because it enables immediate repair of any damage that is caused by the filter.<sup>2,9</sup> However, if the patient is unstable and not a good candidate for surgery or cannot receive surgery promptly for other reasons, endovascular retrieval is a possible alternative. When performing endovascular removal of IVC filters in the RV, direct capture using snares should be selected as the initial technique. If this technique fails, withdrawal by entangling a catheter or guide wire in the filter may be considered because there does not appear to be any better alternative. However, this endovascular technique can cause the development of new TR due to tricuspid valve damage.

### Acknowledgement

None.

### Declaration of conflicting interests

The authors declared no potential conflicts of interest with respect to the research, authorship, and/or publication of this article.

### Funding

This report was not funded by any funding agency in the public, commercial, or not-for-profit sectors.

### References

1. Wang SL and Lloyd AJ. Clinical review: inferior vena cava filters in the age of patient-centered outcomes. *Ann Med* 2013; 45(7): 474–481.
2. Owens CA, Bui JT, Knuttinen MG, et al. Intracardiac migration of inferior vena cava filters: review of published data. *Chest* 2009; 136(3): 877–887.
3. Peters MN, Khazi Syed RH, Katz MJ, et al. Inferior vena cava filter migration to the right ventricle causing nonsustained ventricular tachycardia. *Tex Heart Inst J* 2013; 40(3): 316–319.
4. Arjomand H, Surabhi S and Wolf NM. Right ventricular foreign body: percutaneous transvenous retrieval of a Greenfield filter from the right ventricle—a case report. *Angiology* 2003; 54(1): 109–113.
5. Kuo WT, Loh CT and Sze DY. Emergency retrieval of a G2 filter after complete migration into the right ventricle. *J Vasc Interv Radiol* 2007; 18(9): 1177–1182.
6. Bui JT, West DL, Pinto C, et al. Right ventricular migration and endovascular removal of an inferior vena cava filter. *J Vasc Interv Radiol* 2008; 19(1): 141–144.
7. Veerapong J, Wahlgren CM, Jolly N, et al. Successful percutaneous retrieval of an inferior vena cava filter migrating to the right ventricle in a bariatric patient. *Cardiovasc Intervent Radiol* 2008; 31(Suppl. 2): S177–S181.
8. Haddadian B, Shaikh F, Djelmami-Hani M, et al. Sudden cardiac death caused by migration of a TrapEase inferior vena cava filter: case report and review of the literature. *Clin Cardiol* 2008; 31(2): 84–87.
9. Izutani H, Lalude O, Gill IS, et al. Migration of an inferior vena cava filter to the right ventricle and literature review. *Can J Cardiol* 2004; 20(2): 233–235.