

## Effectiveness and Safety of Percutaneous Transcatheter Implantation of Pulmonary Arterial Stent in Congenital Heart Disease

Hong Ki Ko, MD<sup>1</sup>, Young-Hwue Kim, MD<sup>1</sup>, Jeong Jin Yu, MD<sup>1</sup>, Jae-Kon Ko, MD<sup>1</sup>, In-Sook Park, MD<sup>1</sup>, Dong-Man Seo, MD<sup>2</sup>, Tae-Jin Yun, MD<sup>2</sup>, Jeong-Jun Park, MD<sup>2</sup>, and Wan Sook Jang, MS<sup>1</sup>

<sup>1</sup>Departments of Pediatric Cardiology and <sup>2</sup>Pediatric Cardiac Surgery, Ulsan of University College of Medicine, Asan Medical Center, Seoul, Korea

**Background and Objectives:** Pulmonary arterial stenosis is a relatively common complication after corrective operation of congenital heart disease. Unilateral stenosis of pulmonary arteries could result in decrease perfusion of affected lung, pulmonary regurgitation, or elevation of right ventricular pressure. Eventually there are increasing risks of right ventricular failure, arrhythmia, or sudden death. However we have limited data of pulmonary arterial stent in paediatric population as the treatment of branch pulmonary stenosis. This study aimed at validating the effectiveness and investigating complications of pulmonary arterial stent implantation in a single institution during mid-term follow up period.

**Subjects and Methods:** A total of 42 patients (50 stents) were implanted for treating branch pulmonary arterial stenosis. We used cardiac catheterization for comparing diameter after stent implantation directly and lung perfusion scan indirectly. We also investigated any adverse effect relating the procedure.

**Results:** Percent stenosis of stenotic lesions were decreased from  $54.1 \pm 10.7\%$  to  $22.8 \pm 12.5\%$  ( $p < 0.001$ ) and degree of decrement in affected lung perfusion was declined from  $22.7 \pm 8.0\%$  to  $10.3 \pm 9.0\%$  ( $p < 0.001$ ) immediately and lasts during mid-term follow up period. Complication rate relating the procedure was 12% (6 out of 12) and there was no mortality case.

**Conclusion:** This series showed immediate and short term effectiveness of pulmonary arterial stent in congenital heart defects. We concluded that percutaneous transcatheter implantation of pulmonary arterial stent was safe and effective during short and mid-term follow up period. (Korean Circ J 2012;42:40-45)

**KEY WORDS:** Congenital heart disease; Catheterization.

### Introduction

Pulmonary arterial stenosis is a relatively common complication after corrective surgery for congenital heart disease.<sup>1-3</sup> Branch pulmonary arterial stenosis develops at a high rate after the repair of

tetralogy of Fallot among the various congenital heart defects.<sup>4</sup> Uncorrected unilateral stenosis of pulmonary arteries could result in decreased perfusion of the affected lung, pulmonary regurgitation, or elevation of right ventricular pressure.<sup>5,6</sup> Treatment should be decided by assessing the patient's hemodynamic status regardless of the development of symptoms, because of the increasing risks of right ventricular failure, arrhythmia, or sudden death.<sup>7</sup> Improvement of right ventricular systolic function was reported in a swine model using cardiac magnetic resonance imaging (MRI) after relief of stenosis of the branch pulmonary artery.<sup>8</sup> However, there is limited clinical data for human species mainly due to the relatively small population of branch pulmonary artery stenosis patients.<sup>9</sup>

Stent implantation of pulmonary arteries for relief of stenotic lesions is still an 'off-label' procedure, although it has been a standardized therapy from the late 1980s.<sup>7</sup> That is not because of questions concerning its effectiveness and safety, but because of lack of interest among government and companies.<sup>10-12</sup> Although few stud-

**Received:** August 5, 2011

**Accepted:** September 21, 2011

**Correspondence:** Young-Hwue Kim, MD, Department of Pediatric Cardiology, Ulsan of University College of Medicine, Asan Medical Center, 88 Olympic-ro 43-gil, Songpa-gu, Seoul 138-736, Korea  
Tel: 82-2-3010-3386, Fax: 82-2-473-3725  
E-mail: yhkim@amc.seoul.kr

• The authors have no financial conflicts of interest.

This is an Open Access article distributed under the terms of the Creative Commons Attribution Non-Commercial License (<http://creativecommons.org/licenses/by-nc/3.0>) which permits unrestricted non-commercial use, distribution, and reproduction in any medium, provided the original work is properly cited.

ies had demonstrated a high success rate after 20 years of experience, there has not been any multicenter-randomized controlled study.<sup>9)13)14)</sup> This study aimed at validating the effectiveness and investigating complications of pulmonary arterial stent implantation in a single institution during midterm follow up period.<sup>15)16)</sup>

## Subjects and Methods

Between January 1999 and May 2010, patients with unilateral or bilateral pulmonary arterial stenosis after corrective surgery for their congenital heart defects were enrolled in the Department of Pediatric Cardiology at Asan Medical Center. Only patients who were implanted with pulmonary arterial stents were included. A total of 42 patients (50 stents) were implanted. The ratio of boys to girl was 0.92. At the time of implantation the patient median age was 12 years (range 0.5–31 years), and their median weight was 22 kg (range 4.8–80.4 kg). Site of lesions were right pulmonary arteries (n=6), left pulmonary arteries (n=28), and bilateral pulmonary arteries (n=8).

Patient medical records were retrospectively reviewed for demographic data such as age, weight, and height at intervention. For assessing the effectiveness data of catheterization, lung perfusion scan, or heart computed tomography (CT) scan and echocardiography were also collected before and after the intervention. Institutional review board of Asan Medical Centre approved this study and patient consent was waived.

### Catheterization

Pressure data and diameter of stenotic lesions were obtained before and after the implantation. Additionally, the percent stenosis (i.e., ratio of diameter at stenotic lesion to that of normal pulmonary artery at the level of helium) was calculated to compare the results. Indications of pulmonary arterial stent implantation were when lung perfusion ratio of the normal side to affected side was over 2.5 and when the right ventricular systolic pressure was over 50% of systemic systolic blood pressure.

### Percutaneous transcatheter implantation of pulmonary arterial stent

Measurement of the diameter of the stenotic lesion and ipsilateral pulmonary artery at the first-branching site helped choose the size and length of stent from angiography of pulmonary arteries with biplane fluoroscopy. Pre-mounted or hand-mounted stent was placed accurately at the stenotic lesion and dilated by inflating the balloon. In case of a hand-mounted stent, we made a so-called shoulder of balloon to prevent slippage of the stent during catheter manipulation.

Sometimes balloon angioplasty was tried first and the proximal part of the stent was widened after implantation, making it easier to pass through the stent subsequently. Bilateral stenosis was treated simultaneously by a double wire technique to minimize displacement of the stent from the optimal site (Figs. 1 and 2). We used various type of stents, including Jostent® peripheral (Abbott, Abbott Park, IL, USA), Palmaz® stent; P\*\*4/8/10B/ 14 series, XD (Johnson & Johnson-Cordis, Bridgewater, NJ, USA), Express® Vascular LD (Boston Scientific, Natick, MA, USA), and Wallflex® vascular stent (Boston Scientific).

### Lung perfusion scan

The geometric result of lung perfusion scan before and after implantation was investigated and then the decrement of perfusion was calculated by subtracting percent of affected side from that of normal value (left : right, 45% : 55%), which was calculated only in unilateral pulmonary arterial stenosis.

### Echocardiography and heart CT scan

The non-invasive methods of echocardiography and heart CT scan were used to supplementing the results of angiography.

### Statistical analyses

Data was analyzed using Statistical Package for the Social Sciences (SPSS) for Windows, version 12 (SPSS Inc., Chicago, IL, USA). Descriptive data for continuous variables are presented as mean±SD. Student's t-test was used for comparing the results before and after implantation. Pearson correlation coefficient was used to estimate correlation between percent stenosis and perfusion decrease. P<0.05 was considered statistically significant.

## Results

Demographic data of patients are shown in Table 1. Mean diameter of the narrowest point on pulmonary arterial stenosis was 6.6 mm and mean percent stenosis was 54%. Patients with tetralogy of Fallot with or without pulmonary atresia were most common, and consisted of part truncus arteriosus and pulmonary atresia with intact ventricular septum in order.

### Validation of effectiveness

The diameter of stenotic lesion after stent implantation increased significantly from mean 6.6 mm to mean 12.4 mm and the decrement of perfusion changed significantly from 22.7±8.0% to 10.3±9.0% (p<0.001) (Table 2). Changes of each patient in diameter and percent stenosis are presented in Fig. 3; an increase in diameter from 6.6±2.1 mm to 12.4±3.6 mm, and drop in percent stenosis from

54.1±10.7% to 22.8±12.5% ( $p<0.001$ ) were evident. Eight patients (10 stents) had angiography for suspected re-stenosis on follow-up study. Period after first intervention was median 4.5 years, age was median 15 year-old and weight was median 38.2 kilograms. Among the eight patients, only two patients demonstrated re-stenosis to be re-dilated by balloon; the final diameter of these patients was mean 12.8 mm. Change in percent stenosis was 22.7±12.4% after the first intervention to 26.8±14.5% at the second angiography, indicative of little growth of distal pulmonary

**Table 1.** Patient characteristics

Age at first intervention (years, range)	6.5	0.5-31
Weight at first intervention (kg, range)	21.8	4.8-80.4
Male (n, %)	23	54.8
PA stenosis (n, %)		
Left PA	28	67
Right PA	6	14
Both PAs	8	19
Diagnosis (n, %)		
TOF without pulmonary atresia	19	45.2
TOF with pulmonary atresia	9	21.4
Truncus arteriosus	3	7.1
PAIVS	2	4.7
Others	9	21.4

PA: pulmonary arteries, TOF: tetralogy of Fallot, PAIVS: pulmonary atresia with intact ventricular septum

**Table 2.** Effect of stent implantation

	Pre-stent	Post-stent	p
Minimal PA diameter (mm)	6.6±2.1	12.4±3.6	<0.001
Percent stenosis (%)	54.1±10.7	22.8±12.5	<0.001
Percent of decreased lung perfusion scan results (%)	22.7±8.0	10.3±9.0	<0.001

PA: pulmonary arteries

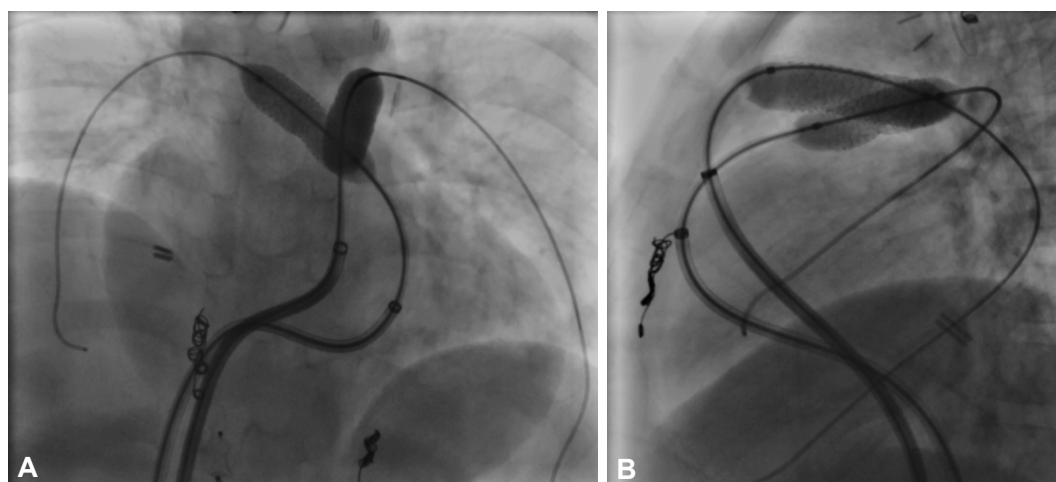
arteries after stent implantation.

### Assessment of safety

Overall complication rate related to the procedure was 12%. There was no mortality, but there were three cases of serious complications. The first was the perforation of a pulmonary artery to be repaired by stent graft in the implanted stent (Fig. 4A). The second was a hemothorax during the access to the neck vein for the indwelling chest tube. The third was a stent migration to the right ventricle destined for surgical removal and repair due to development of ventricular tachycardia. Other complications included two cases of stent displacement re-positioned by transcatheter manipulation. One was repositioned by snaring the migrating stent and the other case positioned the first-implanted stent at the contralateral pulmonary artery because of failure to reposition and to implant another stent at the original stenotic lesion. One stent fracture was found during follow-up, requiring the implantation of another stent in the fractured stent (Fig. 4B). Additionally, balloon rupture occurred in two cases during inflation.

### Discussion

This study showed that short-term result of pulmonary arterial stent implantation was effective in increasing the diameter and flow of treated pulmonary arteries. Although the long-term result

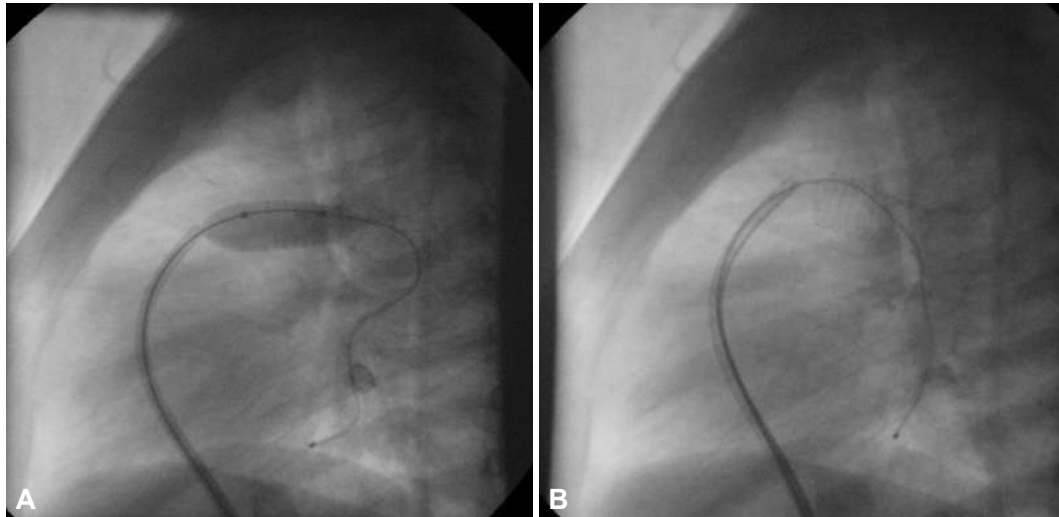


**Fig. 1.** Double wire technique in stenosis of both pulmonary arteries. This still frame image shows that two wires were located at both sides of pulmonary arteries for simultaneous ballooning of the stents. A: sit-up view. B: lateral view.

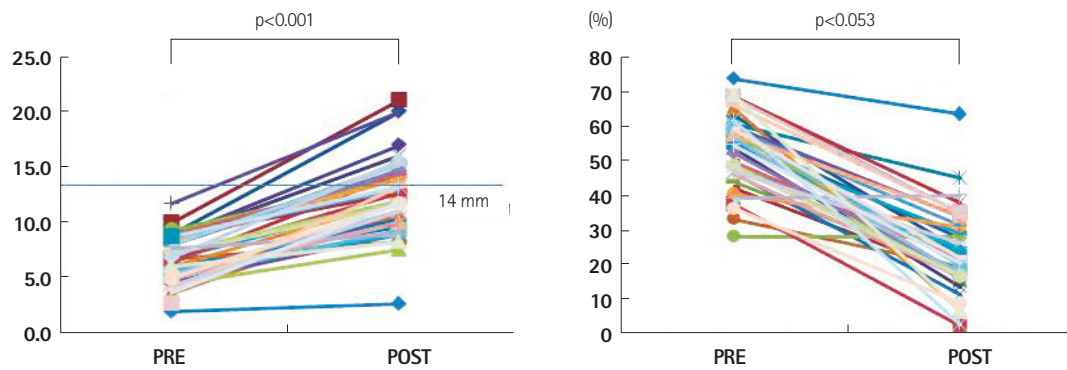
still needs to be clarified, follow-up catheterization showed that rate of re-stenosis and percent stenosis remained relatively low after intervention. However, dilatation over 14 mm, the normal typical pulmonary artery size of an adult, is potentially harmful to the vessel when

using over a 12 Fr sheath for delivering a bulky stent such as the Palmaz® genesis stent (Johnson & Johnson-Cordis, Bridgewater, NJ, USA).<sup>10)11)15)</sup>

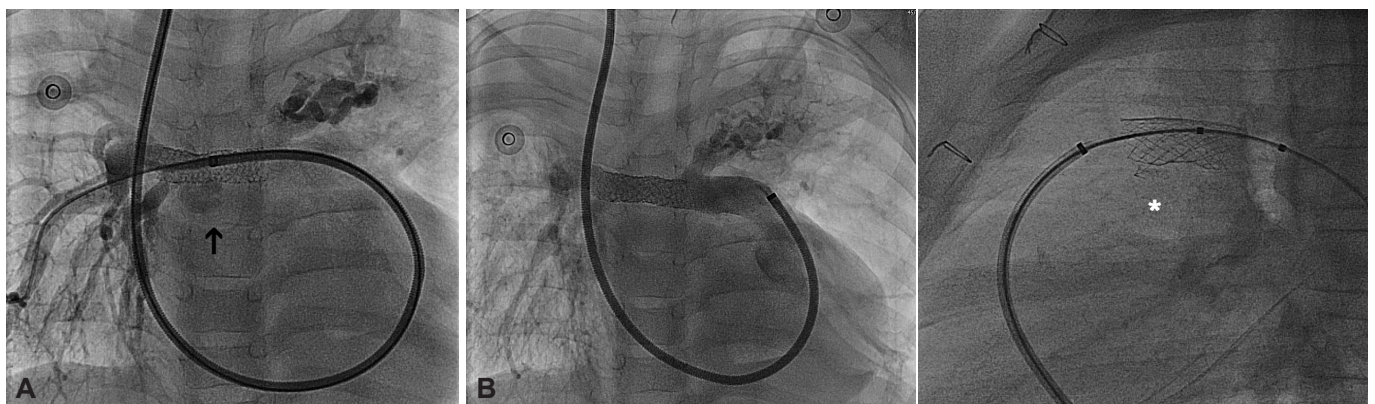Presently, there was no instance of mortality and the rate of com-



**Fig. 2.** Extra-balloon widening of proximal stent for easy-approach. This image showed ballooning (A) of proximal part of stent after implantation first, which made it easier and safer to access distal pulmonary artery next time. Wide opened stent is shown (B).



**Fig. 3.** Changes in diameter of pulmonary arterial stenosis and in percent stenosis. This represents increase of diameter in stenotic lesion and decrease of percent stenosis after stent implantation significantly among almost patients.



**Fig. 4.** Complications of implantation of pulmonary artery stent. A: after implanting stent vascular leakage was noted (left) then it was repaired by Jostent® Graft Master. After graft implantation within stent, no leakage was found on angiography (right). B: this showed that stent fracture at proximal part of stent was found during follow-up catheterization for evaluating re-stenosis of left pulmonary artery.

plications association with implantation was 12%, similar to the long-term reports of other studies.<sup>9)13)14)16)17)</sup> One study reported their long term result of pulmonary stent experiencing 9.1% of complication rate (six out of 55 stents) including one death related to procedure. The complication rate has decreased with the refinement/ development of equipments and skills.<sup>9)13)14)16)17)</sup>

After more than 20 years of pediatric stent implantation, this use of stents has not received Food and Drug Administration approval, which has necessitated the use of peripheral stents intended for adult patients (Jostent®, Genesis®, Wallflex®, and Express® stents). Additionally, Mega® LD or Maxi® LD stents, which prevent jailing vessel, Double stent® LD stent, which increases flexibility, and custom-built Cheatham-Platinum® (C-P) stent have been used in other countries.<sup>18)</sup> The maximal diameter of a stent is usually larger than recommended in spite of variable shortening in length. For example, the maximal diameter of the Express® stent is 12 mm and that of the Palmaz genesis® stent is over 20 mm.

The BIB® stent, which is not available in Korea, consists of an inner and outer balloon. This stent is useful for severe stenotic lesions of the large pulmonary artery, a location in which the usual balloon cannot resolve the stenosis, necessitating the implantation of a butterfly stent. BIB® has a two-step inflation process in which an inner small balloon relieves severe stenotic lesion first to avoid wrinkling of the stent, which could be a fixed stenosis.<sup>18)</sup>

Since we were unable to reach consensus on indication of stent implantation among centers, there are two considerations for the procedure: policy for jailed vessel and treatment time for patient age and physical condition. Treatment timing is changing to reflect device improvements and jailing vessel from stent implantation is contraindicated in our institution. Furthermore, accessibility and diversity of suitable stents is limited in many center.<sup>19)</sup>

Methods for detecting re-stenosis after stent implantation should be effective and safe. This study used a non-invasive method, lung perfusion scan, which showed a relationship between perfusion decrease and percent stenosis. However, patients having follow-up catheterization had decreased perfusion ratio but percent stenosis was not appreciably increased. This could be postulated to be due to the persistent increase of pulmonary resistance or diffuse stenosis of distal pulmonary artery without growth after stent implantation. Follow-up modalities used in other studies were mostly catheterization, and cardiac MRI. Lung perfusion scan lacks the ability to detect patency of a jailed vessel. However, we did not perform an implant when an adjacent vessel could be jailed if the stent was implanted.

This series showed immediate and short-term effectiveness of pulmonary arterial stent in congenital heart defects, which had a comparable result to surgical correction. However, we were limited

in validating the result of lung perfusion scan compared to data from catheterization because we performed only a limited number of cardiac catheterizations.

We conclude that transcatheter percutaneous implantation of pulmonary artery stent is safe and effective during short- and mid-term follow-up.

## REFERENCES

1. Mullins CE, O'Laughlin MP, Vick GW 3rd, et al. *Implantation of balloon-expandable intravascular grafts by catheterization in pulmonary arteries and systemic veins. Circulation 1988;77:188-99.*
2. Hellenbrand WE. *Transcatheter therapy for congenital heart disease. Cardiol Clin 1988;6:421-36.*
3. Rath PC, Sukumar IP. *Transcatheter therapy for congenital heart disease. J Assoc Physicians India 1986;34:199-201.*
4. Chaturvedi RR, Kilner PJ, White PA, Bishop A, Szwarc R, Redington AN. *Increased airway pressure and simulated branch pulmonary artery stenosis increase pulmonary regurgitation after repair of tetralogy of Fallot. Real-time analysis with a conductance catheter technique. Circulation 1997;95:643-9.*
5. Fogelman R, Nykanen D, Smallhorn JF, McCrindle BW, Freedom RM, Benson LN. *Endovascular stents in the pulmonary circulation: clinical impact on management and medium-term follow-up. Circulation 1995;92:881-5.*
6. Oyen WJ, van Oort AM, Tanke RB, van Mill GJ, Aengevaeren WR, Corstens FH. *Pulmonary perfusion after endovascular stenting of pulmonary artery stenosis. J Nucl Med 1995;36:2006-8.*
7. Latson LA. *Interventional catheterization for congenital heart disease--limited "surgery" without the chest scar. Clin Pediatr (Phila) 1997;36:125-7.*
8. Petit CJ, Gillespie MJ, Harris MA, et al. *Relief of branch pulmonary artery stenosis reduces pulmonary valve insufficiency in a swine model. J Thorac Cardiovasc Surg 2009;138:382-9.*
9. Law MA, Shamszad P, Nugent AW, et al. *Pulmonary artery stents: long-term follow-up. Catheter Cardiovasc Interv 2010;75:757-64.*
10. Recto MR, Elbl F, Austin E. *Use of the new IntraStent for treatment of transverse arch hypoplasia/coarctation of the aorta. Catheter Cardiovasc Interv 2001;53:499-503.*
11. Rutledge JM, Mullins CE, Nihill MR, Grifka RG, Vincent JA. *Initial experience with intratherapeutic IntraStent Doublestrut LD stents in patients with congenital heart defects. Catheter Cardiovasc Interv 2002;56:541-8.*
12. Latson LA. *Pulmonary artery stents: on target, but still "off label". Catheter Cardiovasc Interv 2010;75:765-6.*
13. Moszura T, Michalak KW, Dryzek P, Moll JA, Moll J, Sysa A. *One center experience in pulmonary artery stenting without long vas-*

- cular sheath. Cardiol J 2010;17:149-56.*
14. Tomita H, Nakanishi T, Hamaoka K, Kobayashi T, Ono Y. *Stenting in congenital heart disease: medium- and long-term outcomes from the JPIC stent survey. Circ J 2010;74:1676-83.*
  15. Forbes TJ, Rodriguez-Cruz E, Amin Z, et al. *The Genesis stent: a new low-profile stent for use in infants, children, and adults with congenital heart disease. Catheter Cardiovasc Interv 2003;59:406-14.*
  16. Breinholt JP, Nugent AW, Law MA, Justino H, Mullins CE, Ing FF. *Stent fractures in congenital heart disease. Catheter Cardiovasc Interv 2008;72:977-82.*
  17. Ashwath R, Gruenstein D, Siwik E. *Percutaneous stent placement in children weighing less than 10 kilograms. Pediatr Cardiol 2008;29:562-7.*
  18. Li F, Zhou AQ, Gao W, et al. *Therapeutic effect of Cheatham-Platinum stent implantation for vessel stenosis associated with congenital heart disease in children and adolescents. Zhonghua Er Ke Za Zhi 2009;47:255-9.*
  19. Maglione J, Bergersen L, Lock JE, McElhinney DB. *Ultra-high-pressure balloon angioplasty for treatment of resistant stenoses within or adjacent to previously implanted pulmonary arterial stents. Circ Cardiovasc Interv 2009;2:52-8.*