

# Endovascular repair of an innominate artery pseudoaneurysm using the Valiant Mona LSA branched graft device

Josh A. Sibille, MD, Joel P. Harding, BS, Jocelyn K. Ballast, BA, Mohammad Hooshmand, BS, Jeko M. Madjarov, MD, and Frank R. Arko III, MD, *Charlotte, NC*

A 60-year-old woman involved in a motor vehicle collision presented with a traumatic pseudoaneurysm of the innominate artery origin in addition to multiple concomitant injuries. She was classified as a high-risk candidate for open repair. An experimental thoracic branched graft device was used for coverage of the injury with the addition of a right carotid-to-left carotid-to-left subclavian artery bypass. Follow-up imaging showed resolution of the pseudoaneurysm and patency of her bypass grafts. This is the first described use of the Mona LSA Branch Thoracic Stent Graft System (Medtronic, Minneapolis, Minn) in the innominate artery. (*J Vasc Surg Cases and Innovative Techniques* 2017;3:1-3.)

Traumatic injury to the aortic arch and great vessels has traditionally required open operative repair.<sup>1</sup> Recent advancements in endovascular techniques and devices have allowed less invasive repairs to be performed. Several authors have shown hybrid procedures have a lower morbidity and mortality in patients requiring supra-aortic intervention, especially in patients who would be poor candidates for open repair.<sup>2,3</sup> Furthermore, a retrospective study at the University of Washington highlighted that pseudoaneurysm formation from blunt trauma can be treated with endovascular repair and that short-term outcomes with less invasive measures have more favorable results.<sup>4</sup> However, this study focused on the use of thoracic endovascular aortic repair for traumatic transection of the innominate artery at the base of the transverse arch.

We present a patient with traumatic injury to the innominate artery with pseudoaneurysm formation treated with a branched endograft. A Mona LSA Branch Thoracic Stent Graft System (Medtronic, Minneapolis, Minn) branched endograft was used to repair the injury to the innominate artery with concomitant revascularization of the distal arch vessels. This was done on a compassionate-use basis with approval from the United States Food and Drug Administration and our Institutional Review Board. Consent was obtained from the patient and her family for the procedure and this publication via our facility's general consent form.

This graft was selected because the patient was considered too high risk for cardiopulmonary bypass due to subarachnoid and subdural hematomas as well as recent spinal fusion related to her injuries. The Mona LSA is a branched thoracic endograft designed to allow proximal extension beyond the left subclavian artery without need for revascularization. Early outcomes of the Mona LSA stent graft have been promising.<sup>5</sup> We felt this was a reasonable treatment given the patient's anatomy and our familiarity with this single branch graft device.

## CASE REPORT

A 60-year-old woman presented after a motor vehicle collision with a traumatic injury to the origin of the innominate artery with pseudoaneurysm formation. Additional injuries included a femur fracture, bilateral subdural and subarachnoid hemorrhages, C4 and C5 fractures, and a spinal cord contusion resulting in lower extremity paralysis. The patient had a history of cerebral palsy and a previously placed ventriculoperitoneal shunt. She was admitted to the surgical intensive care unit. The long-bone fractures and cervical spine fractures were surgically stabilized and repaired. Extensive discussions were held with the patient and her family regarding the treatment of her innominate injury.

Imaging of the chest showed a 1.3-cm × 0.8-cm pseudoaneurysm arising from the posterior portion of the innominate artery (Fig 1). She was also noted to have a bovine arch variant with the innominate and left carotid arteries sharing a common origin. The innominate artery measured 12.5 mm at its origin, and the proximal thoracic aorta measured 27.5 mm. The patient was treated conservatively for 14 days with anti-impulse therapy. Repeat computed tomography angiography of the chest at 2 weeks demonstrated enlargement of the pseudoaneurysm by 5 mm with continued chest discomfort.

At the time of the procedure, the patient underwent right carotid-to-left subclavian bypass with left carotid transposition using an 8-mm polytetrafluoroethylene graft. The proximal left carotid stump was ligated as well. The branched graft was then deployed in the aortic arch with branch graft placement into the innominate artery. We did not coil the left subclavian

---

From the Department of Vascular Surgery, Sanger Heart and Vascular Institute. Author conflict of interest: none.

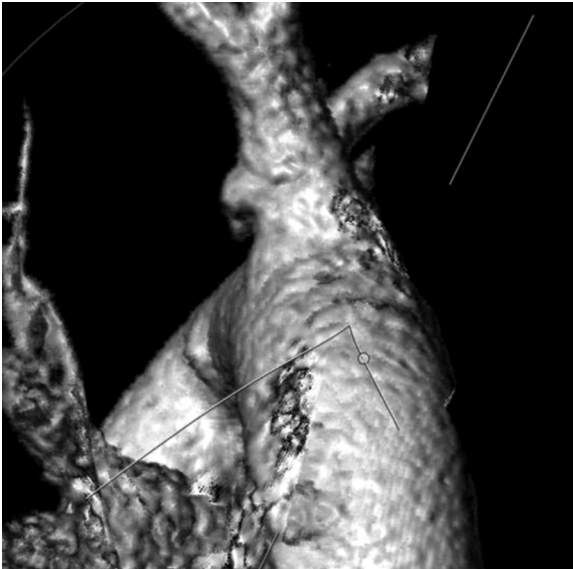
Correspondence: Frank R. Arko III, MD, Department of Vascular Surgery, Sanger Heart and Vascular Institute, 1001 Blythe Blvd, Charlotte, NC 28203 (e-mail: [farkomd@gmail.com](mailto:farkomd@gmail.com)).

The editors and reviewers of this article have no relevant financial relationships to disclose per the Journal policy that requires reviewers to decline review of any manuscript for which they may have a conflict of interest.

2468-4287

© 2016 The Authors. Published by Elsevier Inc. on behalf of Society for Vascular Surgery. This is an open access article under the CC BY-NC-ND license (<http://creativecommons.org/licenses/by-nc-nd/4.0/>).

<http://dx.doi.org/10.1016/j.jvscit.2016.09.009>



**Fig 1.** A three-dimensional reconstruction of a computed tomography image shows the innominate pseudoaneurysm.

artery because the thoracic aorta was normal and we had excellent seal at the level of the subclavian.

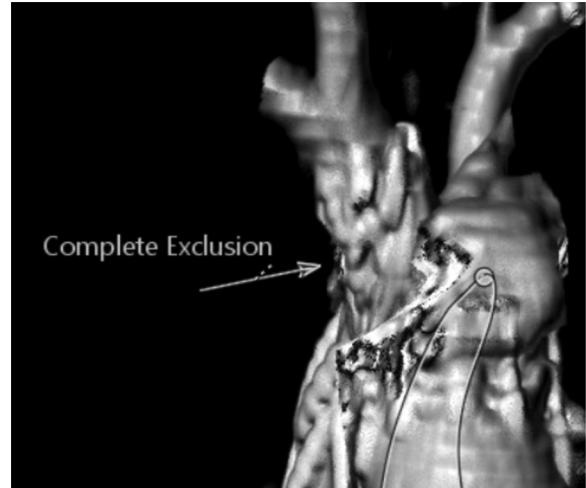
A 30-mm × 30-mm × 150-mm Mona LSA device with a 14-mm × 14-mm × 40-mm branch was used to cover the injury of the vessel. The distance from the origin of the innominate artery to the bifurcation of right subclavian and carotid arteries was 35 mm. Because of this distance, we kept the 14-mm branch graft hanging into the aorta ~10 mm. The Mona LSA is a two-wired system for precannulation of the branch. It is currently in clinical trials in the United States and Europe, with a planned indication of treatment of aneurysm, dissection, and penetrating aortic ulcer.<sup>5</sup>

The patient recovered uneventfully from the procedure and has been maintained on oral antiplatelet therapy after clearance from neurosurgery. She was discharged to a rehabilitation facility for rehabilitation of her spinal cord injury on postoperative day 16.

Follow-up imaging at 3 months showed resolution of the pseudoaneurysm and patency of all arch vessel bypasses. There was also complete occlusion of the proximal left common carotid artery and proximal left subclavian artery (Fig 2). The patient has continued to recover from her neurologic injuries, is walking with assistance, and is fully awake and alert to her baseline.

## DISCUSSION

With current improvements in endovascular devices, as well as increasing physician technical skill in performing complex endovascular procedures, there is a growing trend to treat more complex cases in an endovascular fashion. Lioupis et al<sup>6</sup> have a small series using custom thoracic multibranch grafts to repair thoracic aneurysms. They successfully placed four of six thoracic branched grafts with total arch coverage. Murphy et al<sup>7</sup> have also



**Fig 2.** Follow-up imaging at 3 months shows resolution of the pseudoaneurysm (arrow).

reported placement of a physician-modified device with innominate branching for repair of an ascending aortic aneurysm. Several studies have shown the feasibility and safety of branched endografts in the proximal aortic branches.<sup>8-10</sup> These studies have evaluated the treatment of aneurysm and dissections. No study to date has evaluated the use of branched endografts in the proximal aorta and its branches in the treatment of traumatic injuries. Post-traumatic lesions of the innominate artery are best suited for endovascular repair because of the focal nature of the lesion in an otherwise nondiseased artery.<sup>11,12</sup>

As new developments in endovascular devices become available, the ability to treat complex disease processes becomes more common. This case shows the feasibility of the branched graft technique for traumatic injury to the arch vessels. The use of the Mona LSA graft would also provide an off-the-shelf solution to complex aortic pathology. As a single branch system, if it is used for the innominate artery, then revascularization of the left carotid would be mandatory. Revascularization of the left subclavian artery would be up to the physician's discretion; however, we prefer to revascularize the left subclavian artery in the urgent and elective settings.

## CONCLUSIONS

The adaptability and usefulness of the Mona LSA stent graft in this patient showcases its flexibility in the treatment of pathology in the aortic arch. Larger studies are still needed to solidify target populations for this interventional modality. Long-term studies of the Mona LSA showing efficacy over open repair are currently lacking, but short-term outcomes thus far have been promising, and its use in the innominate artery as a single-branch system is feasible.

## REFERENCES

1. Sladojevic M, Markovic M, Ilic N, Pejkić S, Banzic I, Djoric P, et al. Open treatment of blunt injuries of supra aortic branches: case series. *Ann Vasc Surg* 2016;31:205. e5-10.
2. Eckhauser A, Hannon D, Molitor M, Scaife E, Gruber P. Repair of traumatic aortoinnominate disruption using CorMatrix. *Ann Thorac Surg* 2013;95:e99-101.
3. Canaud L, Hireche K, Berthet J, Branchereau P, Marty-Ane C, Alric P. Endovascular repair of aortic arch lesions in high-risk patients or after previous aortic surgery: midterm results. *J Thorac Cardiovasc Surg* 2010;140:52-8.
4. Starnes B, Lundgren R, Gunn M, Quade S, Hatsukami T, Tran N, et al. A new classification scheme for treating blunt aortic injury. *J Vasc Surg* 2012;55:47-54.
5. Roselli E, Arko F, Thompson M. Results of the Valiant Mona LSA early feasibility study for descending thoracic aneurysms. *J Vasc Surg* 2015;62:1465-71.
6. Lioupis C, Corriveau M, MacKenzie K, Obrand D, Steinmetz O, Abraham C. Treatment of aortic arch aneurysms with a modular transfemoral multibranch stent graft: initial experience. *Eur J Vasc Endovasc Surg* 2012;43: 525-32.
7. Murphy E, Dimaio J, Jessen M, Arko F. Technique for branched thoracic stent-graft repair of a chronic type a aortic dissection in a patient with multiple prior sternotomies. *J Endovasc Ther* 2011;18:359-64.
8. Tsilimparis N, Debus E, Yskert K, Wipper S, Rohlfs F, Detter C, et al. Branched vs. fenestrated endografts for endovascular repair of aortic arch lesions. *J Vasc Surg* 2016;64:592-9.
9. Patel H, Dake M, Bavaria J, Singh M, Filinger M, Fischbein M, et al. Branched endovascular therapy of distal aortic arch: preliminary results of the feasibility multicenter trial of the Gore thoracic branch endoprosthesis. *Ann Thorac Surg* 2016;16:30226-30.
10. Spear R, Haulon S, Okhi T, Tsilimparis N, Kancake Y, Milne C, et al. Editors choice - subsequent results for arch aneurysm repair with inner branched endografts. *Eur J Vasc Endovasc Surg* 2016;51:380-5.
11. Puech-Leão P, Orra H. Endovascular repair of an innominate artery true aneurysm. *J Endovasc Ther* 2001;8:429-32.
12. Axisa B, Loftus I, Fishwick G, Spyt T, Bell P. Endovascular repair of an innominate artery false aneurysm following blunt trauma. *J Endovasc Ther* 2000;7:245-50.

Submitted Jul 7, 2016; accepted Sep 26, 2016.