

# Intractable otitis media as a diagnostic clue to antineutrophil cytoplasmic antibody-associated vasculitis

Yukiko Ishikawa MD<sup>1</sup> | Koichi Takeda MD<sup>2</sup> | Yoichiro Akiyama MD<sup>2</sup> | Masami Matsumura MD<sup>1</sup>

<sup>1</sup>Division of General Internal Medicine, Jichi Medical University Hospital, Shimotsuke, Japan

<sup>2</sup>Division of Rheumatology and Clinical Immunology, Department of Medicine, Jichi Medical University, Shimotsuke, Japan

## Correspondence

Yukiko Ishikawa, Division of General Internal Medicine, Jichi Medical University Hospital, Shimotsuke, Tochigi, Japan.  
Email: yuishi@jichi.ac.jp

## Abstract

Antineutrophil cytoplasmic antibody-associated vasculitis (AAV) presents a variety of manifestations. Two patients with a history of intractable otitis media were diagnosed as having AAV. One was an 87-year-old woman who presented with cough, anorexia, and fever with a one-year and four-month history of otitis media, and the other was a 65-year-old woman with arthritis that appeared after the diagnosis of otitis media. The history of otitis media was a diagnostic clue to AAV in both patients. Diagnosis at the early localized stage is crucial to prevent irreversible status of AAV. Primary care physicians should be aware of the otological manifestation of AAV.

## KEYWORDS

antineutrophil cytoplasmic antibody, otitis media, vasculitis

## 1 | INTRODUCTION

Antineutrophil cytoplasmic antibody (ANCA)-associated vasculitis (AAV) can present a variety of clinical symptoms. Diagnosis at the early localized stage of AAV is crucial for improving the patient's prognosis. In our general internal medicine outpatient practice, two patients with a history of intractable otitis media were diagnosed as having AAV. One patient who had cough, anorexia, and fever with a one-year and four-month history of otitis media was diagnosed with microscopic polyangiitis (MPA). The other patient with arthritis which appeared after the onset of right ear fullness was diagnosed with granulomatosis with polyangiitis (GPA).

We reported two cases of AAV. A history of intractable otitis media was a clue to the diagnosis of AAV in the outpatient care setting.

## 2 | CASE REPORTS

### 2.1 | Case 1

An 87-year-old woman had been in good health until one and a half years before when coughing, bilateral ear fullness, and hearing

impairment appeared. She consulted a pulmonary medicine office. Idiopathic pulmonary fibrosis (IPF) was diagnosed from the chest computed tomography (CT) findings. She was followed without treatment. Two months later, she consulted an otolaryngologist and was diagnosed with bilateral otitis media. She was treated with medications and received bilateral myringotomies, but the otitis media remained refractory. Four weeks earlier, nocturnal cough and anorexia had appeared. She consulted a community hospital. Blood tests disclosed a leukocyte count of 11 300/ $\mu$ L, hemoglobin 8.3 g/dL, and creatinine 0.56 mg/dL. Chest CT scan showed no change of IPF. Garenoxacin at a dose of 200 mg per day was prescribed for 7 days without improvement. Five days before, low-grade fever appeared. She was referred to our division. Past myringotomies were observed in both tympanic membranes. Late inspiratory fine crackles were heard at the base of the lungs. AAV was strongly suspected from the history, especially intractable otitis media. Laboratory values were as follows: leukocyte count 11 800/ $\mu$ L; hemoglobin 8.8 g/dL; platelet count 373 000/ $\mu$ L; aspartate aminotransferase (AST) 18 IU/L; alanine aminotransferase (ALT) 12 IU/L; creatinine 0.52 mg/dL; CRP 6.2 mg/dL; and erythrocyte sedimentation ratio (ESR) 85 mm/h. Urinalysis disclosed trace hematuria and no proteinuria. Myeloperoxidase (MPO)-ANCA was

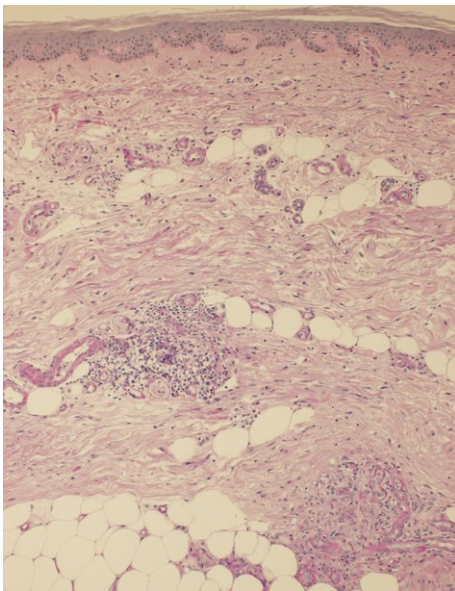
This is an open access article under the terms of the Creative Commons Attribution-NonCommercial License, which permits use, distribution and reproduction in any medium, provided the original work is properly cited and is not used for commercial purposes.

© 2017 The Authors. *Journal of General and Family Medicine* published by John Wiley & Sons Australia, Ltd on behalf of Japan Primary Care Association.

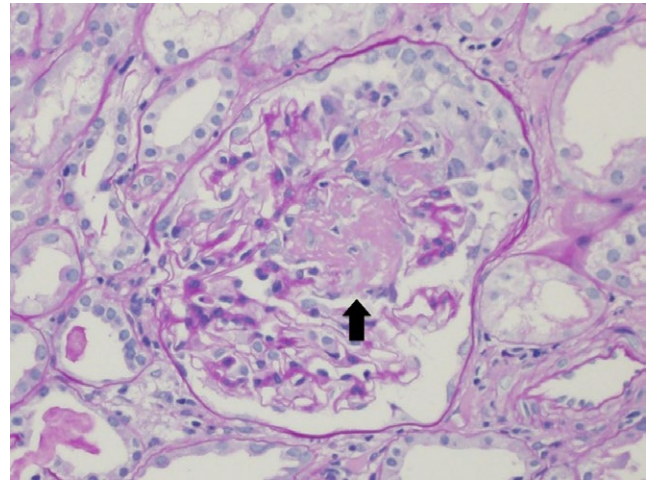
positive at 43.5 U/mL. Proteinase 3 (PR3)-ANCA was negative. She was admitted to the division of rheumatology for examination. On admission, livedo reticularis was observed in both legs. Skin biopsy of the lesion showed leukocytoclastic vasculitis without fibrinoid necrosis in small arteries and veins located in the dermis and subcutaneous tissue (Figure 1). She was diagnosed with MPA. Oral prednisolone at a dose of 20 mg per day was administered, and all symptoms including otitis media improved markedly.

## 2.2 | Case 2

A 65-year-old woman had been well until 5 months before admission when right ear fullness appeared. She consulted an otolaryngologist. However, her symptom did not improve in spite of treatment. Six weeks before, she visited another otolaryngologist. A tympanostomy tube was inserted for right otitis media with effusion. Five weeks before, the right second and third metacarpophalangeal (MCP) joints were swollen for 4 days. Soon after this sign ameliorated, the left second and third MCP joints were also swollen for 4 days. Four weeks before, she noticed swelling in the bilateral third, fourth, and fifth metatarsophalangeal joints for 4 days. She consulted an orthopedist. Blood test disclosed CRP 8.3 mg/dL, and hand X-ray showed no abnormality. Five days before, right pleuritic chest pain appeared. She consulted a local hospital. Electrocardiogram and chest X-ray showed no abnormality. Acetaminophen was prescribed with improvement. She was referred to our division. Right episcleritis and right ankle arthritis were observed. The physician strongly suspected AAV from the history of intractable otitis media followed by arthritis. Laboratory values were as follows: leukocyte count 8900/ $\mu$ L; hemoglobin 10.8 g/dL; platelet count 444 000/ $\mu$ L; AST 17 IU/L; ALT 15 IU/L; creatinine 0.58 mg/dL; CRP 7.6 mg/dL; and ESR 85 mm/h. Urinalysis showed 1+



**FIGURE 1** Skin biopsy showed leukocytoclastic vasculitis without fibrinoid necrosis in small arteries and veins located in the dermis and subcutaneous tissue (Periodic acid Schiff staining,  $\times 100$ )



**FIGURE 2** Renal biopsy showed segmental fibrinoid exudate with necrosis (arrow; Periodic acid Schiff staining,  $\times 400$ )

proteinuria and 3+ hematuria. Urine sediment disclosed red blood cells (20-29/HPF), and granular casts (1-4/HPF). MPO-ANCA was negative. However, PR3-ANCA level was high at 263 U/mL. Chest CT showed no abnormality. She was admitted to the division of rheumatology. On admission, bilateral episcleritis was noted. Renal biopsy was performed and included 14 glomeruli. One glomerulus showed segmental fibrinoid exudate with necrosis (Figure 2). Two glomeruli disclosed global sclerosis. Immunofluorescence of glomeruli showed negative results. She was diagnosed with GPA. Oral prednisolone at a dose of 50 mg per day and methotrexate at a dose of 6 mg per week were administered. Symptoms and abnormalities of urinalysis had improved completely.

## 3 | DISCUSSION

Herein, we report two cases of AAV. One was MPA, and the other was GPA. A history of intractable otitis media was a clue to the diagnosis in both cases.

The frequency of ear, nose, and throat symptoms is 90% for GPA vs 35% for MPA.<sup>1,2</sup> Although otological symptoms are common in systemic AAV, identification of localized AAV patients who initially present only otological symptom is challenging.<sup>3,4</sup> A group of patients who has intractable otitis media or recurrent sensorineural hearing loss despite steroid administration and occasionally accompanied with facial nerve palsy or hypertrophic pachymeningitis with high ANCA titers were proposed as having otitis media with AAV.<sup>5</sup> PR3-ANCA positive otitis media causes granulomatous formation or middle ear effusion, and MPO-ANCA positive otitis media predominantly presents as otitis media with effusion.<sup>5</sup> Holle et al. reported that 10% of localized AAV developed a systemic AAV on long-term follow-up.<sup>6</sup> Prompt diagnosis and treatment are essential to prevent critical organ damage, such as renal dysfunction, pulmonary hemorrhage, or respiratory failure in patients with systemic AAV.<sup>3</sup> Effectiveness of the combination therapy of corticosteroid and cyclophosphamide or methotrexate has been reported.<sup>7,8</sup>

Patients with AAV can manifest a variety of symptoms, such as fever, flu-like syndrome, malaise, anorexia, weight loss, myalgias, arthritis, purpura, numbness in extremities, or hemoptysis. General physicians should be familiar with the clinical manifestations of AAV. If AAV is one of the differentials in those patients, clarification of the otological symptoms may contribute to the diagnosis of AAV, especially in the early localized stage. Our role is to diagnose AAV promptly in the early stage and to refer the patient to a specialist to prevent irreversible organ damage.

#### ACKNOWLEDGEMENT

We thank John Gelblum for his critical reading of the manuscript.

#### CONFLICT OF INTEREST

The authors have stated explicitly that there are no conflicts of interest in connection with this article.

#### REFERENCES

1. Jennette JC, Falk RJ. Small-vessel vasculitis. *N Engl J Med*. 1997;337:1512–23.
2. Seo P, Stone JH. The antineutrophil cytoplasmic antibody-associated vasculitides. *Am J Med*. 2004;117:39–50.
3. Wierzbicka M, Szyfter W, Puszczewicz M, Borucki L, Bartochowska A. Otologic symptoms as initial manifestation of Wegener granulomatosis: diagnostic dilemma. *Otol Neurotol*. 2011;32:996–1000.
4. Mueller A, Holl-Ulrich K, Gross WL. Granuloma in ANCA-associated vasculitides: another reason to distinguish between syndromes? *Curr Rheumatol Rep*. 2013;15:376.
5. Yoshida N, Iino Y. Pathogenesis and diagnosis of otitis media with ANCA-associated vasculitis. *Allergol Int*. 2014;63:523–32.
6. Holle JU, Gross WL, Holl-Ulrich K, et al. Prospective long-term follow-up of patients with localized Wegener's granulomatosis: does it occur as persistent disease stage? *Ann Rheum Dis*. 2010;69:1934–9.
7. Mukhtyar C, Guillevin L, Cid MC, et al. EULAR recommendations for the management of primary small and medium vessel vasculitis. *Ann Rheum Dis*. 2009;68:310–7.
8. Hoffman GS, Kerr GS, Leavitt RY, et al. Wegener granulomatosis: an analysis of 158 patients. *Ann Intern Med*. 1992;116:488–98.

**How to cite this article:** Ishikawa Y, Takeda K, Akiyama Y, Matsumura M. Intractable otitis media as a diagnostic clue to antineutrophil cytoplasmic antibody-associated vasculitis. *J Gen Fam Med*. 2017;18:279–281. <https://doi.org/10.1002/jgf2.67>