

The simplest method to classify CAM lesions

Ricci Plastow*, Zuned Hakim, Max Fehily and Alun Wall

The Royal Bolton Hospital, Minerva Road, Bolton, UK

*Correspondence to: R. Plastow. E-mail: ricciplastow@doctors.org.uk

Submitted 13 February 2016; Revised 5 July 2016; revised version accepted 1 August 2016

ABSTRACT

CAM lesions are now seen as a significant pathology that could cause osteoarthritis of the hip joint. Currently there is no gold standard for classifying these lesions. We aim to show a simple method for classifying these lesions based on shape and position. Using CT 3D reconstruction, 91 preoperative CT scans from patients who had undergone hip arthroscopy for femoroacetabular impingement, were reconstructed to produce 3D images. Two senior hip surgeons have devised a simple four type classification system from previous experience. The system highlights the position and shape of different CAM lesions present in patients. The two senior surgeons and one junior surgeon reviewed the scans individually to assess whether the system could be used at all levels of surgical experience. The two senior surgeons agreed on which type of CAM lesion was present in all 91 cases. Intra observer reliability scores for the senior surgeons were 0.90 and 0.91. The junior surgeon reviewed the scans and disagreed on eight cases. This gave a Kappa co-efficient score of 0.87, which confirms a reliable system. We believe this classification system is simple and reproducible. It will aid surgeons in pre and intra-operative management of CAM lesions. Surgeons will be able to select the optimal portal placement and resect less capsule depending on the exact CAM lesion identified. This will potentially reduce complications and improve outcomes in junior hip arthroscopy surgeons.

INTRODUCTION

Femoroacetabular impingement (FAI) is an established cause of hip pain and is a possible cause of developing osteoarthritis in the hip [1, 2]. CAM and Pincer deformities have been described in the orthopedic literature as two separate entities of hip impingement [3, 4]. The CAM deformity has been described as a pistol grip deformity by Stulberg *et al.* [5], occurring at the head/neck junction. Damage to the acetabular chondral surface from these deformities has been graded [3, 6–7], but the position and size of the CAM lesion has been poorly classified. Current literature has used the alpha angle as a measurement of the deformity [4–10], but it has been criticised for its inaccuracy [11]. Notzli *et al.* introduced this angle in 2002 [7] but they used MR as the imaging modality. The majority of surgeons have since used X-Rays, rather than MR scan to measure this angle. Figure 1 shows how the alpha angle is measured on the AP hip radiograph. Lateral hip radiographs can also be used. It cannot be completely understood from one image and one angle. The majority of CAM lesions lie in the anterosuperior head neck junction, but studies have shown they appear more anteriorly also [12, 13].

Barton *et al.* [11] showed AP radiographs had only 60% sensitivity for identifying CAM lesions compared with MR scan.

The use of 3D CT scanning has enabled the CAM lesion to be accurately visualised [10, 13] and it has shown considerable variation in its morphology.

The aim of this study was to map the position of CAM lesions using preoperative 3D CT reconstructions and validate a four type classification that has been created by the authors of this article. Surgeons could then use this system in clinic to aid preoperative surgical planning. The two senior authors created the classification system from previous experience with preoperative 3D CT reconstruction images for FAI. They have over 5 years of experience in hip arthroscopy between them. They have performed over 500 arthroscopies collectively. They believe all patients fall into these four types. This classification system incorporates different shaped CAM lesions, with varying positions on the femoral head and neck. It does not quantify the size of lesion but this can be produced with computer programs if needed. We believe this system would improve surgeons planning of CAM resection over the basic alpha angle measurement.

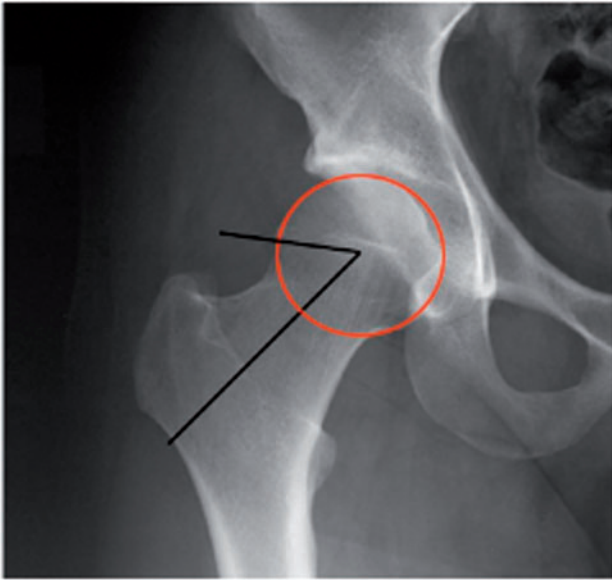


Fig. 1. Alpha angle measurement using AP hip radiograph.

Hip arthroscopy is a technically difficult procedure with studies proving experience affects surgical outcomes and complication rates [14, 15]. Larson and Giveans predicted a 30% increase in Hip arthroscopy between 2008 and 2014 [16]. If this is true then we must suspect that surgeons with limited experience are starting to undertake this procedure. The worry is that complications and revision rates will rise. The main reason for revision hip arthroscopy currently is failure to correct the femoral head neck offset [17, 18]. Giving surgeons as much information as possible will help to keep these revision rates down. By classifying the lesion preoperatively, the surgeon can reduce the number of portal placements and damage as little capsule and soft tissue as possible. Bony resection will be more focussed on correcting the head neck offset. These factors could potentially reduce complications and improve outcomes for junior hip arthroscopy surgeons.

PATIENTS AND METHODS

Between 2011 and 2012, 83 consecutive patients (36 male, 47 female), who underwent arthroscopic surgery for FAI, were entered into the study. 91 hips were classified. The patient's average age was 40 years (range 17–58). Each patient had undergone a CT scan of the affected hip, which was reconstructed to produce a three dimensional image of the joint. The senior surgeons carried out the process using the local radiology 3D reconstruction system. The Siemens 40 slice GE Computerized Tomography scanner with Leonardo reformatting software was used. This allows the femur to be rotated 360°.

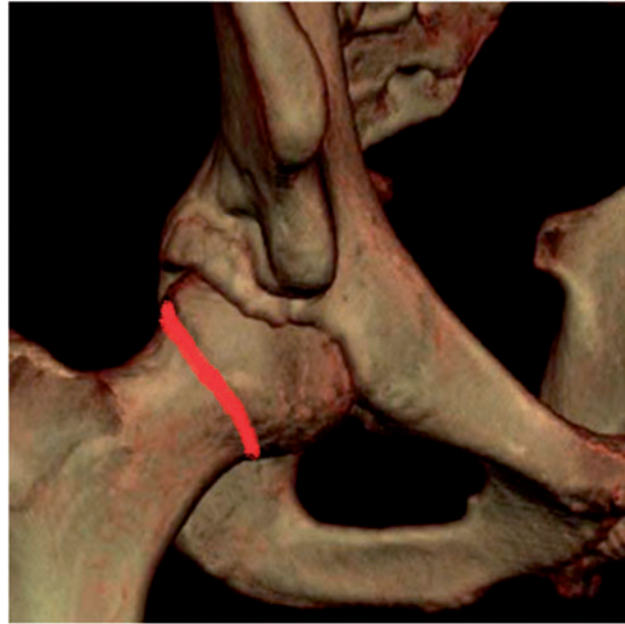

Fig. 2. AP view of hip joint. The red line shows the femoral head neck junction. If the lesion crosses this red line from the neck into the head then it must be the anterolateral head neck lesion or anterior head neck junction lesion. It cannot be the anterolateral neck or anterior neck lesion.

Below is the four type classification system used:

- i. Anterolateral head neck
- ii. Anterolateral neck
- iii. Anterior neck
- iv. Anterior head neck junction

The reviewers looked at AP and lateral images of the 3D reconstruction to decide which lesion was present. Anterolateral head neck or anterolateral neck lesions are seen on both the AP and Lateral views. Anterior head neck junction and anterior neck lesions can only be seen on the AP views. Figures 2 and 3 help explain the difference between the four lesions.

Figures 4–9 show the four types of CAM lesion identified and how they appear on the two views.

Each 3D CT scan was independently reviewed by the two senior surgeons and then by a junior surgeon. The junior surgeon had no experience in hip arthroscopy surgery or interpreting 3D CT scans before the study. He was given a 15-min tutorial to help classify the CAM lesions. All were blinded to the patient's identity, clinical examination and diagnosis. They were also blinded to the other reviewer's results. They had access to the images above to aid classification. Two weeks later all three reviewers classified the scans again to produce intra-observer reliability scores.

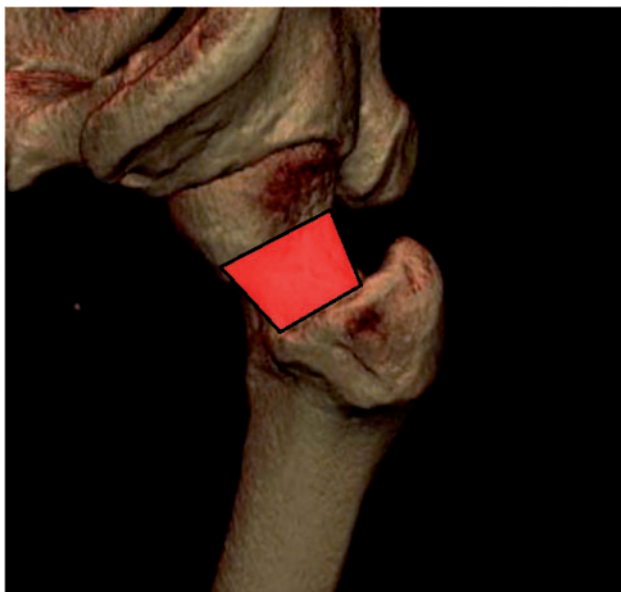


Fig. 3. 3D CT lateral view of hip. If the lesion is seen on the lateral view in the neck region (red rectangle) then it must be either the anterolateral head neck type or the anterolateral neck type. If a lesion is not present in the red rectangle it must be either the anterior head neck junction lesion or anterior neck lesion only.

The Cohen kappa coefficient value was calculated to assess the reliability of our classification system. This score is used instead of simple percentages for agreement between reviewers, because it takes into account the element of chance agreement. The score of 1.0 suggests perfect agreement between all reviewers.

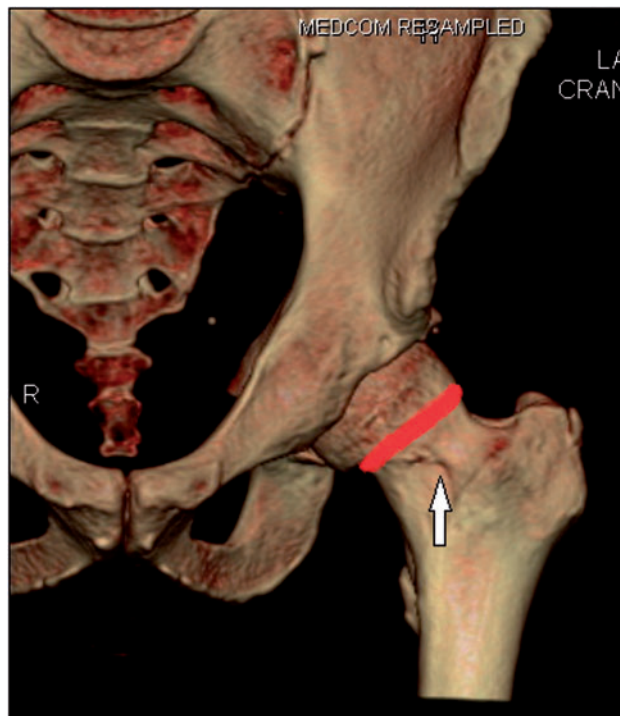
RESULTS

Table I shows significantly more females had the anterior neck lesion ($P = 0.022$), whereas significantly more males had the anterolateral head neck lesion ($P = 0.001$). No CAM lesion was found in significantly more females than males ($P = 0.002$). There were no significant differences between males and females in the presence of the anterior head neck junction lesion and the anterolateral neck lesion ($P = 0.613$ and 0.711 , respectively).

Intra and inter-observer kappa co-efficient scores

There were no differences noted between the two senior surgeons when classifying the CT 3D reconstruction scans. They agreed on all 91 hips, which gave a theoretical perfect kappa co-efficient score of 1.

The junior surgeon disagreed on eight scans compared with the senior surgeons. The kappa co-efficient score for inter-observer reliability was 0.87 for all three surgeons.



Figs. 4 and 5. Anterolateral Head Neck Lesion. The arrows highlight the lesion on both views. This lesion crosses the head neck junction and is seen on the lateral view so it can only be the anterolateral head neck lesion rather than the anterolateral neck lesion, which does not cross the head neck junction.

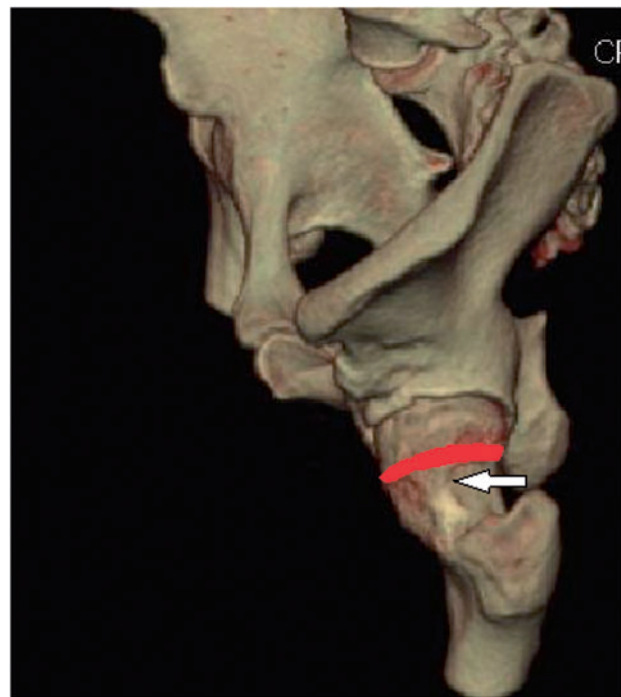

Fig. 5. See Figure 4.

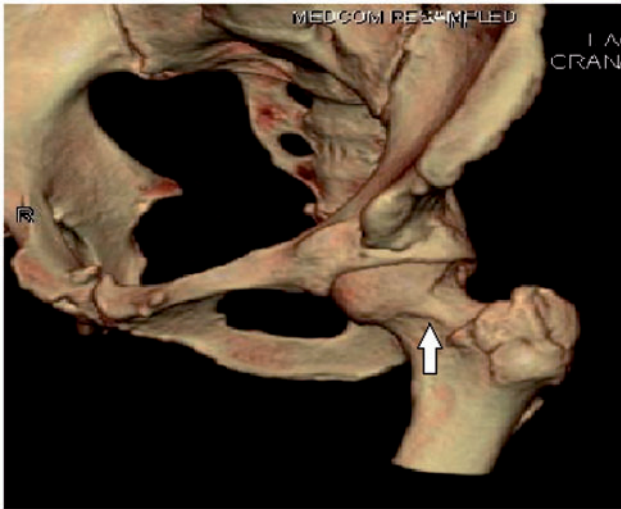

Fig. 6 and 7. Anterolateral neck lesion. This lesion does not cross the head neck junction, but can be seen on both the AP and lateral views.

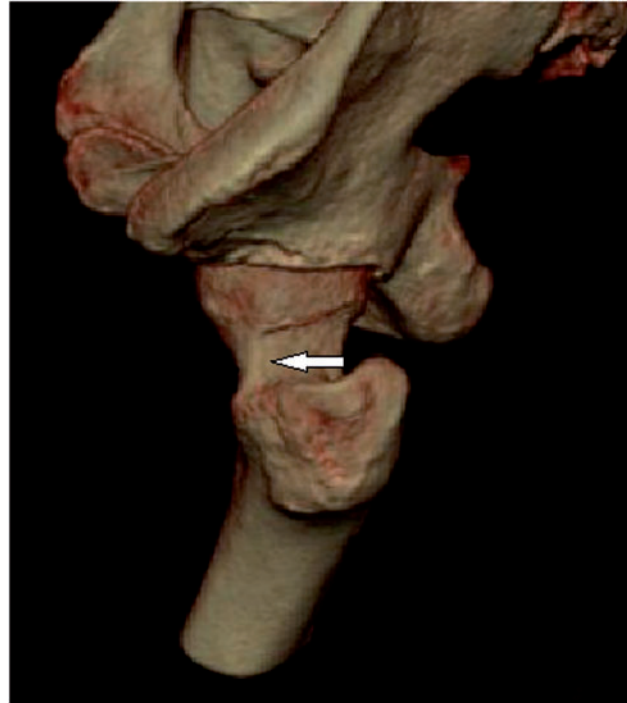

Fig. 7. See figure 6.

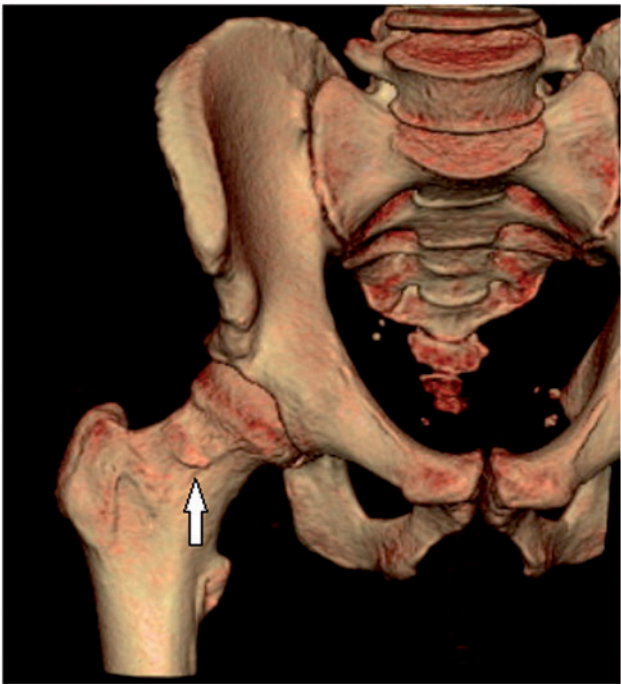


Fig. 8. Anterior neck lesion. This lesion is only seen on the AP view and does not cross the head neck junction.

The scores in [table II](#) show all surgeons could reliably classify the CAM lesions again at a later date.

As you can see there were no specific types of lesion that the surgeons disagreed on significantly ([Table III](#)).

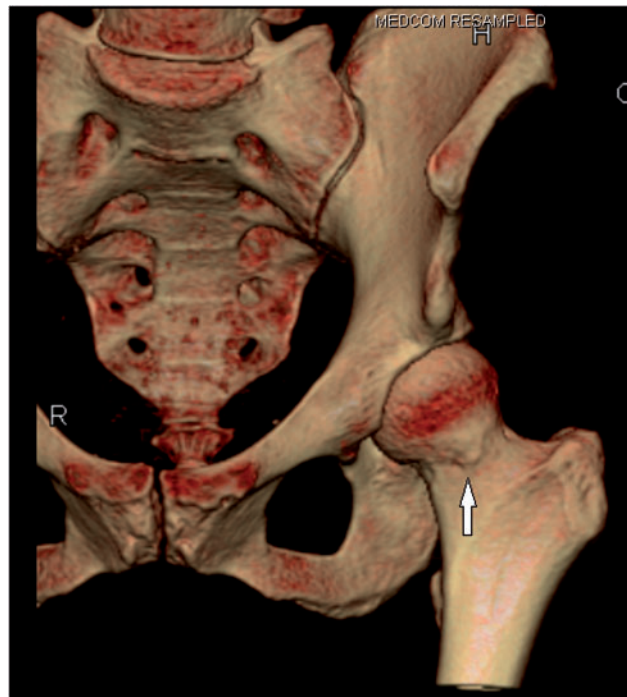

Fig. 9. Anterior head neck junction lesion. This lesion is only seen on the AP view but crosses the head neck junction so is not just the anterior neck lesion seen in [Figure 8](#).

Table I. The variation in CAM lesions between the study groups

	AN	ALHN	ALN	AHNJ	No CAM
Males	2	20	10	4	1
Females	13	11	11	4	15
Significance	$P = 0.022$	$P = 0.001$	$P = 0.613$	$P = 0.711$	$P = 0.002$

Table II. Intra-observer reliability scores for all surgeons

	<i>Intra-observer Kappa score</i>
Senior surgeon	0.91
Senior surgeon	0.90
Junior surgeon	0.87

Table III. The distribution of each CAM lesion when the three surgeons reviewed the scans

	<i>Anterior neck</i>	<i>Anterolateral head/neck</i>	<i>Anterolateral neck</i>	<i>Anterior head neck junction</i>	<i>No CAM</i>
Senior surgeons	15	31	21	8	16
Junior surgeon	13	29	20	12	17

DISCUSSION

This simple four type classification system has been shown to be reliable and accurate during analysis. Kappa coefficient scores of 0.81 or higher for intra and inter-observer reliability are good results in the literature.

The presence of a CAM lesion is common in those patients with FAI, but often there is a mixed pathology with both CAM and Pincer lesions being present. The fact that no CAM lesions were identified in 16 patients suggests this. It also highlights that CT 3D reconstruction images are sensitive enough to exclude the lesion.

The position of the CAM lesion varies within the study population, but four types are reliably described by the senior surgeons. The most common types seen are the anterolateral head neck lesion and anterolateral neck lesion. The anterior head neck junction lesion is the rarest type seen.

The two senior surgeons agreed on all 91 CT scans. With the junior surgeons review, the inter-observer reliability kappa

score dropped to 0.87. We feel the junior surgeon's agreement level was lower because they had no experience of 3D CT scans and CAM lesions before the study. We would expect all hip arthroscopy surgeons to have agreement scores closer to the senior surgeons. The intra-observer scores were also similar between reviewers suggesting the level of experience did not affect reliability of the system.

Some studies have stated a score >0.75 suggests an excellent agreement [19, 20].

These studies on the other hand are opinion rather than backed by statistical evidence. The practical conclusion is that this system is reliable and reproducible for all levels of surgeons to use when assessing CAM lesions.

Although the CAM deformities have been measured in previous literature using the alpha angle and triangular index measurements [4–7], their validity has been questioned when compared with CT 3D reconstruction [11, 21, 22]. It is only possible to map the exact position and size of CAM lesions using 3D CT. This imaging gives an excellent visualisation of the lesions and helps with the preoperative planning of the procedure. Several studies have looked at CT 3D reconstruction to calculate a more accurate alpha angle with significant improvements compared with AP radiographs [10, 11]. The alpha angle however, only gives the largest point of deformity within the lesion. Our system defines the position and rough shape of the lesion rather than one point. It allows the surgeon to map the lesion across a larger area than one alpha angle point. When a surgeon only uses the alpha angle, it is possible to miss other areas of the lesion causing symptoms. One study by Bedi *et al.* [23] has used clock positions to describe the position of CAM deformities in 3D CT reconstructions. They found all patient deformities were located within the 12 to 4 o'clock positions. We feel our classification of four groups encompasses all shapes of CAM lesion. The CAM lesion is not a line on a clock face, but more a bony island.

Computer 3D software packages are available to map the exact size and shape of a CAM lesion [24, 25]. The CT scans have to be sent off for considerable money and the result is waited on. The results do give exact measurements in millimetres of the CAM lesion and motion analysis to see where the lesion causes impingement. This is

therefore the gold standard, but cannot be afforded by most healthcare systems. With our system the lesion is mapped by the surgeon themselves in clinic using the local radiology software. This is why we feel our system is the simplest and most effective way of mapping CAM lesions.

Hip arthroscopy is known as a technically difficult procedure and studies show complication rates and clinical outcomes improve with experience. Konan *et al.* [14] suggested 30 procedures are needed before complication rates decrease significantly [15]. The aim of this classification system is to help the surgeon pre and intra-operatively. When these lesions are mapped, one can use a targeted approach to their resection at operation with the help of intra-operative fluoroscopy. This can potentially reduce the effect of the surgeons experience on outcomes. With less capsular resection and more targeted portal placement we feel surgical complications will be lower and outcomes will improve.

The limitations of this study are that the lesions cannot be quantified in size. We can highlight the different shapes, but no exact measurements can be given from the classification. As mentioned earlier, programs are available to do this but come at a cost to the health provider. We feel this system is the best option between cost effectiveness and accuracy of CAM lesion assessment. No classification system is perfect but we feel this provides valuable information to surgeons when planning CAM resection.

Another limitation is that only three reviewers were used and potentially more would validate the system further. The statistical analysis with kappa scores is a limitation but is the best analysis available. It cannot completely exclude the element of chance agreement.

CONCLUSION

The mapping of CAM lesions with our CT 3D reconstruction method allows for a reproducible classification system that is simple and cheap compared with remodeling software packages. Plain X-rays are cheaper but do not have the accuracy of CT 3D reconstruction. We feel our system is the best balance between accuracy and cost effectiveness. The identification of the position and shape of the CAM lesion allows for more accurate surgical planning. This can potentially reduce the number of portals needed and damage less capsule, which will lower complication rates and improve the surgical outcomes for junior hip arthroscopy surgeons.

CONFLICTS OF INTEREST

None declared.

REFERENCES

1. Ganz R, Parvizi J, Beck M *et al.* Femoroacetabular impingement: a cause for early osteoarthritis of the hip. *Clin Orthop* 2003; **417**:112–20.
2. Byrd JW, Jones KS. Arthroscopic femoroplasty in the management of cam-type femoroacetabular impingement. *Clin Orthop* 2009; **467**:739–46.
3. Cobb J, Iqbal K, Davda K *et al.* Cams and pincer impingement are distinct, not mixed: the acetabular pathomorphology of femoroacetabular impingement. *Clin Orthop Relat Res* 2010; **468**:2143–51.
4. Tannast M, Siebenrock KA, Anderson SE. Femoroacetabular impingement: radiographic diagnosis—what the radiologist should know. *AJR Am J Roentgenol* 2007; **188**:1540–52.
5. Stulberg S. Unrecognized childhood hip disease: a major cause of idiopathic osteoarthritis of the hip. In: *The Hip. Proceedings of the Third Open Scientific Meeting of the Hip Society*, pp. 212–28. St. Louis, C. V. Mosby, 1975.
6. Bardakos NV, Villar R. Predictors of progression of osteoarthritis in femoroacetabular impingement. A radiological study with a minimum of ten years follow up. *J Bone Joint Surg Br* 2009; **91-B**:162–9.
7. Notzli HP, Wyss TF, Stoecklin CH *et al.* The contour of the femoral head-neck junction as a predictor for the risk of anterior impingement. *J Bone Joint Surg Br* 2002; **84B**:556–60.
8. Gosvig K, Jacobsen S, Palm H *et al.* A new radiological index for assessing asphericity of the femoral head in cam impingement. *J Bone Joint Surg Br* 2007; **89**:1309–16.
9. Ipach I. A new classification for “pistol grip deformity” - correlation between the severity of the deformity and the grade of osteoarthritis of the hip. *Rofo* 2011; **183**:365–71.
10. Audenaert EA, Baelde N, Huysse W *et al.* Development of a three-dimensional detection method of cam deformities in femoroacetabular impingement. *Skeletal Radiol* 2011; **40**:921–7.
11. Barton C, Salineros MJ, Rakhra KS *et al.* Validity of the alpha angle measurement on plain radiographs in the evaluation of cam-type femoroacetabular impingement. *Clin Orthop Relat Res* 2011; **469**:464–9.
12. Pfirrmann C, Mengiardi B, Dora C *et al.* Cam and pincer femoroacetabular impingement: characteristic MR arthrographic findings in 50 patients. *Radiology* 2006; **240**:778–85.
13. Rakhra K, Sheikh AM, Allen D *et al.* Comparison of MRI alpha angle measurement planes in femoroacetabular impingement. *Clin Orthop Relat Res* 2009; **467**:660–5.
14. Konan S, Rhee SJ, Haddad FS. Hip arthroscopy: analysis of a single surgeon’s learning experience. *J Bone Joint Surg [Am]* 2011; **93-A (Suppl)**:52–6.
15. Souza BG, Dani WS, Honda EK *et al.* Do complications in hip arthroscopy change with experience? *Arthroscopy* 2010; **26**:1053–7.
16. Larson CM, Giveans MR. Arthroscopic management of femoroacetabular impingement: early outcomes measures. *Arthroscopy* 2008; **24**:540–6.
17. Philippon MJ, Schenker ML, Briggs KK *et al.* Revision hip arthroscopy. *Am J Sports Med* 2007; **35**:1918–21.
18. Sardana V, Philippon MJ *et al.* Revision hip arthroscopy indications and outcomes: a systematic review. *Arthroscopy* 2015; **31**:2047–55.

19. Landis J, Koch G. The measurement of observer agreement for categorical data. *Biometrics* 1977; **33**:159–74.
20. Fleiss J. *Statistical Methods for Rates and Proportions*, 2nd edn. New York: John Wiley. 1981.
21. Nepple JJ, Martel JM, Kim YJ *et al.* ANCHOR Study Group. Do plain radiographs correlate with CT for imaging of cam-type femoroacetabular impingement? *Clin Orthop Relat Res* 2012; **470**: 3313–20.
22. Horisberger M, Brunner A, Herzog RF. Arthroscopic treatment of femoroacetabular impingement of the hip: a new technique to access the joint. *Clin Orthop* 2010; **468**:182–90.
23. Bedi A, Dolan M, Magennis E *et al.* Computer-assisted modelling of osseous impingement and resection in femoroacetabular impingement. *Arthroscopy* 2012; **28**:204–18.
24. Milone M, Bedi A, Poultsides L *et al.* Novel CT-based three-dimensional software improves characterization of CAM morphology. *Clin Orthop Relat Res* 2013; **471**:2484–91.
25. Audenaert E, Smet B, Pattyn C *et al.* Imageless versus image-based registration in navigated arthroscopy of the hip, a cadaver-based assessment. *J Bone Joint Surg Br* 2012; **94**:624–9.