

Research Article

Efficacy Analysis of Combining Sintilimab with Neoadjuvant Chemotherapy in Treating Middle and Advanced Rectal Cancer Based on Big Data

Yifei Wang,¹ Jiandong Fei,¹ Yanan Zheng,¹ Ping Li,¹ Xiaodong Ren,² and Yongzhu An¹ 

¹Department of Gastrointestinal Surgery, The First Affiliated Hospital of Hebei North University, Zhangjiakou, 075000 Hebei, China

²Central Laboratory, The First Affiliated Hospital of Hebei North University, Zhangjiakou, 075000 Hebei, China

Correspondence should be addressed to Yongzhu An; anyongzhu@hbbfyfy.com.cn

Received 27 June 2022; Revised 9 August 2022; Accepted 25 August 2022; Published 16 September 2022

Academic Editor: Alamgeer Yuchi

Copyright © 2022 Yifei Wang et al. This is an open access article distributed under the Creative Commons Attribution License, which permits unrestricted use, distribution, and reproduction in any medium, provided the original work is properly cited.

Objective. To analyze the efficacy of combining sintilimab with neoadjuvant chemotherapy in treating middle and advanced rectal cancer based on big data. **Methods.** According to the inclusion and exclusion criteria, 43 patients with middle and advanced rectal cancer, who were treated with sintilimab and neoadjuvant chemotherapy in General Surgery of the hospitals of Zhangjiakou city from January 2020 to January 2022, were selected for the retrospective study. The patients' short-term efficacy was scientifically evaluated, and the factors affecting efficacy and the correlation were analyzed. **Results.** Among the 43 enrolled patients, 30 of them had regional lymphatic metastasis but none had distant metastasis; most patients were at Broders II and TNM III, and all of them had adenocarcinoma; the total response rate was 69.77% (30 cases), with no grade IV and V adverse reactions; the patients were divided into the effective group and the ineffective group after treatment based on the evaluation results of short-term efficacy, and analysis of the relevant factors exposed in both groups revealed significant differences in age, tumor size, CEA, NLR value, PLR value, TNM stage, and presence of combined lymphatic metastasis between the two groups ($P < 0.05$); univariate analysis showed that tumor size, CEA, TNM stage, and combined lymphatic metastasis were the independent risk factors affecting the efficacy in patients with middle to advanced rectal cancer ($P < 0.05$); and through the Spearman correlation analysis of the above independent risk factors, it was further confirmed that tumor size, CEA, TNM stage, and combined lymphatic metastasis were negatively correlative with the efficacy of combining sintilimab with neoadjuvant chemotherapy in treating middle to advanced rectal cancer ($P < 0.05$). **Conclusion.** Combining sintilimab with neoadjuvant chemotherapy has good efficacy and safety profile, which is conducive to subsequent surgery; in contrast, larger tumor diameter, higher CEA level, higher TNM stage, and more serious lymphatic metastasis are all independent risk factors affecting treatment sensitivity and can lead to poor efficacy.

1. Introduction

Rectal cancer is one of the most common malignant tumors of the digestive tract. According to the 2020 global epidemiological statistics on cancer published by the International Agency for Research on Cancer (IARC), rectal cancer has become the 3rd most prevalent malignant tumor in men and the 2nd in women worldwide, with the highest incidence in developed countries such as North America, Aus-

tralia, and New Zealand and 392,000 new cases in China in 2018. Its early symptoms are not obvious, and the incidence is relatively high in men aged 40-80 years. At present, surgical treatment is in the central position in rectal cancer treatment, because it provides patients at the early stage with long-term survival and those who can only receive limited treatment if they have local recurrence or distant metastasis with better survival in combination with chemoradiotherapy [1]. For patients with locally advanced rectal cancer,

neoadjuvant chemotherapy can lower the tumor stage, and some reports have confirmed that the application of neoadjuvant chemotherapy before total mesorectal excision (TME) is the “gold standard” for the treatment of patients with stage II and III rectal cancer [2, 3]. In addition, some published works and reports also state that neoadjuvant chemotherapy has the potential to reduce local recurrence. In recent years, the studies of immune checkpoint inhibitors (ICIs) in various tumors are growing vigorously, and the results have shown that ICIs have good therapeutic effect. Immunotherapy is claimed to significantly improve the prognosis of colorectal cancer patients, and ICIs have also been recommended as a first-line option for advanced rectal cancer [4–7]. Related studies suggest that ICIs show good effects in the neoadjuvant treatment of resectable rectal cancer; meanwhile, ICI drugs also have a great potential in the comprehensive treatment decision-making of locally advanced and early rectal cancer. In 2022, sindilizumab as an innovative PD-1 inhibitor drug was successfully included in the CSCO guidelines for the clinical use of ICIs, achieving the breakthrough that all first-line therapies for five major tumors were included in the CSCO guidelines [8–10]. The use of immunotherapy in neoadjuvant treatment is mostly dependent on the safety and efficacy of the treatment, and it is still in the stage of active exploration from relevant data at home and abroad, with few clinical studies reported. Therefore, this article mainly collected middle and advanced rectal cancer patients treated with sindilizumab plus neoadjuvant chemotherapy in the General Surgery of the hospitals to carry out a retrospective study and to inquire about the clinicopathological factors related to the treatment efficacy, avoiding ineffectiveness or overtreatment, which is also beneficial to guide the preoperative treatment regimen and achieve the individualized treatment of middle and advanced rectal cancer.

2. Materials and Methods

2.1. Inclusion Criteria. (1) All patients were diagnosed with middle and advanced rectal cancer after CT, MRI, and pathological examination; (2) the TNM stages of the patients were IIc and III; (3) the ECOG score was less than 3 points; (4) the patients had basically normal routine blood test result, ECG, coagulation function, and liver and kidney function; (5) the patients failed in first-line oxaliplatin+targeted therapy chemotherapy and had not receive other PD-1 immunotherapy; (6) the patients did not have contraindications of sindilizumab and chemotherapy; (7) the patients received TME after neoadjuvant chemotherapy; and (8) the patients and their family members understood the study and signed the treatment consent and study consent.

2.2. Exclusion Criteria. Exclusion criteria are as follows: (1) complicated with other malignant tumors; (2) complicated with heart disease, severe hypertension, and other diseases of the cardiovascular system; (3) complicated with hematological system diseases and severe internal medicine diseases; (4) central nervous system metastases; (5) estimated survival

less than 3 months; (6) concurrent acute infection, such as lung infection and urinary system infection; (7) pregnant or lactating women; and (8) low compliance with treatment and lost to follow-up.

2.3. Patient Screening. According to the inclusion and exclusion criteria, 43 patients with middle and advanced rectal cancer, who were treated with sintilimab and neoadjuvant chemotherapy in General Surgery of the hospitals of Zhangjiakou city from January 2020 to January 2022, were selected for the retrospective study; the study plan met the code of ethics and was reviewed and approved by the ethics committees of the hospitals of Zhangjiakou city.

2.4. Methods

2.4.1. Sintilimab. Patients were treated with third-line and above anti-PD-1 mAb monotherapy or in combination with other agents, the single dosage of sintilimab injection (Tyvyt®) (specification: 100 mg; manufacturer: Innovent Biologics (Suzhou) Co., Ltd.; NMPA approval no. S20180016) was 200 mg, and it was administered once every 3 weeks until the downstaging effect and surgical resection indicators were met, so as to improve the rate of radical resection (R0 resection).

2.4.2. Neoadjuvant Chemotherapy. XELOX scheme: from day 1 to day 14, 1000 mg/m² of capecitabine was given twice daily; and at day 1, 130 mg/m² of oxaliplatin was given. If a second course of chemotherapy was implemented, it should be started at day 22 of radiotherapy.

2.5. Observation Indicators. Clinical characteristics: the enrolled patients' clinical information including age (with 55 years old as the critical value), gender, smoking, Broders classification, ECOG score, and TNM stage was recorded.

Short-term efficacy: patients received reexamination after 4 weeks of treatment and were evaluated according to the WHO criteria for short-term objective response evaluation in solid tumors [11]. Complete disappearance of tumor lesions and maintenance for ≥ 4 weeks were considered complete remission (CR); $\geq 30\%$ reduction in volume of tumor lesions compared with that before treatment and maintenance for ≥ 4 weeks represented partial remission (PR); $< 30\%$ reduction in volume of tumor lesions compared with that before treatment or $< 20\%$ increase represented stable disease (SD); and $\geq 20\%$ increase in volume of tumor lesions compared with that before treatment or appearance of new lesions represented progressive disease (PD), with total response = CR + PR.

Adverse reactions: according to the Common Terminology Criteria for Adverse Events (CTCAE) v4.0 of the National Cancer Institute (NCI) [12], the adverse reactions were divided into grades I to V (grade I: mild adverse reaction, asymptomatic or mild symptoms, intervention not indicated; grade II: moderate adverse reactions, clinical symptoms that require intervention and may affect body function, but daily life will not be affected; grade III: severe adverse reactions, complicated symptoms that require active intervention and treatment; grade IV: life-threatening

TABLE 1: Clinical characteristics of 43 patients ($n = 43$).

| Clinical data | Number of cases | Proportion (%) |
|---------------|-----------------|----------------|
| Age | | |
| ≤55 years | 20 | 46.51 |
| >55 years | 23 | 53.49 |
| Gender | | |
| Male | 28 | 65.12 |
| Female | 15 | 34.88 |
| Smoking | | |
| Yes | 24 | 55.81 |
| No | 19 | 44.19 |
| Broders grade | | |
| I | 4 | 9.30 |
| II | 31 | 72.09 |
| III | 8 | 18.60 |
| ECOG score | | |
| 0-1 point | 26 | 60.47 |
| 2 points | 17 | 39.53 |
| TNM stage | | |
| IIC | 13 | 30.23 |
| III | 30 | 69.77 |

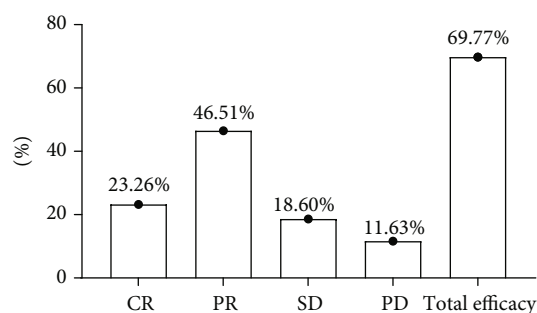


FIGURE 1: Evaluation results of patients' short-term efficacy.

adverse reactions that may lead to disability and even organ damage or dysfunction; grade V: death).

Fasting venous blood was taken from all patients after treatment and tested for white blood cell count (normal range: $4.0 - 10.0 \times 10^9/L$), neutrophils (normal range: $1.80 - 6.30 \times 10^9/L$), lymphocytes (normal range: $0.8 - 4 \times 10^9/L$), platelets (normal range: $100 - 300 \times 10^9/L$), CEA (normal range: $3.5 - 5.0 \text{ ng/mL}$), CA199 (normal range: $<37 \text{ IU/mL}$), NLR (normal range: 1-3), and PLR (normal range: 63.0-182.6).

The related factors, such as age (>55 years old), tumor size ($\geq 3 \text{ cm}$), gender (male), distance between tumor and anal verge ($\geq 5 \text{ cm}$), concurrent chemotherapy cycle (≥ 3 weeks), neoadjuvant chemotherapy cycle (≥ 2 weeks), white blood cell count, neutrophil, lymphocyte, platelet, CEA, CA199, NLR value, PLR value, TNM stage, and lymph node metastasis, were included in the single variate analysis of treatment effectiveness, and then, logistic regression analysis and Spearman correlation analysis were performed.

2.6. Statistical Processing. In this study, the data processing software was SPSS 22.0, which was mainly used to calculate the between-group differences of data; the picture drawing software was GraphPad Prism 7 (GraphPad Software, San Diego, USA); the items included were enumeration data and measurement data, which were expressed by $[n(\%)]$ and $(\bar{x} \pm s)$, examined by the X^2 test and t -test, and met normal distribution; and differences were considered statistically significant when $P < 0.05$.

3. Results

3.1. Clinical Characteristics. Among the 43 enrolled patients (aged 42 to 74 years) of the study, there were 28 males and 15 females, 30 patients had regional lymphatic metastasis, and none had distant metastasis; most patients were at Broders II and TMN III stage, all of them had adenocarcinoma. See Table 1 for statistical data.

3.2. Short-Term Efficacy. All 43 patients finished sintilimab treatment, neoadjuvant chemotherapy, and surgical treatment and completed clinical efficacy evaluation. There were 10 CR cases, 20 PR cases, 8 SD cases, and 5 PD cases and a total of 30 effective cases. See Figure 1.

3.3. Adverse Reactions. After recording patients' adverse reactions, it was found that patients did not have grade IV and V adverse reactions, and the incidence rate of vomiting and nausea was the highest, followed by granulocytopenia and mucocutaneous damage. See Table 2.

3.4. Analysis of Factors Related to Treatment Effectiveness. The patients were divided into the effective group ($n = 30$) and the ineffective group ($n = 30$) after treatment based on the evaluation results of short-term efficacy, and analysis of the relevant factors exposed in both groups revealed significant differences in age, tumor size, CEA, NLR value, PLR value, TNM stage, and presence of combined lymphatic metastasis between the two groups ($P < 0.05$). See Table 3.

3.5. Logistic Regression Analysis. After including the single factors into logistic regression analysis, it was showed that tumor size, CEA, TNM stage, and lymphatic metastasis were independent risk factors affecting the efficacy of combining sintilimab with neoadjuvant chemotherapy in treating middle and advanced rectal cancer ($P < 0.05$). See Table 4.

3.6. Correlation Analysis. After performing Spearman correlation analysis of the above independent risk factors, it was further confirmed that tumor size, CEA, TNM stage, and combined lymphatic metastasis were negatively correlated with the efficacy of combining sintilimab with neoadjuvant chemotherapy in treating middle and advanced rectal cancer ($P < 0.05$). See Table 5.

4. Discussion

In recent years, neoadjuvant chemoradiotherapy has gradually walked into the popular field, and numerous previous studies have shown that the comprehensive treatment mode

TABLE 2: Evaluation results of patients' adverse reactions.

| Adverse reactions | Grade I | Grade II | Grade III | Grade IV | Grade V | Total incidence rate [n (%)] |
|----------------------|---------|----------|-----------|----------|---------|------------------------------|
| Nausea | 17 | 2 | 0 | 0 | 0 | 19 (44.19) |
| Vomiting | 15 | 3 | 1 | 0 | 0 | 19 (44.19) |
| Diarrhea | 6 | 5 | 0 | 0 | 0 | 11 (25.58) |
| Leukopenia | 8 | 4 | 0 | 0 | 0 | 12 (27.91) |
| Granulocytopenia | 11 | 4 | 2 | 0 | 0 | 17 (39.53) |
| Thrombocytopenia | 3 | 3 | 0 | 0 | 0 | 6 (13.95) |
| Mucocutaneous damage | 10 | 4 | 1 | 0 | 0 | 15 (34.88) |
| Neurotoxicity | 9 | 2 | 0 | 0 | 0 | 11 (25.58) |
| Peripheral phlebitis | 4 | 1 | 0 | 0 | 0 | 5 (11.63) |

TABLE 3: Analysis of factors related to treatment effectiveness.

| Related factors | Ineffective group (n = 13) | Effective group (n = 30) | X ² /t | P |
|---|----------------------------|--------------------------|-------------------|--------|
| Age (>55 years) | 10 (72.92) | 13 (43.33) | 4.113 | 0.043 |
| Gender (male) | 7 (53.85) | 21 (70.00) | 1.042 | 0.307 |
| Tumor size (≥3 cm) | 8 (61.54) | 8 (26.67) | 4.721 | 0.030 |
| Distance between tumor and anal verge (≥5 cm) | 7 (53.85) | 16 (53.33) | 1.042 | 0.307 |
| Concurrent chemotherapy cycle (≥3 weeks) | 6 (46.15) | 11 (36.67) | 0.342 | 0.559 |
| Neoadjuvant chemotherapy cycle (≥2 weeks) | 8 (61.54) | 16 (53.33) | 0.248 | 0.619 |
| White blood cell count (×10 ⁹ /L) | 3.82 ± 0.55 | 4.03 ± 0.68 | 0.981 | 0.332 |
| Neutrophil (×10 ⁹ /L) | 3.04 ± 1.01 | 3.10 ± 1.04 | 0.175 | 0.862 |
| Lymphocyte (×10 ⁹ /L) | 0.90 ± 0.54 | 0.92 ± 0.49 | 0.119 | 0.906 |
| Platelet (×10 ⁹ /L) | 216.94 ± 60.16 | 218.33 ± 68.73 | 0.063 | 0.950 |
| CEA (ng/mL) | 5.24 ± 1.48 | 2.64 ± 1.28 | 5.836 | <0.001 |
| CA199 (IU/mL) | 30.31 ± 12.16 | 23.85 ± 11.95 | 1.575 | 0.123 |
| NLR value | 4.16 ± 0.62 | 3.61 ± 0.85 | 2.098 | 0.042 |
| PLR value | 284.03 ± 13.85 | 270.11 ± 13.74 | 3.044 | 0.004 |
| TNM stage | | | 4.488 | 0.034 |
| IIc | 1 (7.69) | 12 (40.00) | | |
| III | 12 (92.31) | 18 (60.00) | | |
| Lymphatic metastasis | 12 (92.31) | 18 (60.00) | 4.488 | 0.034 |

TABLE 4: Multivariate logistic regression analysis.

| Variable | B | S.E. | Wals | df | Sig. | Exp (B) | 95% C.I. of Exp (B) |
|----------------------|--------|-------|--------|----|-------|---------|---------------------|
| Tumor size | -1.482 | 0.704 | 4.431 | 1 | 0.035 | 0.227 | 0.057-0.903 |
| CEA (ng/mL) | -1.240 | 0.376 | 10.904 | 1 | 0.001 | 3.457 | 1.656-7.218 |
| TNM stage | -2.079 | 1.106 | 3.538 | 1 | 0.006 | 0.125 | 0.014-1.091 |
| Lymphatic metastasis | -2.079 | 1.106 | 3.538 | 1 | 0.006 | 0.125 | 0.014-1.091 |

of neoadjuvant therapy combined with radical surgery has a relatively good effect on reducing the pathological stage of middle and advanced rectal cancer, lowering the rate of local recurrence, prolonging survival time, and improving the rate of anal conserving and the quality of life [13, 14]. Through preoperative neoadjuvant chemoradiotherapy, it is able to achieve postoperative pathological outcome as CR with low

chance of recurrence in some patients; in addition, it can reduce the total number and positive rate of lymph nodes in postoperative specimens, which is beneficial to the improvement of the curative resection rate; and finally, neoadjuvant therapy reduces the tumor volume, increases the distance between the lower edge of the tumor and the anal verge, and increases the success rate of anal-conserving

TABLE 5: Spearman correlation analysis.

| Variable | N | Correlative coefficient | Significance |
|----------------------|----|-------------------------|--------------|
| Tumor size | 43 | -0.331* | 0.030 |
| CEA (ng/mL) | 43 | -0.664** | <0.001 |
| TNM stage | 43 | -0.323* | 0.035 |
| Lymphatic metastasis | 43 | -0.323* | 0.035 |

Note: * indicated significant correlation at the 0.05 level (two-sided); ** indicated a significant correlation at the 0.01 level (two-sided).

surgery. Meanwhile, concomitant with the continuous development of medical treatment, ICIs represented by anti-PD-1 mAb have become a research hotspot for cancer therapy, and a pan-tumor clinical trial study found that patients with mismatch repair dysfunction and high microsatellite instability might benefit from anti-PD-1 mAb therapy, but there is still insufficient evidence, and immunotherapy strategies for rectal cancer are under continuous exploration. The advent of sindilizumab marks the entry of antitumor immunotherapy in China into the innovation era. It is characterized by high affinity, long-lasting, stability and high target occupancy, and the objective response rate and disease control rate of immunotherapy using this drug for relapsed and refractory Hodgkin lymphoma are as good as those of innovative drugs of the international class [15, 16]. At present, radiotherapy combined with immunotherapy is the research hotspot of tumor regression, and the systemic immune response induced before surgery can make the body produce immune memory, while after surgery, patients cannot produce immune-mediated sustained antitumor effects due to tumor resection, so neoadjuvant chemotherapy combined with immunotherapy is also rational to a certain extent. Based on this, the efficacy of combining sindilizumab with neoadjuvant chemotherapy in treating middle and advanced rectal cancer was explored herein, and the related factors affecting efficacy were analyzed based on data.

The evaluation of clinical results of 43 patients revealed that there were 10 CR cases, 20 PR cases, 8 SD cases, and 5 PD cases, and the overall response rate of treatment was 69.77% (30 cases), which was higher compared with the previous results. On the one hand, the study result affirmed the efficacy of sindilizumab combined with neoadjuvant chemotherapy in patients with medium and advanced rectal cancer; on the other hand, because sindilizumab injection was officially marketed in mainland China only in 2019 and the duration of its clinical use for rectal cancer treatment is relatively short, so there are relatively few clinical cases. In addition, based on the study criteria, most of the enrolled patients were TNM stage III patients, some of them had regional lymph node metastasis, and none had distant metastasis, and therefore, the specificity of case screening may have some influence on the overall efficacy statistics. Based on the statistics of adverse reactions in patients, no grade IV and V adverse reactions occurred in all patients, and the incidence of nausea and vomiting was the highest, followed by granulocytopenia and mucocutaneous damage, which was close to most of the previous similar reported data [17, 18]. The overall incidence of adverse reactions

was not low but was within an acceptable range from the point of view of clinical treatment. The patients were divided into the effective group and the ineffective group after treatment based on the evaluation results of short-term efficacy, and analysis of the relevant factors exposed in both groups revealed significant differences in age, tumor size, CEA, NLR value, PLR value, TNM stage, and presence of combined lymphatic metastasis between the two groups ($P < 0.05$); after including the single factors into logistic regression analysis, it was showed that tumor size, CEA, TNM stage, and combined lymphatic metastasis were the independent risk factors affecting the efficacy of combining sintilimab with neoadjuvant chemotherapy in treating middle and advanced rectal cancer ($P < 0.05$); and after performing Spearman correlation analysis of the above independent risk factors, it was further confirmed that tumor size, CEA, TNM stage, and combined lymphatic metastasis were negatively correlative with the efficacy of combining sintilimab with neoadjuvant chemotherapy in treating middle and advanced rectal cancer ($P < 0.05$). In terms of TNM studies in malignant tumors, reports have confirmed that the later the T stage of the tumor, the poorer the efficacy [19–21]. As the course of the disease progresses, the depth of tumor infiltration increases, the blood supply is relatively insufficient, and the tumor cells suffer from poor nutrition and hypoxia, which reduce the treatment sensitivity.

The sensitivity of mAb therapy and chemotherapy is dependent not only on the biological characteristics of the tumor itself but also on the microenvironment in which it resides. In vivo studies have found that tumor cells dying after chemoradiotherapy are able to present tumor associated antigens to host immune cells, activating the body tumor response. Therefore, hematological indices can also be an influential factor in the evaluation of recurrence and prognosis. The results of available studies suggest that neutrophils, NLR, lymphocytes, platelets, and CEA have some correlation with the efficacy and clinicopathological characteristics of neoadjuvant chemoradiotherapy and are somewhat valuable in judging the prognosis [22, 23]. CEA is widely used to predict the efficacy of neoadjuvant chemoradiotherapy for rectal cancer, with demonstrated efficacy predictive value. The changes in NLR and PLR, novel systemic immune response indicators, are caused by the synergistic effect of neutrophils, platelets, and lymphocytes. Relevant studies have shown that preoperative NLR levels and tumor volume size in cancer patients have significant associations [24, 25]. In this study, in logistic regression analysis and correlation analysis, the difference of NLR and PLR was not found, so the reference and guidance value of their level changes for the treatment of rectal cancer with the combination of sindilizumab and neoadjuvant chemotherapy should be confirmed with large-sample and multicenter studies.

In conclusion, combining sintilimab with neoadjuvant chemotherapy has significant efficacy in treating middle and advanced rectal cancer and is safer, which is conducive to the subsequent surgery; and larger tumor diameter, higher CEA level, higher TNM stage, and more serious lymphatic

metastasis are all independent risk factors affecting treatment sensitivity and can lead to poor efficacy.

Data Availability

Data to support the findings of this study is available on reasonable request from the corresponding author.

Conflicts of Interest

The authors do not have conflicts of interest to declare.

References

- [1] X. Yang, T. Hu, C. Gu et al., "The prognostic significance of isolated tumor cells detected within lateral lymph nodes in rectal cancer patients after laparoscopic lateral lymph node dissection," *Journal of Laparoendoscopic & Advanced Surgical Techniques*, vol. 29, no. 11, pp. 1462–1468, 2019.
- [2] A. Nishie, Y. Asayama, K. Ishigami et al., "Amide proton transfer imaging to predict tumor response to neoadjuvant chemotherapy in locally advanced rectal cancer," *Journal of Gastroenterology and Hepatology*, vol. 34, no. 1, pp. 140–146, 2019.
- [3] S. P. Ng, J. Chu, S. Chander et al., "Results of phase II trial of intensified neoadjuvant treatment with interdigitating radiotherapy and chemotherapy with oxaliplatin, 5-fluorouracil and folinic acid in patients with locally advanced rectal cancer (PROARCT trial)," *Radiotherapy and Oncology*, vol. 155, pp. 27–32, 2021.
- [4] S. Lichthardt, L. Zenorini, J. Wagner et al., "Impact of adjuvant chemotherapy after neoadjuvant radio- or radiochemotherapy for patients with locally advanced rectal cancer," *Journal of Cancer Research and Clinical Oncology*, vol. 143, no. 11, pp. 2363–2373, 2017.
- [5] F. Sclafani, G. Brown, D. Cunningham et al., "Systemic chemotherapy as salvage treatment for locally advanced rectal cancer patients who fail to respond to standard neoadjuvant chemoradiotherapy," *The Oncologist*, vol. 22, no. 6, pp. 728–736, 2017.
- [6] J. Zhang, M. Huang, Y. Cai et al., "Neoadjuvant chemotherapy with mFOLFOXIRI without routine use of radiotherapy for locally advanced rectal cancer," *Clinical Colorectal Cancer*, vol. 18, no. 4, pp. 238–244, 2019.
- [7] S. Hasegawa, S. Goto, T. Matsumoto et al., "A multicenter phase 2 study on the feasibility and efficacy of neoadjuvant chemotherapy without radiotherapy for locally advanced rectal cancer," *Annals of Surgical Oncology*, vol. 24, no. 12, pp. 3587–3595, 2017.
- [8] S. Feng, P. Yan, Q. Zhang et al., "Induction chemotherapy followed by neoadjuvant chemoradiotherapy and surgery for patients with locally advanced rectal cancer: a systematic review and meta-analysis," *International Journal of Colorectal Disease*, vol. 35, no. 8, pp. 1355–1369, 2020.
- [9] K. Toritani, J. Watanabe, Y. Suwa et al., "A prospective, single-arm, multicenter trial of neoadjuvant chemotherapy with mFOLFOX6 plus panitumumab without radiotherapy for locally advanced rectal cancer," *International journal of colorectal disease*, vol. 35, no. 12, pp. 2197–2204, 2020.
- [10] W. Eisterer, G. Piringer, A. De Vries et al., "Neoadjuvant chemotherapy with capecitabine, oxaliplatin and bevacizumab followed by concomitant chemoradiation and surgical resection in locally advanced rectal cancer with high risk of recurrence - a phase II study," *Anticancer Research: International Journal of Cancer Research and Treatment*, vol. 37, no. 5, pp. 2683–2691, 2017.
- [11] A. Bohlok, A. Hendlisz, F. Bouazza et al., "The potential benefit of adjuvant chemotherapy in locally advanced rectal cancer treated with neoadjuvant chemoradiotherapy is not predicted by tumor regression grade," *International Journal of Colorectal Disease*, vol. 33, no. 10, pp. 1383–1391, 2018.
- [12] T. Conroy, J.-F. Bosset, P.-L. Etienne et al., "Neoadjuvant chemotherapy with FOLFIRINOX and preoperative chemoradiotherapy for patients with locally advanced rectal cancer (UNICANCER-PRODIGE 23): a multicentre, randomised, open-label, phase 3 trial," *The Lancet Oncology*, vol. 22, no. 5, pp. 702–715, 2021.
- [13] Y. Sun, Z. Huang, Y. Zhang et al., "Is early initiation of adjuvant chemotherapy beneficial for locally advanced rectal cancer following neoadjuvant chemoradiotherapy and radical surgery?," *World Journal of Surgery*, vol. 44, no. 9, pp. 3149–3157, 2020.
- [14] K. Y. Hu, M. T. Simpson, J. J. Blank et al., "Use of neoadjuvant chemotherapy in the treatment of locally advanced rectal cancer," *Journal of Surgical Research: Clinical and Laboratory Investigation*, vol. 243, pp. 447–452, 2019.
- [15] F. Sclafani, G. Brown, D. Cunningham et al., "PAN-EX: a pooled analysis of two trials of neoadjuvant chemotherapy followed by chemoradiotherapy in MRI-defined, locally advanced rectal cancer," *Annals of Oncology*, vol. 27, no. 8, pp. 1557–1565, 2016.
- [16] Q. Xu, Y. Xu, H. Sun et al., "Quantitative intravoxel incoherent motion parameters derived from whole-tumor volume for assessing pathological complete response to neoadjuvant chemotherapy in locally advanced rectal cancer," *Journal of Magnetic Resonance Imaging*, vol. 48, no. 1, pp. 248–258, 2018.
- [17] A. Ogura, K. Uehara, T. Aiba et al., "Indications for neoadjuvant treatment based on risk factors for poor prognosis before and after neoadjuvant chemotherapy alone in patients with locally advanced rectal cancer," *European Journal of Surgical Oncology*, vol. 47, no. 5, pp. 1005–1011, 2021.
- [18] A. Patel, P. Szychalski, G. Corrao et al., "Neoadjuvant short-course radiotherapy with consolidation chemotherapy for locally advanced rectal cancer: a systematic review and meta-analysis," *Acta Oncologica*, vol. 60, no. 10, pp. 1308–1316, 2021.
- [19] T. Mukai, K. Uehara, T. Aiba et al., "Importance of the neoadjuvant rectal (NAR) score to the outcome of neoadjuvant chemotherapy alone for locally advanced rectal cancer," *Surgery Today*, vol. 50, no. 8, pp. 912–919, 2020.
- [20] H. Hu and H. Jiang, "Prediction of neoadjuvant radiotherapy and chemotherapy for locally advanced rectal cancer based on 3.0T MRI intravoxel incoherent motion diffusion weighted-imaging with Fe3O4nanocontrast agent," *Nanoscience and Nanotechnology Letters*, vol. 11, no. 12, pp. 1676–1684, 2019.
- [21] K. M. Hardiman, A. G. Antunez, A. Kanters, A. D. Schuman, and S. E. Regenbogen, "Clinical and pathological outcomes of induction chemotherapy before neoadjuvant radiotherapy in locally-advanced rectal cancer," *Journal of Surgical Oncology*, vol. 120, no. 2, pp. 308–315, 2019.
- [22] L. Guo, P. Song, X. Xue et al., "Variation of programmed death ligand 1 expression after platinum-based neoadjuvant

- chemotherapy in lung cancer,” *Journal of Immunotherapy*, vol. 42, no. 6, pp. 215–220, 2019.
- [23] C. Jiangxia, C. Siying, K. Dong et al., “Efficacy and safety of cindilimab in patients with advanced colorectal cancer,” *China pharmacovigilance*, vol. 19, no. 2, pp. 164–168, 2022.
- [24] B. Yue, S. Daqiang, Z. Xun, Z. Gongjian, L. Lili, and C. Qun, “Application of PD-1 monoclonal antibody combined with chemotherapy in preoperative neoadjuvant therapy of stage III a non-small cell lung cancer,” *Chinese Journal of Thoracic and Cardiovascular Surgery*, vol. 38, no. 2, pp. 96–101, 2022.
- [25] G. Chijiang, C. Ke, and D. Jinlin, “Changes and clinical significance of vascular endothelial growth factor after bevacizumab combined with radiotherapy and chemotherapy in the neoadjuvant treatment of locally advanced rectal cancer,” *China Chronic Disease Prevention and Control*, vol. 25, no. 5, pp. 372–375, 2017.