

# Patellar Tendon Revision Reconstruction With Hamstring Tendon Autografts



Edward R. Floyd, M.S., Gregory B. Carlson, M.D., and Robert F. LaPrade, M.D., Ph.D.

**Abstract:** Patellar tendon rupture is an infrequent cause of disability in patients younger than 40 years, with chronic injury and repeat procedures creating difficulty in facilitating healing. Use of hamstring autograft to reinforce the repair has been reported to strengthen the repair construct in patients with previous failure or chronic injury. This technique describes utilization of gracilis and semitendinosus tendon autografts to reconstruct the patellar tendon in a case of primary repair failure.

Patellar tendon rupture is a less common cause of extensor disruption than patella fracture or quadriceps tendon rupture, affecting chiefly skeletally mature adults younger than 40 years.<sup>1,2</sup> It has been associated with corticosteroid use, systemic lupus erythematosus, diabetes mellitus, chronic renal disease, and trauma.<sup>1,3</sup> Patellar tendon degeneration resulting from repetitive microtraumas or age-related changes frequently underlies traumatic rupture in older patients.<sup>3</sup> Traumatic injury in younger patients has been reported to occur as an eccentric load is applied to a flexed knee with patellar tendon taut, with the most force applied to the extensor mechanism occurring with quadriceps contraction at 60 degrees of knee flexion.<sup>4</sup> The tendon is more frequently

torn from its proximal or distal musculotendinous junction (Fig 1), but intrasubstance stretch injury of the tendon has been reported in patients with open physes.<sup>1</sup> Repair is usually indicated in the acute setting to avoid retraction and fibrosis. However, in the presence of a failed repair or morbidity or pathology causing significant disruption of the patellar tendon, a reconstruction may be necessary. Here, we describe a reconstruction technique with hamstring autografts for a failed patellar tendon repair for which a revision repair was not possible.

From Twin Cities Orthopedics Edina-Crosstown, Edina, Minnesota, U.S.A. (E.R.F., G.B.C., R.F.L.) and Georgetown University School of Medicine, Washington, D.C., U.S.A. (E.R.F.).

The authors report the following potential conflicts of interest or sources of funding: R.F.L. is a consultant for Arthrex, Ossur, Smith & Nephew, and Linvatec; receives royalties from Arthrex, Ossur, and Smith & Nephew; receives research grants from Smith & Nephew and Ossur; is on the editorial boards for American Orthopaedic Society for Sports Medicine, Journal of Experimental Orthopaedics, and Knee Surgery, Sports Traumatology, Arthroscopy; and serves on the committees for American Orthopaedic Society for Sports Medicine, Arthroscopy Association of North America, and International Society of Arthroscopy, Knee Surgery and Orthopaedic Sports Medicine. The other authors have nothing to disclose. Full ICMJE author disclosure forms are available for this article online, as [supplementary material](#).

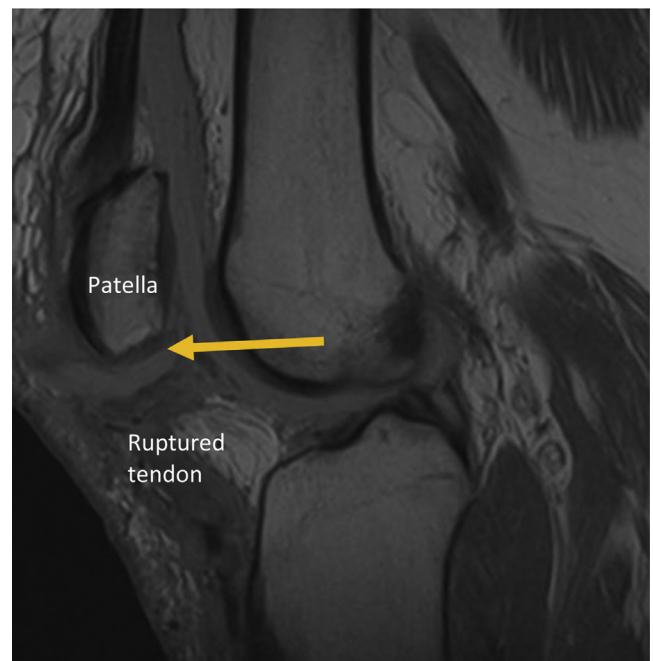
Received October 3, 2020; accepted November 1, 2020.

Address correspondence to Robert F. LaPrade, M.D., Ph.D., Twin Cities Orthopedics Edina-Crosstown, 4010 W 65th St, Edina, MN 55435-1706, U.S.A. E-mail: [laprademphd@gmail.com](mailto:laprademphd@gmail.com)

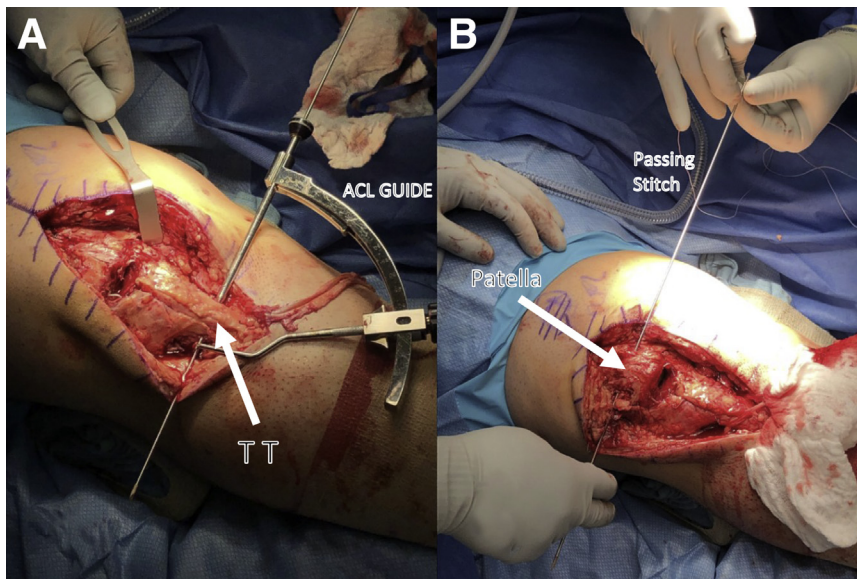
© 2020 by the Arthroscopy Association of North America. Published by Elsevier. This is an open access article under the CC BY-NC-ND license (<http://creativecommons.org/licenses/by-nc-nd/4.0/>).

2212-6287/201663

<https://doi.org/10.1016/j.eats.2020.11.001>



**Fig 1.** Sagittal magnetic resonance image of a right knee showing complete rupture of a previous patellar tendon repair from the inferior pole of the patella.



**Fig 2.** Preparing for graft passage in a right knee. (A) An anterior cruciate ligament tibial guide (Arthrex, Naples, FL) used to drill a tunnel through the tibial tubercle. The tibial tunnel will be overreamed with a 4.5-mm Endobutton reamer before using a passing stitch to pull the semitendinosus graft from medial to lateral. (B) A passing stitch is placed through the patellar tunnel to pull the semitendinosus tendon from lateral to medial.

### Surgical Technique

The patient is brought into the operating room and placed in the supine position. General anesthesia is induced and a padded high thigh tourniquet placed. Range of motion is assessed under anesthesia, along with posterior drawer, Lachman's test, varus and valgus stress testing, and palpation of the tendon defect. Three grams of cefazolin prophylaxis is given before incision.

The surgical technique is demonstrated in [Video 1](#). An anterior longitudinal incision using the previous repair incision is extended to approximately 4 cm distal to the tibial tubercle. If previous surgery or injury has occurred, scar tissue may impede identification of the tibial tubercle; a spinal needle may be used to locate the superior aspect of the tubercle for exposure. Dissection is then carried out toward the pes anserinus tendons. The tibial medial collateral ligament attachment should be identified after entering the pes bursa. Once in the bursa, the surgeon should be able to identify the gracilis and semitendinosus tendons. Once freed of adhesions and exposed, the tendons are then harvested with an open hamstring tendon stripping device (Arthrex, Naples, FL), leaving them attached distally. The autograft tendons are cleaned to remove remaining muscle with the blade of a surgical scissor or an elevator.

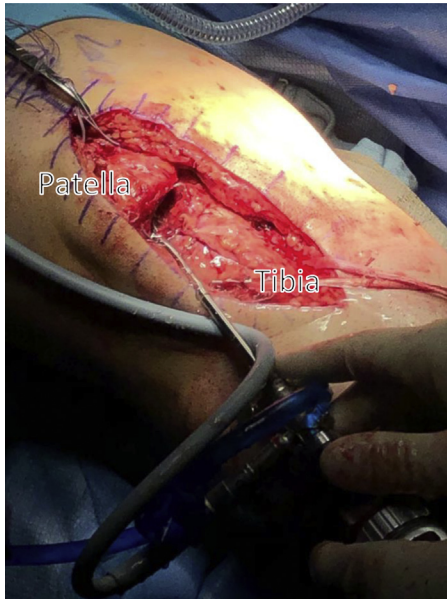
After harvesting the graft tendons, medial and lateral aspects of the tibial tubercle are exposed with a rongeur and No. 15 blade. Here, an anterior cruciate ligament tibial guide (Arthrex) is placed and used to drill a horizontal eyelet pin from medial to lateral through the tubercle before overreaming the tunnel with a 4.5-mm Endobutton reamer (Smith & Nephew, London, UK) ([Fig 2](#)). If the patient is skeletally immature, fluoroscopic guidance is recommended to place the tunnel just distal to the open physis ([Table 1](#)).<sup>1</sup> Because of the more posterior and lateral position of the semitendinosus insertion on the tibia, this tendon is pulled with a passing stitch through the tibial reconstruction tunnel from medial to lateral ([Table 2](#)).

A Q-Fix anchor (Smith & Nephew) is used to secure both the semitendinosus and gracilis tendons at the medial aperture of the tunnel and another to secure the semitendinosus tendon as it exits the tibial tunnel laterally. Channels are cleared along the longitudinal margins of the retracted remnant patellar tendon to facilitate later graft passage.

Medial and lateral aspects of the patella are identified, and once more the tibial anterior cruciate ligament guide is placed to drill a horizontal eyelet pin through the patella. An Endobutton reamer is again used to

**Table 1.** Pearls and Pitfalls for Patellar Tendon Reconstruction

Pearls	Pitfalls
Arthroscopy can be used to address intraarticular pathologies using the traumatic arthrotomy as a portal.	Keep the patellar tunnel as small a diameter as possible to minimize fracture risk.
Lysis of adhesions in the suprapatellar pouch can help improve patellar mobility and knee flexion, especially in revision cases.	Mobilize adhesions before using tendon stripper to avoid premature distal amputation of the tendon.
In skeletally immature patients, use fluoroscopy to drill a tibial tunnel just distal to the open physis.	Ensure adequate bone bridge at the tibial tubercle to avoid tunnel blowout.
Use a finger to protect patellar articular cartilage during tunnel drilling and overreaming.	Range the knee after suturing tendon to verify construct stability and identify postoperative range of motion.



**Fig 3.** The traumatic arthrotomy resultant from a patellar tendon tear can be used to access the joint space for chondroplasty or other intraarticular procedure during a patellar tendon reconstruction. The traumatic arthrotomy in this right knee is used as a portal for arthroscopy.

overream the eyelet pin in a manner similar to previously, with a finger kept over the articular cartilage for protection and to verify positioning at an appropriate depth. A passing stitch is placed (Fig 2).

If preoperative imaging, medical or surgical history, or clinical assessment raises suspicion for intraarticular pathology, arthroscopic management is appropriate at this point (Fig 3). We prefer to identify structures for revision

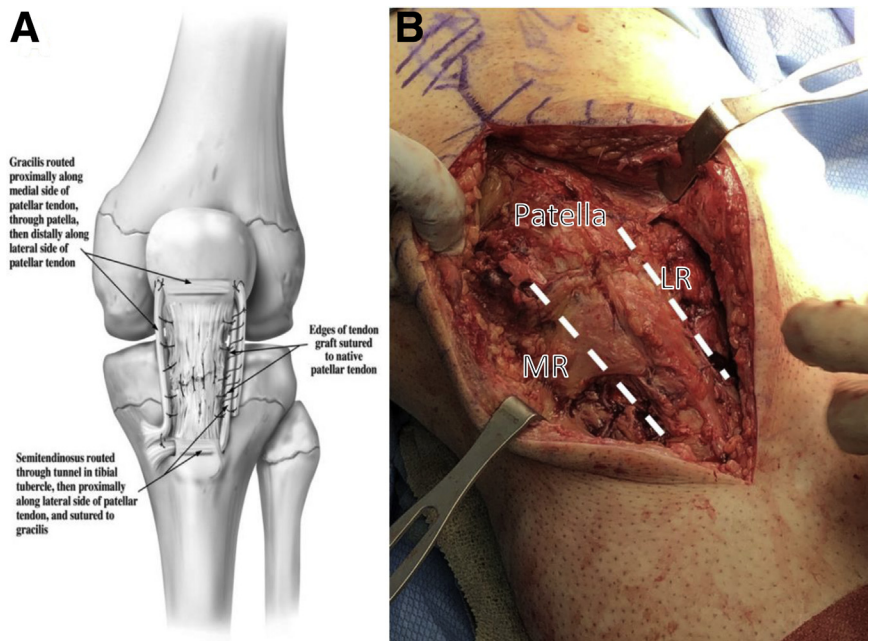
cases with an open approach before arthroscopy to avoid fluid extravasation, which can impede anatomic plane dissection. The patellar tendon rupture site may be used instead of a portal to examine and address defects in the anterior compartment, medial and lateral gutters, medial and lateral menisci, anterior and posterior cruciate ligaments, suprapatellar pouch, and patellofemoral articular cartilage. After addressing intraarticular pathology, fluid is evacuated from the joint.

The semitendinosus tendon is then passed from the point of exit from the tibial tunnel up the lateral channel, whereas the gracilis tendon is passed up the medial channel. The semitendinosus is then pulled from lateral to medial through the patellar tunnel using the passing stitch, whereas the gracilis tendon is passed from medial to lateral through the patella with a Hewson passer (Smith & Nephew) (Fig 4). A Kocher clamp is used to grasp the end of both grafts and to position the patellar tendon reconstruction to its correct length.

After repositioning the patella, Orthocord No. 2 sutures (DePuy Synthes, West Chester, PA) are used to tie the gracilis and semitendinosus tendons to one another. The remaining graft portions are passed proximal to distal through the lateral and medial channels and tied together distally. At this point, the surgeon should range the knee to ensure integrity of the reconstruction through 0 to 90 degrees of flexion.

The remnant patellar tendon is dissected out from any remaining fat pad and is repaired with 0 Vicryl (Ethicon, Inc. Somerville, NJ) sutures, depending on the location of the defect, to close the joint space. Flex the knee to 90 degrees to ensure that the reconstruction is stable for early postoperative range of motion.

**Fig 4.** Operative technique for an autogenous hamstring graft to reconstruct the patellar tendon. (A) Anteroposterior view schematic, left knee. (B) Intraoperative view, right knee. The gracilis and semitendinosus tendons are left intact at their pes anserinus insertion and wound in a box-like shape around the native tendon, traversing horizontal patellar and tibial tubercle bone tunnels.





**Table 2.** Advantages and Disadvantages for Patellar Tendon Reconstruction With Hamstring Autografts

Advantages	Disadvantages
Use of native tendons improves incorporation rate over allografts.	It is more challenging to appropriately tension the patella than in primary repair or free allograft reconstruction.
Keeping the tendons attached on the tibia makes a stronger construct that is better able to hold the patella in anatomic position.	Patellar tunnel creates a stress riser that runs the risk of blowout or fracture.
Using a tibial tunnel creates a strong inferior fixation with low risk of blowout.	

The tourniquet is released, deep tissues are closed with 0 and 2-0 Vicryl sutures, and skin is closed with a Monocryl (Ethicon, Inc., Somerville, NJ) subcuticular stitch. Steri-Strips (3M, Saint Paul, MN) may be loosely applied over the incision followed by sterile dressing and an immobilizer locked in full extension.

Postoperatively, the patient should remain strictly nonweightbearing for 6 weeks on the operative extremity. Flexion to 45 degrees is allowed for the first 2 weeks, then 0 to 90 degrees for the next 2 weeks and as tolerated after 4 weeks from surgery. Physical therapy should begin the day after surgery to ensure range of motion, prevent stiffness, promote quadriceps activation, and control edema. DVT prophylaxis with enoxaparin for 2 weeks is appropriate, followed by transition to aspirin and TED hose. Anteroposterior and lateral radiographs are obtained at postoperative day 1 to establish baseline patellar height and at 6 weeks prior to beginning weightbearing.

### Discussion

Patella tendon repair is a usually indicated for acute ruptures and is reported to have a high rate of success.<sup>3</sup> However, in circumstances where previous repair has failed, rerupture was caused by nontraumatic pathology such as systemic disease, significant obesity, or some combination of these factors. In this scenario, patellar tendon reconstruction may be necessary. With complete disruption of the extensor mechanism, conservative treatment may not be feasible because of severe disability and risk of adverse long-term consequences, including the development of patellofemoral osteoarthritis and chondromalacia patellae.<sup>1,5</sup>

It is important to perform repairs and reconstructions in the acute setting, because retraction may necessitate lengthening or shortening of the quadriceps tendon and extensive tissue release during reconstruction.<sup>5</sup> The hamstring reconstruction with circumferential placement of the autografts along the native tendon described in this report may be used to create a strong, stable construct with satisfactory restoration of extensor function or to reconstruct a previously failed repair.<sup>1</sup> A recent report described 13 patients with hamstring autograft patellar tendon reconstructions, demonstrating stability of flexion and extension, improvement

of Insall-Salvati index to 1.2, and improvement of mean Lysholm scores from 65 to 93 at a mean follow-up of 6 years using a similar method to the one described here.<sup>6</sup> A review in 2015 comparing patellar tendon repair and reconstruction techniques across 41 studies and 503 patients concluded that autograft reconstructions in the chronic setting had the lowest complication rates and best functional outcome scores.<sup>5</sup> Patellar tendon reconstruction with hamstring autograft ideally provides for early restoration of motion and usually results in favorable outcomes in terms of return to previous level of activity and strength.<sup>6-8</sup>

### References

1. LaPrade RF, Griffith CJ, Gilbert TJ. Intrasubstance stretch tear of a preadolescent patellar tendon with reconstruction using autogenous hamstrings. *Am J Sports Med* 2008;36:1410-1413.
2. Pires e Albuquerque R, Prado J, Hara R, et al. Epidemiological study on tendon ruptures of the knee extensor mechanism at a level 1 hospital. *Rev Bras Ortop* 2012;47:719-723.
3. Rose PS, Frassica FJ. Atraumatic bilateral patellar tendon rupture: A case report and review of the literature. *J Bone Joint Surg Am* 2001;83:1382-1386.
4. van Eijden TM, Weijs WA, Kouwenhoven E, Verburg J. Forces acting on the patella during maximal voluntary contraction of the quadriceps femoris muscle at different knee flexion/extension angles. *Acta Anat (Basel)* 1987;129:310-314.
5. Gilmore JH, Clayton-Smith ZJ, Aguilar M, Pneumaticos SG, Giannoudis PV. Reconstruction techniques and clinical results of patellar tendon ruptures: Evidence today. *Knee* 2015;22:148-155.
6. Valianatos P, Papadakou E, Erginoussakis D, Kampras D, Schizas N, Kouzoupis A. Treatment of chronic patellar tendon rupture with hamstrings tendon autograft. *J Knee Surg* 2020;33:792-797.
7. von Glinski A, Yilmaz E, Rausch V, et al. Semitendinosus autograft augmentation after bilateral patellar tendon rupture: A case report and technique note. *Eur J Orthop Surg Traumatol* 2019;29:1347-1353.
8. Maffulli N, Del Buono A, Loppini M, Denaro V. Ipsilateral hamstring tendon graft reconstruction for chronic patellar tendon ruptures: Average 5.8-year follow-up. *J Bone Joint Surg Am* 2013;95:e1231-e1236.