



Insights into treatment and outcome of fracture-related infection: a systematic literature review

H. Bezstarosti¹ · E. M. M. Van Lieshout¹ · L. W. Voskamp¹ · K. Kortram¹ · W. Obremskey² · M. A. McNally³ · W. J. Metsemakers⁴ · M. H. J. Verhofstad¹

Received: 12 September 2018 / Published online: 20 October 2018
© The Author(s) 2018

Abstract

Introduction Standardized guidelines for treatment of fracture-related infection (FRI) are lacking. Worldwide many treatment protocols are used with variable success rates. Awareness on the need of standardized, evidence-based guidelines has increased in recent years. This systematic literature review gives an overview of available diagnostic criteria, classifications, treatment protocols, and related outcome measurements for surgically treated FRI patients.

Methods A comprehensive search was performed in all scientific literature since 1990. Studies in English that described surgical patient series for treatment of FRI were included. Data were collected on diagnostic criteria for FRI, classifications used, surgical treatments, follow-up protocols, and overall outcome. A systematic review was performed according to the PRISMA statement. Proportions and weighted means were calculated.

Results The search yielded 2051 studies. Ninety-three studies were suitable for inclusion, describing 3701 patients (3711 fractures) with complex FRI. The population consisted predominantly of male patients (77%), with the tibia being the most commonly affected bone (64%), and a mean of three previous operations per patient. Forty-three (46%) studies described FRI at one specific location. Only one study (1%) used a standardized definition for infection. A total of nine different classifications were used to guide treatment protocols, of which Cierny and Mader was used most often (36%). Eighteen (19%) studies used a one-stage, 50 (54%) a two-stage, and seven (8%) a three-stage surgical treatment protocol. Ten studies (11%) used mixed protocols. Antibiotic protocols varied widely between studies. A multidisciplinary approach was mentioned in only 12 (13%) studies.

Conclusions This extensive literature review shows a lack of standardized guidelines with respect to diagnosis and treatment of FRI, which mimics the situation for prosthetic joint infection identified many years ago. Internationally accepted guidelines are urgently required to improve the quality of care for patients suffering from this significant complication.

Keywords Fracture-related infection · Outcome measurements · Diagnosis · Treatment · Definition · Classification

Introduction

Fracture-related infection (FRI) is a serious complication related to musculoskeletal trauma. It can have a devastating impact on a patient's quality of life and has huge socio-economic consequences [1]. Patients are often not only unable to participate in social activity due to their limited mobility and function. They also encounter higher direct and indirect health care costs. The results from a recent cost analysis showed that the hospital-related health care costs of infected cases are approximately 6.5-times higher than for non-infected cases, which is much higher than data that were previously published [2–4]. These results stress the

✉ M. H. J. Verhofstad
m.verhofstad@erasmusmc.nl

¹ Trauma Research Unit Department of Surgery, Erasmus MC, University Medical Center Rotterdam, P.O. Box 2040, 3000 CA Rotterdam, The Netherlands

² Vanderbilt University, Nashville, USA

³ Nuffield Orthopaedic Centre, Oxford University Hospitals, Oxford, UK

⁴ Department of Trauma Surgery, University Hospitals Leuven, Leuven, Belgium

importance of standardized prevention and treatment guidelines, with respect to this serious complication.

Since the beginning of the twentieth century the cornerstones of treatment have been extensive and multiple debridements with dead space management and soft tissue coverage [5]. Antibiotic therapy was added as technology progressed. Now almost a 100 years later, a wide variety of strategies is used (e.g., 1 stage, 2 stage, Masquelet, RIA, Ilizarov methods, different types of local antibiotics) without clear scientific background, resulting in a wide spread of clinical results. The rate of FRI remains at 20–30%, with a reported overall treatment failure of 4–11% [6–8].

The aim of this review was to give an overview of the diagnostic criteria, classifications, surgical and follow-up protocols, and success rates of all FRI treatment series published over the last decades.

Methods

This study was written according to the Preferred Reporting Items for Systematic Reviews and Meta-Analyses (PRISMA) statement [9].

Literature search strategy

A comprehensive search was performed with the help of a biomedical information specialist in October 2016 and updated on July 1 2017, using Medline, Embase, Web of Science, Cochrane, and Google Scholar. The search strings are recorded in Appendix 1. All studies that described surgical patient series for treatment of FRI were included. Series needed to be greater than five patients and reported in English. Publications before 1990, studies that did not describe FRI patient treatment, and publications reporting non-original data (e.g., reviews or meta-analyses) were excluded. Inclusion consisted of two phases. During the first phase title and abstract were screened for relevance, and full text articles were obtained. When a full text was not available, the corresponding author was contacted once by email. Full text articles were reviewed in the second phase. All references were reviewed by HB and LWV and included after matching the inclusion criteria. Consensus was reached on all references.

Data extraction

After inclusion, data from each study was independently extracted by two authors (HB and LWV). Disagreements were discussed until agreement was reached. Data were collected in five areas. Part one provided general information from all studies (sample size, age, FRI, and location of FRI). Part two offered information on diagnostic

criteria for FRI (given definition of FRI, used classification of FRI, and parameters describing the outcome parameters of FRI).

Part Three focused on data from surgical protocols (number of stages in surgical protocol, type of fixation used, and use of a multidisciplinary approach). Part four described the treatment concept (bone defect size, exact treatment protocol, use of bone, skin or muscle graft, and use of local antibiotics). Part five included the follow-up protocol (bony consolidation without infection after the primary surgical study protocol (primary healing), bony consolidation or amputation without infection at the end of study period (total healing), recurrence of FRI, amputation of the affected limb, number of complications, revision surgery, time to bony union and Hospital Length of Stay (HLOS) and patient reported outcomes).

Analysis

Results were pooled for the total population presented in the included studies. Binomial data were pooled using Medcalc (MedCalc Statistical Software version 17.9.7) (MedCalc Software bvba, Ostend, Belgium; <http://www.medcalc.org>; 2017). Heterogeneity was quantified with Cochran's Q test and I^2 statistic, a fixed effects model was used when the I^2 was $< 40\%$. A random effects model was used for the pooled analysis when the heterogeneity test was $\geq 40\%$. Pooled estimates are reported with their 95% confidence intervals (CI).

Since for continuous data, most studies only provided a mean but not the standard deviation, a full meta-analysis was not feasible. Instead, continuous data were pooled by calculating the weighted mean using Microsoft Excel. Sample size of the individual studies was used as weighting factor. The pooled mean is reported with the range.

Results

The search identified a total of 2051 unique studies. Figure 1 shows the inclusion flowchart. After selection, 93 studies [8, 10–101] remained for inclusion, describing 3701 patients with 3711 FRI's. The population consisted predominantly of male patients ($n = 2656$; 77%), with a mean age of 42 (range 6–95) years, a mean infection duration of 28 (range 0–154) months and a mean follow-up of 42 (range 6–101) months. Patients had a mean of 3 (range 0–31) operations before study inclusion. Of all studies, 43 described FRI at one specific location. Table 1 shows the reported locations of FRI, with the tibia being the most commonly affected site ($n = 2533$; 64%), followed by the femur ($n = 599$; 16%).

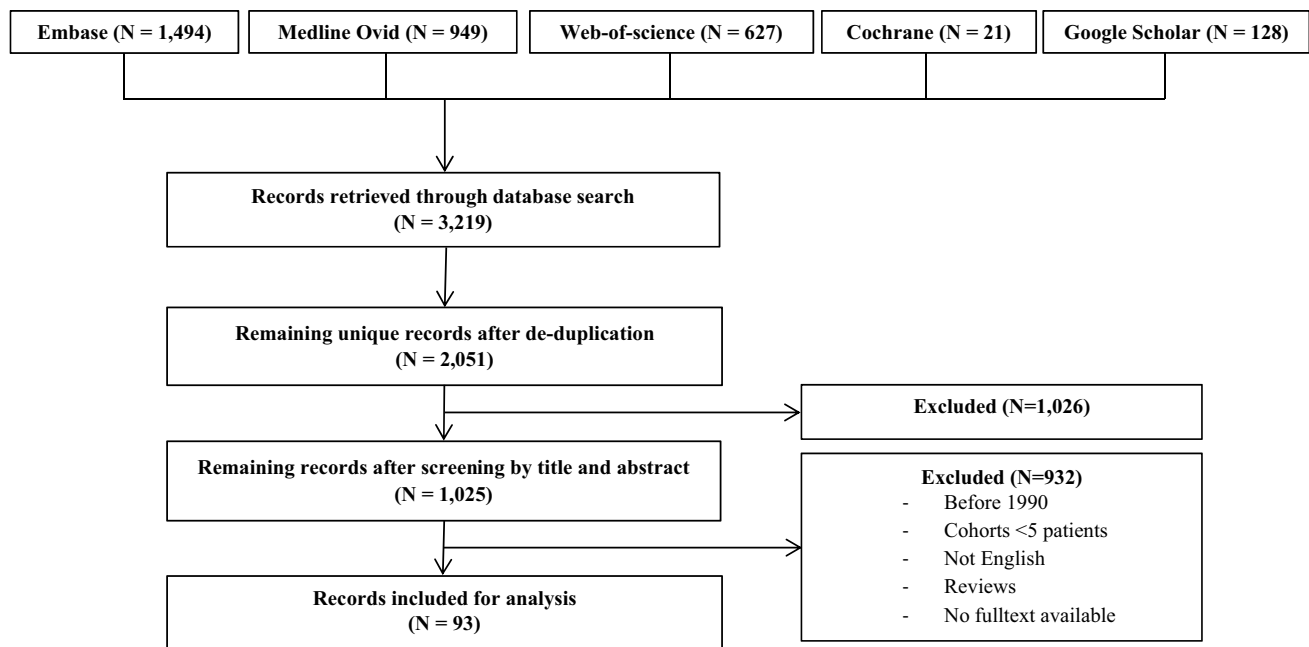


Fig. 1 Flowchart of the study

Table 1 Overview of locations of FRI

Location of FRI	All studies, <i>N</i> = 3711
Tibia	2533 (68.3%)
Femur	599 (16.1%)
Ankle	124 (3.3%)
Calcaneus	77 (2.1%)
Foot	63 (1.7%)
Humerus	59 (1.6%)
Knee	49 (1.3%)
Fibula	30 (0.8%)
Radius	24 (0.6%)
Forearm	24 (0.6%)
Ulna	18 (0.5%)
Ilium	13 (0.4%)
Elbow	11 (0.3%)
Clavicle	4 (0.1%)
Spine	1 (0.0%)
Skull	1 (0.0%)
Not specified	197 (5.3%)
Lower extremity not defined	41 (1.1%)
Upper extremity not defined	21 (0.6%)

Diagnosis and classification

An overview of all criteria used to diagnose and/or define FRI is given in Table 2. Diagnostic criteria to define FRI were found in 85 (91%) studies. Clinical ($n = 83$; 89%) and

Table 2 Overview of parameters used to diagnose or define FRI

Parameters associated with FRI	Number of studies, <i>N</i> = 93
Clinical signs	
Purulent drainage (or discharge)	34 (37%)
Dolor (pain)	14 (15%)
Tumor (swelling)	9 (10%)
Calor (warmth)	8 (9%)
Rubor (redness)	7 (8%)
Wound dehiscence/breakdown	7 (8%)
Fever	5 (5%)
Unspecified	46 (49%)
Laboratory testing	
C-reactive protein (CRP)	17 (18%)
Unspecified	9 (10%)
Radiological signs	
Signs of osteomyelitis	62 (67%)
Evidence of non-union	34 (37%)
Bacteriological/histological findings	
Cultures taken	56 (60%)
Unspecified histology	17 (18%)
Unspecified bacteriology	15 (16%)
Other	
Time of infection	27 (29%)
No parameters for diagnosis given	8 (9%)

Table 3 Classifications used to define FRI

Classification System	Number of studies, <i>N</i> =47
Cierny-Mader classification	34 (72%)
May's classification	4 (9%)
Jain and Sinha's modified May classification	2 (4%)
Calori's classification for non-union	1 (2%)
CDC guidelines for wound infection	1 (2%)
Osteomyelitis diagnosis score	1 (2%)
UTMB staging system for adult osteomyelitis	1 (2%)
Weiland classification	1 (2%)
Yang's classification for bone defects	1 (2%)
Ziran's algorithm for acute infection after ORIF	1 (2%)

Table 4 Periods defined in classification of FRI

Time frame	Number of studies <i>N</i> =93
Chronic infection	12 (13%)
> 6 weeks	3 (3%)
> 12 weeks	3 (3%)
> 4 months	2 (2%)
> 6 months	4 (4%)
Infected non-union	12 (13%)
> 3 months	1 (1%)
> 4 months	1 (1%)
> 6 months	9 (10%)
> 12 months	1 (1%)
Multiple divisions	3 (3%)
Acute < 2 weeks, Subacute 2–6 weeks, Chronic > 6 weeks	1 (1%)
Acute < 30 days, Subacute 1–6 months, Chronic > 6 months	2 (2%)
No period of time mentioned	66 (71%)

radiological signs ($n = 73$; 78%) were mostly included in the diagnosis of FRI.

An overview of all described classifications is given in Table 3. A total number of ten different classifications to define infection were found in 47 (51%) studies. The classification of Cierny-Mader was most widely used ($N = 34$; 37%). The duration of the infection was part of infection classifications in 27 (29%) studies. An overview of all time periods recorded in defining FRI can be found in Table 4. Chronic osteomyelitis was described as an infection-period longer than 6 months in four studies (4%), a period of more than 12 weeks in three studies (3%), a period of more than 6 weeks in three studies (3%), and a period longer than 2 months in two studies (2%). Infected non-union was

also classified according to time in 12 studies, of which nine (10%) used 6 months as a cutoff.

Finally, three studies (3%) subdivided infection into three time periods (acute, subacute and chronic). Of all studies, 66 (71%), did not mention time in the classification of FRI.

Surgical protocols

An overview of surgical protocols is given in Table 5. Surgical treatment protocols differed widely across all studies. Overall, 41 (44%) studies described a FRI located in a single anatomic location, compared with 52 (56%) studies, where multiple locations were described.

A two-stage surgical procedure was used in 50 (54%) studies, followed by a one-stage procedure in 18 (19%), and a three-stage protocol in seven (8%) studies.

Most of the included studies (34; 37%) described a mixture of fracture/bone fixation techniques. Single techniques described were external fixation without bone transport in 27 (29%), followed by external fixation with bone transport in 14 (15%), and internal fixation in twelve (13%). Treatment of bone defects larger than 1 cm were described in 41 (44%) studies.

A multidisciplinary approach in the treatment of FRI was mentioned in 12 (13%) studies, mostly mentioning a team consisting of a trauma or orthopedic surgeon in combination with a plastic surgeon and/or infectious disease (ID) specialist. The different specialties collaborating in such a multidisciplinary team are summarized in Table 6.

Treatment specifications

An overview of bone grafts used in the treatment of FRI is given in Table 7.

In 62 (67%) studies a total of 1418 bone grafts were described to treat FRI, of which 555 (39%) were cancellous and 381 (27%) were free vascularized bone grafts.

Table 8 summarizes all means by which soft tissue reconstruction was achieved. In 41 (44%) studies a total of 1171 methods to reconstruct soft tissue were described, of which 460 (39%) free flaps, 247 (21%) skin grafts, and 125 (11%) rotational flaps. Local antibiotic therapy was used in 51 (55%) studies. Systemic or oral antibiotic treatment regimens differed widely across studies and will be discussed elsewhere.

Follow-up protocols

Details on all parameters used in follow-up of FRI can be found in Table 9.

Routine follow-up episodes were defined in 26 (28%) studies, describing clearly defined appointment protocols in 14 (15%) of them. Follow-up parameters used to identify

Table 5 Surgical Protocol and Type of Fixation

Number of stages	Number of studies, <i>N</i> =93
One-stage	18 (19%)
Two-stage	50 (54%)
Three-stage	7 (8%)
Combination of the above	10 (11%)
Unknown	16 (17%)
Type of fixation	Number of studies, <i>N</i> =93
Internal	12 (13%)
External	27 (29%)
Bone transport	14 (15%)
Mixed protocols	34 (37%)
Unknown	14 (15%)

Table 6 Multidisciplinary approach in treatment of FRI

Specialists involved	Number of studies, <i>N</i> =12
Trauma/orthopedic surgeon	10 (83%)
Infectious disease specialist	5 (42%)
Plastic surgeon	5 (42%)
Pharmacist	1 (8%)
Radiologist	1 (8%)
Team not defined	3 (25%)

Table 7 Bone grafts used in treatment of FRI

Graft type used (62 studies)	<i>N</i> =1418 (% of total)
Cancellous bone	555 (39)
Iliac crest	445 (31)
RIA (with BMP-7)	76 (5)
Tibia condyle	25 (2)
Femur condyle	9 (1)
Vascularized bone	381 (27)
Vascularized fibula	322 (23)
Latissimus dorsi with rib	41 (3)
Vascularized ilium	18 (1)
Other	27 (2)
Graft not defined	455 (32)

disease recurrence were based on radiology (*N*=49; 53%), serology (*N*=32; 34%), and clinical signs (*N*=31; 33%).

Two different scoring systems to describe bone quality were found in five (5%) studies. In 19 (20%) studies a functional outcome scoring system was used, describing 13 different functional outcome scores.

Table 8 Muscle and skin flaps used in treatment of FRI

Total (41 studies)	<i>N</i> =1171 (% of total)
Free flap	460 (39)
Latissimus dorsi	206 (18)
Not defined	82 (7)
Gracilis	64 (5)
Rectus abdominis	47 (4)
Scapular skin flap	23 (2)
Serratus anterior	23 (2)
Lateral thigh	15 (1)
Rotational flap	125 (11)
Gastrocnemius	52 (4)
Saphenous	50 (4)
Soleus	23 (2)
Skin	247 (21)
Split skin graft	232 (20)
Full thickness skin graft	15 (1)
Other	76 (1)
Skin/muscle not defined	200 (17)

Surgical outcome

A summary of surgical outcome is detailed in Table 10. Of all 3711 reported complex FRI cases, bone healing and eradication of infection, without recurrence, was reported in 85% (95% CI 82–88) after the primary surgical study protocol. This percentage increased to 93% (95% CI 91–94) if repeated treatment protocols, including amputations, were taken into account. In 3% (95% CI 3–5) of all cases, amputation was deemed necessary to treat FRI. Recurrence of infection was seen in 9% (95% CI 7–11).

A total of 0.39 complications per patient were reported, for which 0.31 surgical revisions per patient were needed. Furthermore, bone healing was achieved in a mean of 7 months (2–15), and patients stayed in the hospital for a mean of 1.39 months (0–3).

Discussion

To our knowledge this is the first extensive review showing a complete overview of treatment and outcome of FRI from 1990 until 2017. A literature search has been performed, including 93 articles describing mostly retrospective series of FRI treatment in 3701 patients.

Treatment principles were described by five items. Diagnosis and classification, surgical protocol, treatment concept, follow-up protocol, and outcome, all showed a clear lack of consensus on diagnosis and treatment guidelines for FRI.

Table 9 Parameters used during follow-up of FRI

Parameter	Number of studies, <i>N</i> = 93
Predefined routine follow-up episodes	26 (28%)
Clinical signs of infection	31 (33%)
Routine radiological check up	49 (53%)
Blood biomarkers	32 (34%)
C-reactive protein	12 (13%)
Erythrocyte sedimentation rate	10 (11%)
Leucocyte count	4 (4%)
Complete blood count	2 (2%)
Undefined	4 (4%)
Bone scoring systems	5 (5%)
ASAMI	4 (4%)
Bahr score	1 (1%)
Functional outcome scoring systems	19 (20%)
Self-defined functionality scores	5 (5%)
Paley's functionality score	3 (3%)
American orthopaedic foot and ankle society score	1 (1%)
EuroQol 5D	1 (1%)
Johner-Wruhs evaluation criteria	1 (1%)
Lower extremity functionality scale	1 (1%)
Ma's knee score	1 (1%)
Mazur's ankle evaluation grading system	1 (1%)
Merchant and Dietz score	1 (1%)
SF-12	1 (1%)
SF-36	1 (1%)
Shahcheraghi and Bayatpoor evaluation score	1 (1%)
Stewart and Hundley criteria	1 (1%)

This mirrors the situation for Prosthetic Joint Infection (PJI), identified many years ago [102].

It seems that basic management concepts of FRI treatment have not altered much since the beginning of the twentieth century [5], resulting in possible suboptimal care for FRI patients. The next section will discuss the discrepancies identified in the five specific domains.

Diagnostic criteria and classification

This study shows that diagnostic criteria to define FRI were mentioned in 91% of all included studies, but no consensus exists on which parameters are relevant. Furthermore, only one study used a standardized definition for FRI (e.g., CDC guidelines) out of 47 studies using a definition. This is in line with conclusions of a previous review of 100 randomized clinical trials aimed at defining FRI [103].

A survey among 2327 orthopedic trauma surgeons in 2017 also confirmed that no consensus exists with respect to which diagnostic criteria should be used to define FRI and almost 90% of the respondents were convinced that a consensus-derived definition of FRI is urgently necessary [104].

Multiple time-related classifications were described in the literature that subdivide FRI into discrete groupings such as acute and chronic infections, or early, delayed and late onset infections [105–107].

These time windows are, to the best of our knowledge, not based on scientific evidence. This supports the view that they are poorly defined for FRI (e.g., time since injury, or time since onset of symptoms) and somewhat arbitrary (e.g., a 6 week transition from acute to chronic infection [108]). This review confirms that a variety of time windows is used to classify infection and that only 27 (29%) studies reported

Table 10 Outcomes of FRI treatment

Proportional variable	Studies (<i>N</i>)	FRI (<i>N</i>)	Chi ² (<i>p</i> value)	<i>I</i> ² value (95% CI)	Pooled proportion (95% CI)
Primary healing	93	3711	*	81% (77–84)	85% (82–88)
Total healing	92	3695	*	77% (72–81)	93% (91–94)
Infection recurrence	89	3598	*	73% (66–78)	9% (7–11)
Amputation rate	83	3226	*	50% (35–61)	3% (3–5)
Continuous variable	Studies (<i>N</i>)	Patients (<i>N</i>)			Weighted mean ^b
Union time (months)	47	1809			6.63
Surgical revisions ^a	58	2110			0.31
Complications ^a	84	3436			0.38
HLOS (months)	14	415			1.39

**p* < 0.0001

^aPer patient

^bSince most of the individual studies did not report a standard deviation (SD) or standard error, no pooled SD could be provided

time in the classification of infection, suggesting that it is not a widely accepted parameter.

The aim of this review was to map all available diagnostic criteria and classifications used when describing patients treated for FRI. Given there are so many different views and no standardized criteria available, an equal comparison is not possible between studies. In the future this can and could be improved if researchers implement the recently developed consensus definition for FRI [108].

Surgical protocols

This systematic review shows an enormous heterogeneity in treatment protocols. In 52 (56%) of all included studies, multiple anatomic locations are mentioned. Furthermore, different treatment strategies are described (e.g., one-stage, two stage). This means that pooling of data related to outcome of these studies was not possible.

Twelve (13%) of the studies included, made use of a multidisciplinary approach to treat FRI. In these cases, a wide spectrum of team members were described, which also confirms the lack of consensus within this field. Recent literature shows that collaboration between multiple departments is essential to improve the outcome in FRI patients, not only with respect to treatment but also for prevention [109–114].

Treatment specifications

As discussed before, this review identified many different treatment strategies for different types of FRI. As a consequence, different success rates were published. Due to heterogeneity it is almost impossible to compare outcome between studies. One explanation for this wide variety of published treatment strategies could be the lack of a consensus in the orthopedic trauma community regarding these strategies to manage FRI [103].

Follow-up protocols

Protocolled follow-up of FRI patients was mentioned in 28% of all studies, showing a wide variety of parameters used in monitoring infection and functional outcome. No consensus exists on proper follow-up for this patient population, again emphasizing the need for international consensus. A recent overview confirms the importance of a well-defined follow-up in stratifications of patients [115].

Surgical outcome

Included patients had a mean of three previous operations per patient before inclusion in the identified studies, further emphasizing the difficulty of FRI treatment. However,

treatment failure and recurrence of disease rates found in this review occurred in 6–9% of all included cases, leading to amputation of the affected limb in 3–5%, which is a lower percentage than previously published [6–8]. This could be explained by underreporting of bad outcome, since surgeons tend to publish successful cases more easily than failures. Such publication bias is often seen in retrospective cohort series, which made up the majority of the series.

The patient-related outcome was calculated as a weighted mean of all included studies, including all available treatment options on different locations of FRI and different lengths of bone defects. Therefore, this outcome is in no way specific and it may only be seen as an overview of various patient-related outcomes in current studies.

Limitations

This review was performed using a literature search with respect to FRI, based on terms that existed before a widely used definition of FRI was available. The lack of a definition makes it difficult to compare studies. In March 2018 a consensus definition of FRI from an international expert group has been published [108], finally offering the possibility to standardize reports and improve published literature.

In 66 (71%) of all studies no timescale was reported for infection, limiting the possibility to give a reliable overview of acute/early/delayed-onset FRI.

A better methodological quality in describing patient series is an absolute must, so comparison between series is possible ultimately leading to improvement of treatment.

We need to organize published work in such a way that comparison of either different surgical protocols or different types of FRI treated with the same surgical protocol is possible, further emphasizing the need for a uniform consensus on diagnosis and treatment of FRI.

Most series published do not provide information on individual patients, and do not supply median and standard deviation for any variable needed to perform statistical comparison between studies. To improve comparative analysis of the literature in the future, there is a need for a standard scientific notation of published data, ultimately leading to improvement in treatment strategies.

Conclusion

This extensive literature review shows that the majority of studies report diagnostic criteria for FRI, and half of all studies describe FRI with a definition. There is an enormous heterogeneity of disease variation in and between reported patient series, surgical treatment protocols, and a

lack of follow-up reports. This confirms the lack of standardized guidelines with respect to diagnosis and treatment of FRI, and mimics the situation for PJI identified many years ago. Standardized reporting and internationally accepted guidelines are urgently required to improve research and ultimately the quality of care for patients suffering from this significant and sometimes devastating complication.

Acknowledgements The authors thank Mr. Wichor M. Bramer, biomedical information specialist (Erasmus MC, University Medical Center Rotterdam, Rotterdam, The Netherlands), for his help in conducting the systematic literature search.

Funding There is no funding source.

Compliance with ethical standards

Conflict of interest The authors have no conflicts of interest to disclose.

Ethical approval This article does not contain any studies with human participants or animals performed by any of the authors.

Informed consent Informed consent was not applicable in this study.

Open Access This article is distributed under the terms of the Creative Commons Attribution 4.0 International License (<http://creativecommons.org/licenses/by/4.0/>), which permits unrestricted use, distribution, and reproduction in any medium, provided you give appropriate credit to the original author(s) and the source, provide a link to the Creative Commons license, and indicate if changes were made.

Appendix 1: Search terms used for the individual databases

a. **Medline OVID:** (“osteitis”/ OR “osteomyelitis”/ OR (osteitis OR osteomyelitis).ab,ti.) AND (exp “Fractures, Bone”/ OR (fracture* OR nonunion* OR malunion* OR nonunited* OR malunited* OR posttraum* OR posttraum*).ab,ti.) AND (“Surgical Procedures, Operative”/ OR “debridement”/ OR osteitis/su OR osteomyelitis/su OR (surger* OR surgic* OR debridement*).ab,ti.) AND (“observational study”/ OR exp “Cohort Studies”/ OR “Case-Control Studies”/ OR “Cross-Sectional Studies”/ OR “multicenter study”/ OR “comparative study”/ OR “clinical study”/ OR exp “clinical trial”/ OR “Random Allocation”/ OR exp “treatment outcome”/ OR (((observation* OR comparativ*) ADJ6 (stud* OR data OR research)) OR cohort* OR longitudinal* OR retrospectiv* OR prospectiv* OR ((case OR cases OR match*) ADJ3 control*) OR (cross ADJ section*) OR correlation* OR multicenter* OR multi-center* OR follow-up* OR followup* OR clinical* OR trial OR random* OR (treatment ADJ3 (outcome* OR fail* OR success*))).

ab,ti.) NOT (letter OR news OR comment OR editorial OR congresses OR abstracts).pt. AND english.la.

b. **Embase:** (“osteitis”/de OR “osteomyelitis”/de OR “chronic osteomyelitis”/de OR (osteitis OR osteomyelitis):ab,ti) AND (“fracture”/exp OR “post-traumatic complication”/de OR (fracture* OR nonunion* OR malunion* OR nonunited* OR malunited* OR posttraum* OR post-traum*):ab,ti) AND (“surgery”/de OR “surgical technique”/de OR “debridement”/de OR “osteitis”/exp/dm_su OR (surger* OR surgic* OR debridement*):ab,ti) AND (“observational study”/exp OR “cohort analysis”/exp OR “longitudinal study”/exp OR “retrospective study”/exp OR “prospective study”/exp OR “case control study”/de OR “cross-sectional study”/de OR “correlational study”/de OR “major clinical study”/de OR “multicenter study”/de OR “comparative study”/de OR “follow up”/de OR “clinical study”/de OR “clinical article”/de OR “clinical trial”/exp OR “randomization”/exp OR “intervention study”/de OR “open study”/de OR “treatment outcome”/exp OR (((observation* OR comparativ*) NEAR/6 (stud* OR data OR research)) OR cohort* OR longitudinal* OR retrospectiv* OR prospectiv* OR ((case OR cases OR match*) NEAR/3 control*) OR (cross NEXT/1 section*) OR correlation* OR multicenter* OR multi-center* OR follow-up* OR followup* OR clinical* OR trial OR random* OR (treatment NEAR/3 (outcome* OR fail* OR success*)):ab,ti) NOT ([Conference Abstract]/lim OR [Letter]/lim OR [Note]/lim OR [Editorial]/lim) AND [english]/lim

c. **Web of Science:** TS=(((osteitis OR osteomyelitis)) AND ((fracture* OR nonunion* OR malunion* OR nonunited* OR malunited* OR posttraum* OR posttraum*)) AND ((surger* OR surgic* OR debridement*)) AND (((observation* OR comparativ*) NEAR/5 (stud* OR data OR research)) OR cohort* OR longitudinal* OR retrospectiv* OR prospectiv* OR ((case OR cases OR match*) NEAR/2 control*) OR (cross NEAR/1 section*) OR correlation* OR multicenter* OR multicenter* OR follow-up* OR followup* OR clinical* OR trial OR random* OR (treatment NEAR/2 (outcome* OR fail* OR success*)))) AND DT=(article) AND LA=(english)

d. **Cochrane:** ((osteitis OR osteomyelitis):ab,ti) AND ((fracture* OR nonunion* OR malunion* OR nonunited* OR malunited* OR posttraum* OR posttraum*):ab,ti) AND ((surger* OR surgic* OR debridement*):ab,ti)

e. **Google scholar:** “posttraumatic|traumatic osteitis|osteomyelitis” surgery|surgical|debridement all intitle:”posttraumatic|traumatic osteitis|osteomyelitis” surgery|surgical|debridement

References

- Metsemakers WJ, Kuehl R, Moriarty TF, Richards RG, Verhofstad MHJ, Borens O, Kates S, Morgenstern M (2018) Infection after fracture fixation: current surgical and microbiological concepts. *Injury* 49(3):511–522
- Metsemakers WJ, Smeets B, Nijs S, Hoekstra H (2017) Infection after fracture fixation of the tibia: analysis of healthcare utilization and related costs. *Injury* 48(6):1204–1210
- Olesen UK, Pedersen NJ, Eckardt H, Lykke-Meyer L, Bonde CT, Singh UM, McNally M (2017) The cost of infection in severe open tibial fractures treated with a free flap. *Int Orthop* 41(5):1049–1055. <https://doi.org/10.1007/s00264-016-3337-6>
- Thakore RV, Greenberg SE, Shi H, Foxx AM, Francois EL, Prablek MA, Nwosu SK, Archer KR, Ehrenfeld JM, Obremsky WT, Sethi MK (2015) Surgical site infection in orthopedic trauma: a case-control study evaluating risk factors and cost. *J Clin Orthop Trauma* 6(4):220–226
- Whire JR (1919) Chronic Traumatic Osteomyelitis, its pathology and treatment. First published. Lewis, Boca Raton
- Kanakaris N, Gudipati S, Tosounidis T, Harwood P, Britten S, Giannoudis PV (2014) The treatment of intramedullary osteomyelitis of the femur and tibia using the Reamer-Irrigator-Aspirator system and antibiotic cement rods. *Bone Joint J* 96-B(6):783–788
- Huh J, Stinner DJ, Burns TC, Hsu JR, Late Amputation Study T (2011) Infectious complications and soft tissue injury contribute to late amputation after severe lower extremity trauma. *J Trauma* 71(1 Suppl):S47–S51
- Bose D, Kugan R, Stubbs D, McNally M (2015) Management of infected nonunion of the long bones by a multidisciplinary team. *Bone Joint J* 97B(6):814–817
- Moher D, Liberati A, Tetzlaff J, Altman DG, Group P (2009) Preferred reporting items for systematic reviews and meta-analyses: the PRISMA statement. *Ann Intern Med* 151(4):264–269
- Anthony JP, Mathes SJ, Alpert BS (1991) The muscle flap in the treatment of chronic lower-extremity osteomyelitis—results in patients over 5 years after treatment. *Plast Reconstr Surg* 88(2):311–318
- Aytaç S, Schnetzke M, Swartman B, Herrmann P, Woelfl C, Heppert V, Gruetzner PA, Guehring T (2014) Posttraumatic and postoperative osteomyelitis: surgical revision strategy with persisting fistula. *Arch Orthop Trauma Surg* 134(2):159–165. <https://doi.org/10.1007/s00402-013-1907-2>
- Barbarossa V, Matković BR, Vučić N, Bielen M, Gluhinić M (2001) Treatment of osteomyelitis and infected non-union of the femur by a modified Ilizarov technique: follow-up study. *Croat Med J* 42(6):634–641
- Beals RK, Bryant RE (2005) The treatment of chronic open osteomyelitis of the tibia in adults. *Clin Orthop Relat Res* 433:212–217. <https://doi.org/10.1097/01.blo.0000150462.41498.fe>
- Caesar BC, Morgan-Jones RL, Warren RE, Wade RH, Roberts PJ, Richardson JB (2009) Closed double-lumen suction irrigation in the management of chronic diaphyseal osteomyelitis: long-term follow-up. *J Bone Jt Surg Ser B* 91(9):1243–1248. <https://doi.org/10.1302/0301-620x.91b9.21768>
- Calhoun JH, Henry SL, Anger DM, Cobos JA, Mader JT (1993) The treatment of infected nonunions with gentamicin-poly-methylmethacrylate antibiotic beads. *Clin Orthop Relat Res* (295):23–27
- Campbell R, Berry MG, Deva A, Harris IA (2011) Aggressive management of tibial osteomyelitis shows good functional outcomes. *Eplasty* 11:e3
- Chadayammuri V, Herbert B, Hao J, Mavrogenis A, Quispe JC, Kim JW, Young H, Hake M, Mauffrey C (2017) Factors associated with adverse postoperative outcomes in patients with long bone post-traumatic osteomyelitis. *Eur J Orthop Surg Traumatol* 27:877. <https://doi.org/10.1007/s00590-017-1962-4>
- Chan YS, Ueng SWN, Wang CJ, Lee SS, Chao EK, Shin CH (1998) Management of small infected tibial defects with antibiotic-impregnated autogenic cancellous bone grafting. *J Trauma Inj Infect Crit Care* 45(4):758–764. <https://doi.org/10.1097/00005373-199810000-00023>
- Chen CE, Ko JY, Pan CC (2005) Results of vancomycin-impregnated cancellous bone grafting for infected tibial nonunion. *Arch Orthop Trauma Surg* 125(6):369–375. <https://doi.org/10.1007/s00402-005-0794-6>
- Chen CE, Ko JY, Wang JW, Wang CJ (2003) Infection after intramedullary nailing of the femur. *J Trauma Inj Infect Crit Care* 55(2):338–344. <https://doi.org/10.1097/01.ta.0000035093.56096.3c>
- Chen CM, Su AW, Chiu FY, Chen TH (2010) A surgical protocol of ankle arthrodesis with combined ilizarov's distraction-compression osteogenesis and locked nailing for osteomyelitis around the ankle joint. *J Trauma Inj Infect Crit Care* 69(3):660–665. <https://doi.org/10.1097/TA.0b013e3181bc01e6>
- Chim H, Sontich JK, Kaufman BR (2011) Free tissue transfer with distraction osteogenesis is effective for limb salvage of the infected traumatized lower extremity. *Plast Reconstr Surg* 127(6):2364–2372
- Choudry UH, Bakri K, Moran SL, Karacor Z, Shin AY (2008) The vascularized medial femoral condyle periosteal bone flap for the treatment of recalcitrant bony nonunions. *Ann Plast Surg* 60(2):174–180. <https://doi.org/10.1097/SAP.0b013e318056d6b5>
- Cierny Iii G (1999) Infected tibial nonunions (1981–1995). The evolution of change. *Clin Orthop Relat Res* (360):97–105
- Conway J, Mansour J, Kotze K, Specht S, Shabtai L (2014) Antibiotic cement-coated rods: an effective treatment for infected long bones and prosthetic joint nonunions. *Bone Joint J* 96-B(10):1349–1354
- de Souza FI, Zumiotti AV, Mattar R, Wei TH, de Resende MR, Torres LR (2009) Use of gastrocnemius muscle on treatment of infected injuries of the knee. *Acta Ortop Bras* 17(4):239–241
- Dendrinou GK, Kontos S, Lyritis E (1995) Use of the Ilizarov technique for treatment of non-union of the tibia associated with infection. *J Bone Joint Surg Am* 77(6):835–846
- Deng Z, Cai L, Jin W, Ping A, Wei R (2014) One-stage reconstruction with open bone grafting and vacuum-assisted closure for infected tibial non-union. *Arch Med Sci* 10(4):764–772. <https://doi.org/10.5114/aoms.2013.34411>
- Doi K, Kawakami F, Hiura Y, Oda T, Sakai K, Kawai S (1995) One-stage treatment of infected bone defects of the tibia with skin loss by free vascularized osteocutaneous grafts. *Microsurgery* 16(10):704–712
- El-Sayed MMH, Gaballah S, Hosny G, Hafez K (2014) Management of infected nonunion of the femur in adults using the Ilizarov technique. *Eur Orthop Traumatol* 5(3):285–291. <https://doi.org/10.1007/s12570-013-0235-x>
- Emami A, Mjoberg B, Larsson S (1995) Infected tibial nonunion. Good results after open cancellous bone grafting in 37 cases. *Acta Orthop Scand* 66(5):447–451
- Eralp İL, Kocaoğlu M, Dikmen G, Azam ME, Balci H, Bilen FE (2016) Treatment of infected nonunion of the juxta-articular region of the distal tibia. *Acta Orthop Traumatol Turc* 50(2):139–146. <https://doi.org/10.3944/aott.2015.15.0147>
- Eralp L, Balci HI, Kocaoğlu M, Sen C, Celiktas M, Tomak Y, Gulsen M, Dikmen G (2016) Is acute compression and distraction superior to segmental bone transport techniques in chronic

- tibial osteomyelitis ? Comparison of distraction osteogenesis techniques. *Acta Orthop Belg* 82(3):599–609
34. Eralp L, Kocaoglu M, Polat G, Baş A, Dirican A, Azam ME (2012) A comparison of external fixation alone or combined with intramedullary nailing in the treatment of segmental tibial defects. *Acta Orthop Belg* 78(5):652–659
 35. Eralp L, Kocaoglu M, Rashid H (2007) Reconstruction of segmental bone defects due to chronic osteomyelitis with use of an external fixator and an intramedullary nail: surgical technique. *J Bone Jt Surg Ser A* 89(SUPPL. 2 PART 2):183–195. <https://doi.org/10.2106/jbjs.g.00306>
 36. Erdinger K, Windhofer C, Papp C (2001) Osteomuscular latissimus dorsi scapula flap to repair chronic, posttraumatic osteomyelitis of the lower leg. *Plastic Reconstr Surg* 107:1430–1435
 37. Esterhai JL Jr, Sennett B, Gelb H, Heppenstall RB, Brighton CT, Osterman AL, LaRossa D, Gelman H, Goldstein G (1990) Treatment of chronic osteomyelitis complicating nonunion and segmental defects of the tibia with open cancellous bone graft, posterolateral bone graft, and soft-tissue transfer. *J Trauma* 30(1):49–54
 38. Fan CY, Hsieh MS, Chen WM, Chen CF (2011) Successful management of infected intramedullary nailing with reaming, lavage, and insertion of antibiotic-impregnated cement rods. *J Exp Clin Med* 3(3):137–141. <https://doi.org/10.1016/j.jecm.2011.04.002>
 39. Ferguson JY, Dudareva M, Riley ND, Stubbs D, Atkins BL, McNally MA (2014) The use of a biodegradable antibiotic-loaded calcium sulphate carrier containing tobramycin for the treatment of chronic osteomyelitis: a series of 195 cases. *Bone Jt J* 96 B(6):829–836. <https://doi.org/10.1302/0301-620x.96b6.32756>
 40. Fleiter N, Walter G, Bosebeck H, Vogt S, Buchner H, Hirschberger W, Hoffmann R (2014) Clinical use and safety of a novel gentamicin-releasing resorbable bone graft substitute in the treatment of osteomyelitis/osteitis. *Bone Joint Res* 3(7):223–229
 41. Guelinckx PJ, Sinsel NK (1995) Refinements in the one-stage procedure for management of chronic osteomyelitis. *Microsurgery* 16(9):606–611. <https://doi.org/10.1002/micr.1920160906>
 42. Hashmi MA, Norman P, Saleh M (2004) The management of chronic osteomyelitis using the Lautenbach method. *J Bone Jt Surg Ser B* 86(2):269–275. <https://doi.org/10.1302/0301-620x.86b2.14011>
 43. Heppert V, Hochstein P, Aymar M, Wentzensen A (1995) The treatment of infected tibial pilon fractures. *Eur J Orthop Surg Traumatol* 5(2):161–163
 44. Humm G, Noor S, Bridgeman P, David M, Bose D (2014) Adjuvant treatment of chronic osteomyelitis of the tibia following exogenous trauma using OSTEOSET-T: a review of 21 patients in a regional trauma centre. *Strateg Trauma Limb Reconstr* 9(3):157–161
 45. Ibnoukhatib A, Lacroix J, Moine A, Archambaud M, Bonnet E, Laffosse JM (2012) Post-traumatic bone and/or joint limb infections due to *Clostridium* spp. *Orthop Traumatol Surg Res* 98(6):696–705
 46. Isenberg JS, Costigan W (1998) Microvascular transfers in the treatment of massive long-bone osteomyelitis: filling the dugout canoe. *J Reconstr Microsurg* 14(2):83–87
 47. Jain AK, Sinha S (2005) Infected nonunion of the long bones. *Clin Orthop Relat Res* 431:57–65. <https://doi.org/10.1097/01.blo.0000152868.29134.92>
 48. Jeong JJ, Lee HS, Choi YR, Kim SW, Seo JH (2012) Surgical treatment of non-diabetic chronic osteomyelitis involving the foot and ankle. *Foot Ankle Int* 33(2):128–132. <https://doi.org/10.3113/fai.2012.0128>
 49. May JM, Jupiter JB, Gallico GG 3rd, Rothkopf DM, Zingarelli P (1991) Treatment of chronic traumatic bone wounds. Microvascular free tissue transfer: a 13-year experience in 96 patients. *Ann Surg* 214(3):241–250 **discussion 250–252**
 50. Lei H, Yi L (1998) One-stage open cancellous bone grafting of infected fracture and nonunion. *J Ortop Sci* 3(6):318–323. <https://doi.org/10.1007/s007760050059>
 51. Lin CC, Chen CM, Chiu FY, Su YP, Liu CL, Chen TH (2012) Staged protocol for the treatment of chronic tibial shaft osteomyelitis with Ilizarov's technique followed by the application of intramedullary locked nail. *Orthopedics* 35(12):e1769–e1774
 52. Liu T, Yu XD, Zhang XS, Li ZH, Zeng W (2012) One-stage management of post-traumatic tibial infected nonunion using bone transport after debridement. *Turk J Med Sci* 42(6):1111–1120
 53. Luo S, Jiang T, Yang Y, Yang X, Zhao J (2016) Combination therapy with vancomycin-loaded calcium sulfate and vancomycin-loaded PMMA in the treatment of chronic osteomyelitis. *BMC Musculoskelet Disord* 17(1):502. <https://doi.org/10.1186/s12891-016-1352-9>
 54. Malizos KN, Gougoulis NE, Dailiana ZH, Varitimidis S, Bargiotas KA, Paridis D (2010) Ankle and foot osteomyelitis: treatment protocol and clinical results. *Injury* 41(3):285–293. <https://doi.org/10.1016/j.injury.2009.09.010>
 55. Marsh JL, Prokuski L, Biermann JS (1994) Chronic infected tibial nonunions with bone loss: conventional techniques versus bone transport. *Clin Orthop Relat Res* 301:139–146
 56. McKee MD, Li-Bland EA, Wild LM, Schemitsch EH (2010) A prospective, randomized clinical trial comparing an antibiotic-impregnated bioabsorbable bone substitute with standard antibiotic-impregnated cement beads in the treatment of chronic osteomyelitis and infected nonunion. *J Orthop Trauma* 24(8):483–490. <https://doi.org/10.1097/BOT.0b013e3181df91d9>
 57. McKee MD, Wild LM, Schemitsch EH, Waddell JP (2002) The use of an antibiotic-impregnated, osteoconductive, bioabsorbable bone substitute in the treatment of infected long bone defects: early results of a prospective trial. *J Orthop Trauma* 16(9):622–627. <https://doi.org/10.1097/00005131-200210000-00002>
 58. Megas P, Saridis A, Kouzelis A, Kallivokas A, Mylonas S, Tylilianakis M (2010) The treatment of infected nonunion of the tibia following intramedullary nailing by the Ilizarov method. *Injury* 41(3):294–299
 59. Moghaddam A, Zietzschmann S, Bruckner T, Schmidmaier G (2015) Treatment of atrophic tibia non-unions according to 'diamond concept': results of one- and two-step treatment. *Injury* 46:S39–S50. [https://doi.org/10.1016/s0020-1383\(15\)30017-6](https://doi.org/10.1016/s0020-1383(15)30017-6)
 60. Mohanty SP, Kumar MN, Murthy NS (2003) Use of antibiotic-loaded polymethyl methacrylate beads in the management of musculoskeletal sepsis—a retrospective study. *J Orthop Surg* 11(1):73–79
 61. Necmioglu S, Askar I, Lök V, Subasi M (2004) Use of the vastus lateralis muscle flap with a grooving procedure in the surgical treatment of chronic osteomyelitis of the femur. *Ann Plast Surg* 53(6):570–576. <https://doi.org/10.1097/01.sap.0000134752.01294.d0>
 62. Nenad T, Reiner W, Michael S, Reinhard H, Hans H (2010) Saphenous perforator flap for reconstructive surgery in the lower leg and the foot: a clinical study of 50 patients with posttraumatic osteomyelitis. *J Trauma Inj Infect Crit Care* 68(5):1200–1207. <https://doi.org/10.1097/TA.0b013e3181d03d18>
 63. Niikura T, Lee SY, Iwakura T, Sakai Y, Kuroda R, Kurosaka M (2016) Antibiotic-impregnated calcium phosphate cement as part of a comprehensive treatment for patients with established orthopaedic infection. *J Ortop Sci* 21(4):539–545. <https://doi.org/10.1016/j.jos.2016.05.003>
 64. Patzakis MJ, Mazur K, Wilkins J, Sherman R, Holtom P (1993) Septopal beads and autogenous bone grafting for bone defects in patients with chronic osteomyelitis. *Clin Orthop Relat Res* (295):112–118

65. Patzakis MJ, Scilaris TA, Chon J, Holtom P, Sherman R (1995) Results of bone grafting for infected tibial nonunion. *Clin Orthop Relat Res* (315):192–198
66. Polyzois VD, Galanakis SP, Tsiampa VA, Papakostas ID, Kouris NK, Avram AM, Papalois AE, Ignatiadis IA (2011) The use of Papineau technique for the treatment of diabetic and non-diabetic lower extremity pseudoarthrosis and chronic osteomyelitis. *Diabetic Foot Ankle* 2:1–7. <https://doi.org/10.3402/dfa.v2i0.5920>
67. Prasarn ML, Ahn J, Achor T, Matuszewski P, Lorich DG, Helfet DL (2009) Management of infected femoral nonunions with a single-staged protocol utilizing internal fixation. *Injury* 40(11):1220–1225
68. Prasarn ML, Ouellette EA, Miller DR (2010) Infected nonunions of diaphyseal fractures of the forearm. *Arch Orthop Trauma Surg* 130(7):867–873
69. Qiang Z, Jun PZ, Jie XJ, Hang L, Bing LJ, Cai LF (2007) Use of antibiotic cement rod to treat intramedullary infection after nailing: preliminary study in 19 patients. *Arch Orthop Trauma Surg* 127(10):945–951
70. Qiu XS, Chen YX, Qi XY, Shi HF, Wang JF, Xiong J (2017) Outcomes of cement beads and cement spacers in the treatment of bone defects associated with post-traumatic osteomyelitis. *BMC Musculoskelet Disord* 18(1):256. <https://doi.org/10.1186/s12891-017-1614-1>
71. Reichert P, Rutowski R, Gosk J, Zimmer K, Wiacek R (2007) Treatment of infected nonunion of long bones. *Adv Clin Exp Med* 16(3):403–409
72. Sadek AF, Laklok MA, Fouly EH, Elshafie M (2016) Two stage reconstruction versus bone transport in management of resistant infected tibial diaphyseal nonunion with a gap. *Arch Orthop Trauma Surg* 136(9):1233–1241
73. Sancineto CF, Barla JD (2008) Treatment of long bone osteomyelitis with a mechanically stable intramedullary antibiotic dispenser: nineteen consecutive cases with a minimum of 12 months follow-up. *J Trauma Inj Infect Crit Care* 65(6):1416–1420. <https://doi.org/10.1097/TA.0b013e31818c6a09>
74. Scholz AO, Gehrmann S, Glombitza M, Kaufmann RA, Bostelmann R, Flohe S, Windolf J (2015) Reconstruction of septic diaphyseal bone defects with the induced membrane technique. *Injury* 46(Suppl 4):S121–S124
75. Schröter S, Ateschrang A, Flesch I, Stöckle U, Freude T (2015) First mid-term results after cancellous allograft vitalized with autologous bone marrow for infected femoral non-union. *Wien Klin Wochenschr* 128(21–22):827–836. <https://doi.org/10.1007/s00508-015-0797-4>
76. Selhi HS, Mahindra P, Yamin M, Jain D, De Long WG Jr, Singh J (2012) Outcome in patients with an infected nonunion of the long bones treated with a reinforced antibiotic bone cement rod. *J Orthop Trauma* 26(3):184–188
77. Shah RK, Singh RP, Quasem MF, Faruquee SR, Harrison J (2009) SIGN interlocking nail for the treatment of infected nonunion. *Tech Orthop* 24(4):289–296. <https://doi.org/10.1097/BTO.0b013e3181bfd597>
78. Shen L, Dong Y, Zhang C, Guo Q, Shou D, Zhang Y, Zhang Z, Wong KKL, Ghista DN, Huang W (2015) Chronic osteomyelitis treatment: a clinical and pharmaco-kinetic study of vancomycin impregnated calcium sulphate. *J Med Imaging Health Inf* 5(1):36–42. <https://doi.org/10.1166/jmihi.2015.1362>
79. Shyam AK, Sancheti PK, Patel SK, Rocha S, Pradhan C, Patil A (2009) Use of antibiotic cement-impregnated intramedullary nail in treatment of infected non-union of long bones. *Indian J Orthop* 43(4):396–402
80. Shah SW, Wei FC, Shih CH. (1999) Management of femoral diaphyseal infected nonunion with antibiotic beads local therapy, external skeletal fixation, and staged bone grafting. *J Trauma Inj Infect Crit Care* 46(1):97–103. <https://doi.org/10.1097/00005373-199901000-00016>
81. Tajsi N, Winkel R, Hoffmann R, Husum H (2009) Sural perforator flap for reconstructive surgery in the lower leg and the foot: a clinical study of 86 patients with post-traumatic osteomyelitis. *J Plast Reconstr Aesth Surg* 62(12):1701–1708. <https://doi.org/10.1016/j.bjps.2008.06.091>
82. Tan Y, Wang X, Li H, Zheng Q, Li J, Feng G, Pan ZJ (2011) The clinical efficacy of the vacuum-assisted closure therapy in the management of adult osteomyelitis. *Arch Orthop Trauma Surg* 131(2):255–259
83. Thonse R, Conway J (2007) Antibiotic cement-coated interlocking nail for the treatment of infected nonunions and segmental bone defects. *J Orthop Trauma* 21(4):258–268
84. Tong K, Zhong Z, Peng Y, Lin C, Cao S, Yang Y, Wang G (2017) Masquelet technique versus Ilizarov bone transport for reconstruction of lower extremity bone defects following post-traumatic osteomyelitis. *Injury* 48(7):1616–1622. <https://doi.org/10.1016/j.injury.2017.03.042>
85. Tu YK, Yen CY (2007) Role of vascularized bone grafts in lower extremity osteomyelitis. *Orthop Clin North Am* 38(1):37–49. <https://doi.org/10.1016/j.ocl.2006.10.005>
86. Tulner SAF, Schaap GR, Strackee SD, Besselaar PP, Luitse JSK, Marti RK (2004) Long-term results of multiple-stage treatment for posttraumatic osteomyelitis of the Tibia. *J Trauma Inj Infect Crit Care* 56(3):633–642
87. Ueng WN, Shih CH (1995) Management of infected tibial intramedullary nailing using an organized treatment protocol. *Eur J Orthop Surg Traumatol* 5(2):151–155
88. Vitkus K, Vitkus M, Cierny Iii G, Nahai F (1992) Reconstruction of large infected tibia defects. *Ann Plast Surg* 29(2):97–108
89. Wang X, Luo F, Huang K, Xie Z (2016) Induced membrane technique for the treatment of bone defects due to post-traumatic osteomyelitis. *Bone Joint Res* 5(3):101–105. <https://doi.org/10.1302/2046-3758.53.2000487>
90. Wascko MK, Borens O (2013) Antibiotic cement nail for the treatment of posttraumatic intramedullary infections of the tibia: mid-term results in 10 cases. *Injury* 44(8):1057–1060
91. Wu CC (2011) Single-stage surgical treatment of infected nonunion of the distal Tibia. *J Orthop Trauma* 25(3):156–161
92. Wu CH, Yuan LJ, Chan YS, Chen ACY, Lee MS, Ueng SWN (2007) Conditions affecting treatment of petrochanteric osteomyelitis. *Chang Gung Med J* 30(5):414–422
93. Xu K, Fu X, Li YM, Wang CG, Li ZJ (2014) A treatment for large defects of the tibia caused by infected nonunion: Ilizarov method with bone segment extension. *Ir J Med Sci* 183(3):423–428
94. Xu XY, Zhu Y, Liu JH (2009) Treatment of calcaneal osteomyelitis with free serratus anterior muscle flap transfer. *Foot Ankle Int* 30(11):1088–1093
95. Yang C, Geng S, Fu C, Sun J, Bi Z (2013) A minimally invasive modified reverse sural adipofascial flap for treating post-traumatic distal tibial and calcaneal osteomyelitis. *Int J Lower Extrem Wounds* 12(4):279–285. <https://doi.org/10.1177/1534734613511637>
96. Yang YF, Xu ZH, Zhang GM, Wang JW, Hu SW, Hou ZQ, Xu DC (2013) Modified classification and single-stage microsurgical repair of posttraumatic infected massive bone defects in lower extremities. *J Reconstr Microsurg* 29(9):593–600. <https://doi.org/10.1055/s-0033-1348064>
97. Yin P, Zhang LH, Li TT, Zhang LC, Wang GQ, Li JT, Liu JH, Zhou JF, Zhang Q, Tang PF (2015) Infected nonunion of tibia and femur treated by bone transport. *J Orthop Surg Res* 10:49
98. Zalavras CG, Patzakis MJ, Thordarson DB, Shah S, Sherman R, Holtom P (2004) Infected fractures of the distal tibial metaphysis and plafond—achievement of limb salvage with free muscle

- flaps, bone grafting, and ankle fusion. *Clin Orthop Relat Res* 427:57–62
99. Zalavras CG, Singh A, Patzakis MJ (2007) Novel technique for medullary canal débridement in tibia and femur osteomyelitis. *Clin Orthop Relat Res* 461:31–34. <https://doi.org/10.1097/BLO.0b013e318098673f>
 100. Zumiotti AV, Teng HW, Ferreira MC (2003) Treatment of post-traumatic tibial osteomyelitis using microsurgical flaps. *J Reconstr Microsurg* 19(3):163–171. <https://doi.org/10.1055/s-2003-39829>
 101. Zych GA, Hutson JJ Jr (1995) Diagnosis and management of infection after tibial intramedullary nailing. *Clin Orthop Relat Res* (315):153–162
 102. Cats-Baril W, Gehrke T, Huff K, Kendoff D, Maltenfort M, Parvizi J (2013) International consensus on periprosthetic joint infection: description of the consensus process. *Clin Orthop Relat Res* 471(12):4065–4075
 103. Metsemakers WJ, Kortram K, Morgenstern M, Moriarty TF, Meex I, Kuehl R, Nijs S, Richards RG, Raschke M, Borens O, Kates SL, Zalavras C, Giannoudis PV, Verhofstad MHJ (2018) Definition of infection after fracture fixation: a systematic review of randomized controlled trials to evaluate current practice. *Injury* 49(3):497–504
 104. Morgenstern M, Moriarty TF, Kuehl R, Richards RG, McNally MA, Verhofstad MHJ, Borens O, Zalavras C, Raschke M, Kates SL, Metsemakers WJ (2018) International survey among orthopaedic trauma surgeons: lack of a definition of fracture-related infection. *Injury* 49(3):491–496
 105. Borens O, Helmy N (2016) [Infected osteosynthesis] Infizierte Osteosynthese. *Chirurg* 87(10):822–830
 106. Willenegger H, Roth B (1986) [Treatment tactics and late results in early infection following osteosynthesis] Behandlungstaktik und Spätergebnisse bei Fruhinjekt nach Osteosynthese. *Unfallchirurgie* 12(5):241–246
 107. Kleber C, Schaser KD, Trampuz A (2015) [Complication management of infected osteosynthesis: therapy algorithm for peri-implant infections] Komplikationsmanagement bei infizierter Osteosynthese: therapiealgorithmus bei periimplantären Infektionen. *Chirurg* 86(10):925–934
 108. Metsemakers WJ, Morgenstern M, McNally MA, Moriarty TF, McFadyen I, Scarborough M, Athanasou NA, Ochsner PE, Kuehl R, Raschke M, Borens O, Xie Z, Velkes S, Hungerer S, Kates SL, Zalavras C, Giannoudis PV, Richards RG, Verhofstad MHJ (2018) Fracture-related infection: a consensus on definition from an international expert group. *Injury* 49(3):505–510
 109. Greene LR (2012) Guide to the elimination of orthopedic surgery surgical site infections: an executive summary of the Association for Professionals in Infection Control and Epidemiology elimination guide. *Am J Infect Control* 40(4):384–386
 110. Greene LR, Association for Professionals in Infection C, Epidemiology, Aorn (2010) Guide to the elimination of orthopedic surgical site infections. APIC, Aorn. <https://apic.org/Resource/EliminationGuideForm/34e03612-d1e6-4214-a76b-e532c6fc3898/File/APIC-Ortho-Guide.pdf>. Accessed 1 June 2018
 111. Dudareva M, Ferguson J, Riley N, Stubbs D, Atkins B, McNally M (2017) Osteomyelitis of the pelvic bones: a multidisciplinary approach to treatment. *J Bone Jt Infect* 2(4):184–193
 112. Bose D, Kugan R, Stubbs D, McNally M (2015) Management of infected nonunion of the long bones by a multidisciplinary team. *Bone Joint J* 97-B(6):814–817
 113. Kortram K, Bezstarosti H, Metsemakers WJ, Raschke MJ, Van Lieshout EMM, Verhofstad MHJ (2017) Risk factors for infectious complications after open fractures; a systematic review and meta-analysis. *Int Orthop* 41(10):1965–1982
 114. Metsemakers WJ, Onsea J, Neutjens E, Steffens E, Schuermans A, McNally M, Nijs S (2017) Prevention of fracture-related infection: a multidisciplinary care package. *Int Orthop* 41(12):2457–2469
 115. Obremskey WT, Higgins TF, Bettger JP, Vrahas MS, Lundy DW (2018) Use of patient-related outcomes after orthopaedic trauma: helpful or not so much? *J Orthop Trauma* 32(Suppl 1):S48–S51