



Since January 2020 Elsevier has created a COVID-19 resource centre with free information in English and Mandarin on the novel coronavirus COVID-19. The COVID-19 resource centre is hosted on Elsevier Connect, the company's public news and information website.

Elsevier hereby grants permission to make all its COVID-19-related research that is available on the COVID-19 resource centre - including this research content - immediately available in PubMed Central and other publicly funded repositories, such as the WHO COVID database with rights for unrestricted research re-use and analyses in any form or by any means with acknowledgement of the original source. These permissions are granted for free by Elsevier for as long as the COVID-19 resource centre remains active.

Coronavirus JHM-Induced Demyelinating Encephalomyelitis in Rats: Influence of Immunity on the Course of Disease

HELMUT WEGE, RIHITO WATANABE, MAKOTO KOGA and VOLKER TER MEULEN

Institute for Virology and Immunobiology, University of Würzburg, Versbacher Str. 7, D-8700 Würzburg (F.R.G.)

INTRODUCTION

Disease processes of the central nervous system (CNS) accompanied by demyelination may be the result of a viral infection or the consequence of an immunopathological reaction directed against myelin (ter Meulen and Hall, 1978; Wisniewski, 1977; Weiner and Stohlman, 1978). In acute viral infections it has been assumed that the infection of oligodendroglial cells, leading to cell destruction, may be the main mechanism for inducing this neuropathological lesion. In the case of a persistent virus infection in oligodendroglia cells, however, it is conceivable that functional impairment of oligodendroglia cells, and/or the induction of an immune reaction to the agent which may cross-react with brain antigens, could eventually cause demyelination. Therefore, pathogenic studies on subacute or chronic demyelinating encephalomyelitides in association with viral infections may provide information on the mechanisms involved in demyelination.

In connection with this, infections by murine coronaviruses are of increasing interest (Wege et al., 1982). Strain JHM is known for its ability to cause demyelinating encephalomyelitis in different animal species (Cheever et al., 1949; Bailey et al., 1949; Weiner, 1973; Powell and Lampert, 1975; Fleury, 1980). Additionally, the virus has a tendency to cause chronic infections accompanied by demyelination (Herndon et al., 1975; Stohlman and Weiner, 1981). In rats, depending on the biological property of the virus material used, the genetic background and immune response of the host, a subacute or late demyelinating encephalomyelitis can be induced, accompanied by primary demyelination (Nagashima et al., 1978, 1979; Sorensen et al., 1980). This provides a model for analysis of the virus and host factors which interact in the pathogenesis of these diseases. In this chapter the results of our studies are summarized.

MATERIALS AND METHODS

Virus

The murine coronavirus JHM was either propagated by passage of brain homogenates from suckling mice, or grown in Sac (–) cells, and purified according to Wege et al. (1978).

Temperature sensitive mutants were selected from virus stocks, after mutagenesis with 5'-fluorouracil, by growth at 34°C and selection at 39.5°C, similar to the methods used by Haspel et al. (1978) and Robb et al. (1979).

Animals

The animals used for experiments were either outbred rats, strain Thom/Chbb (Thomae, Biberach, F.R.G.) or inbred rats, strain Lewis. Animals were inoculated into the left brain hemisphere with 0.03 ml of virus suspension using a dispenser syringe. Methods for histology, electron microscopy and virus isolation have been described in previous communications (Nagashima et al., 1978, 1979).

Immunization

For immunization, female adult rats were inoculated i.p. 4–6 times, with about 1×10^6 pfu of JHM-virus per injection. Alternatively, female rats were immunized by footpad and intradermal inoculation. The virus was purified inactivated by treatment with β -propiolactone and mixed with complete Freund's adjuvant. The animals were boosted 3 weeks later by i.m. and i.v. inoculation with purified inactivated virus. The rats were mated after the last immunization, and suckling animals born from these mothers were infected by intracerebral inoculation of JHM virus (ts6) at an age of 4–5 days.

Stimulation of lymphocytes

Lymphocytes were cultivated and stimulated with either guinea pig myelin basic protein or inactivated purified virus, according to the methods of Richert et al. (1979). Lymphoblast transformation was determined by measuring the incorporation of [^3H]thymidine, and adoptive transfer was performed by i.v. inoculation of $1 \times 10^7 - 1 \times 10^8$ lymphocytes according to Richert et al. (1979).

RESULTS

CNS diseases induced by JHM virus in rats

Uncloned JHM virus inoculated into the brain of suckling rats caused an acute panencephalitis (APE) which developed after a short incubation time (2–8 days) and rapidly led to death. The virus spread through all parts of the CNS, and also caused severe hepatitis. However, when JHM virus was inoculated into rats older than 21 days, two different courses, acute and subacute encephalomyelitis, were observed. After a relatively short incubation time of 6–12 days, a rapidly progressing paralytic disease occurred which was always fatal. The lesions of this acute encephalomyelitis (AE) were often necrotizing with a strong involvement of the CNS grey matter (Fig. 1A). Cell infiltrations were typical of acute inflammations and consisted mainly of polymorphnuclear lymphocytes (Fig. 1B). Viral antigens were detectable in both neurons and glia cells. Animals which showed clinical signs several weeks to months post-infection (p.i.) developed typical plaques of primary demyelination. The lesions of this subacute demyelinating encephalomyelitis (SDE) were disseminated predominantly in selected areas of the white matter including the optic nerve, midbrain and spinal cord. As illustrated in Fig. 2A, plaques were sharply demarcated. Neurons and axons were well preserved, even within the demyelinated area. Perivascular infiltrations consisted mainly of monocytes (Fig. 2B). Viral antigens were confined to glia cells. Animals which developed clinical disease after an incubation time of several months (late demyelinating encephalomyelitis, LDE) showed signs of both demyelination and remyelination on electron microscopic examination, indicating a chronic disease process. Infectious virus could be reisolated even after this long incubation time from such diseased animals.

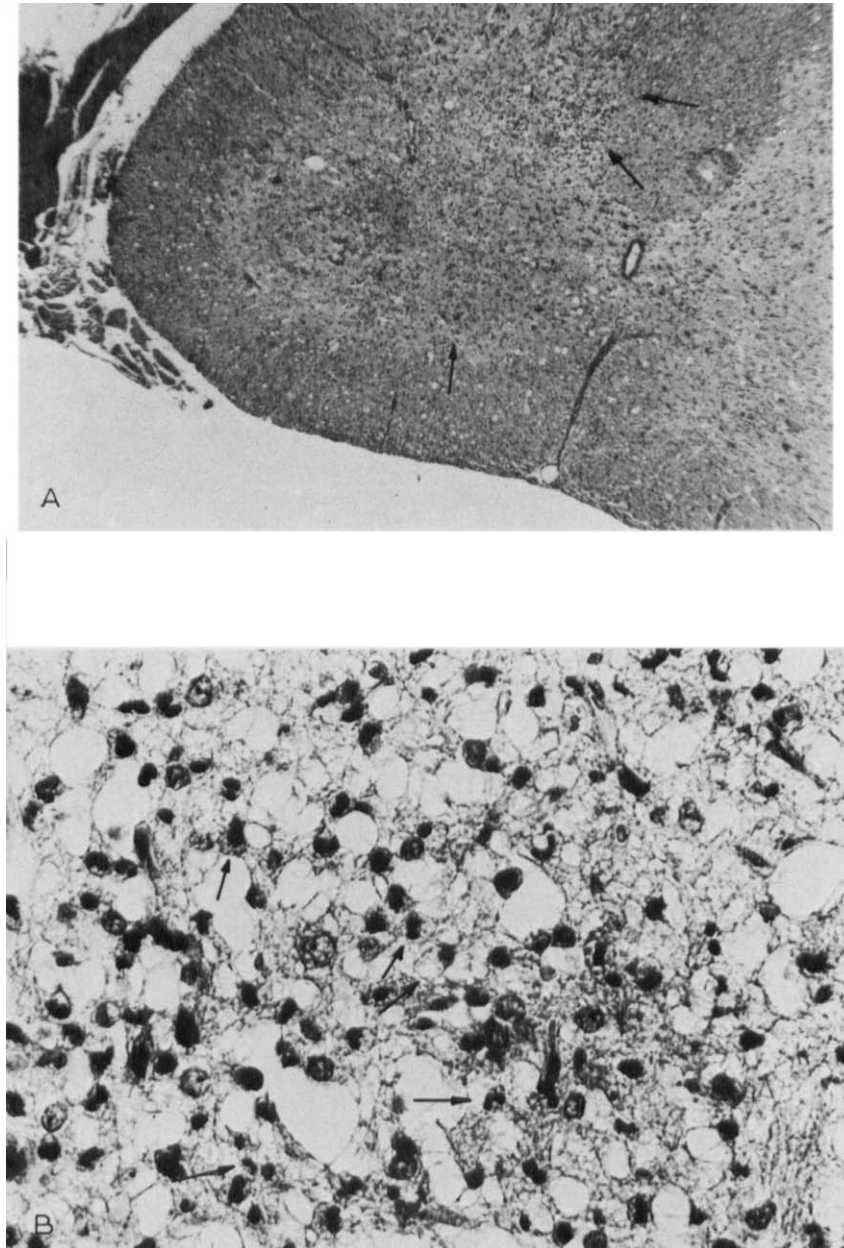


Fig. 1. Spinal cord, acute encephalomyelitis (10 days p.i.) A: widespread cell infiltrations (arrows) in necrotic area of grey matter. HE staining, $\times 35$. B: numerous phagocytes (small arrows) including neutrophilic leucocytes (large arrows) in infiltrated area. HE staining, $\times 400$.

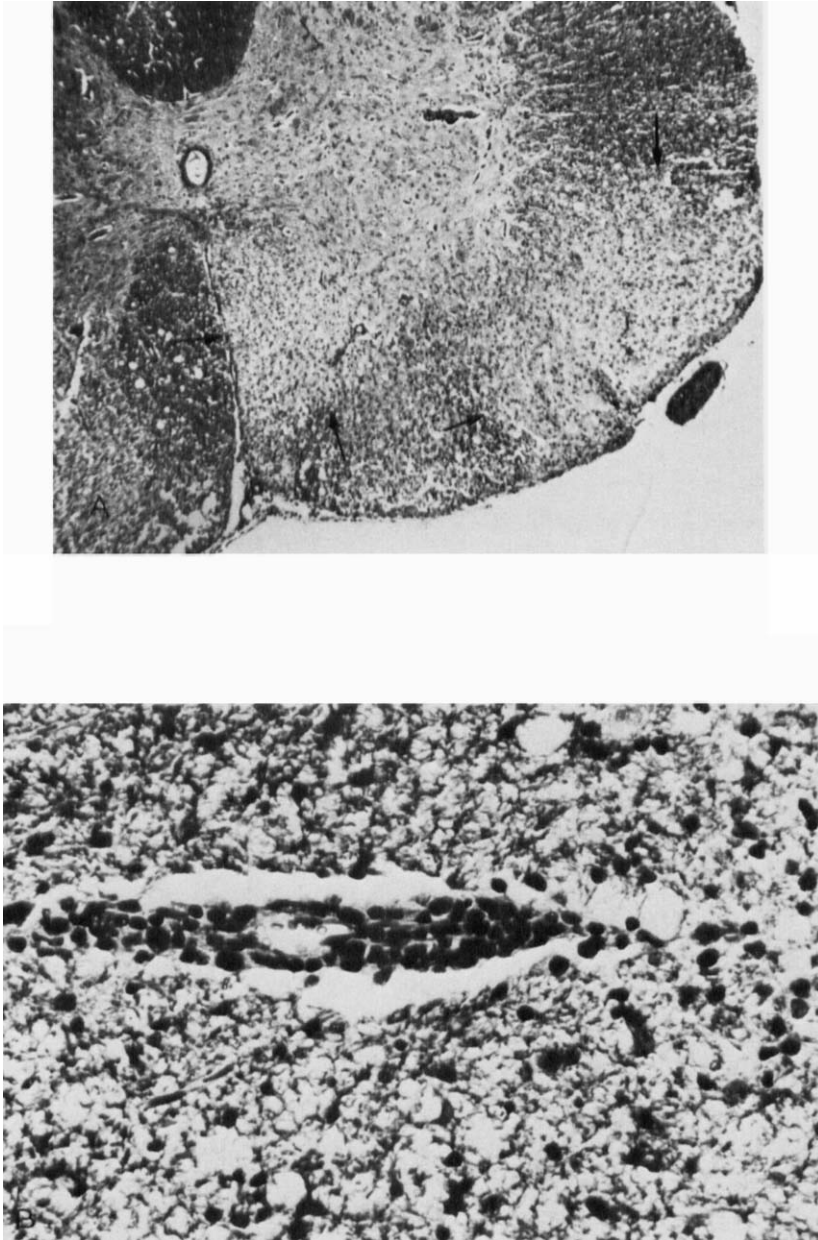


Fig. 2. Spinal cord, subacute demyelinating encephalomyelitis (25 days p.i.). A: demarcated demyelinating plaques (arrows) in white matter. Neurons are well-preserved. HE staining, $\times 35$. B: mononuclear cell infiltration around venule. HE staining, $\times 400$.

Influence of host age and properties of the virus on disease course

Intracerebral infection with uncloned JHM virus gave rise only to APE in suckling rats (Thomae/Chbb); in rats inoculated at an age of 21–25 days both acute, and subacute to late, encephalomyelitis developed (Table I). Cloned virus, which was adapted to grow in tissue

TABLE I
CORONAVIRUS JHM INFECTION IN RATS

<i>Virus inoculated</i>	<i>Age of animals at infection</i>	
	<i>Suckling (<20 days)</i>	<i>Weanling (>20 days)</i>
Uncloned virus	Acute panencephalitis	Acute encephalomyelitis, subacute and late demyelinating encephalomyelitis
Cloned virus	Acute panencephalitis	Acute encephalomyelitis
ts-mutants	Acute panencephalitis and subacute demyelinating encephalomyelitis depending on age of animal and mutant	Subacute and late demyelinating encephalomyelitis

culture, however, had lost the capacity to induce demyelinating diseases and led, depending on the age of the animals, to APE or AE. By contrast, temperature-sensitive mutants differed widely in their neurovirulence, and mutants were found which induced high rates of SDE in suckling rats. The results obtained with ts43, for example, are summarized in Table II: APE was only induced in rats which are inoculated within 5 days after birth. Animals inoculated with wild type virus, however, developed a typical APE which rapidly led to death, regardless of the age at infection. Animals inoculated with ts43 predominantly developed SDE especially if infected at an age of 10–15 days. With increasing age, however, the rats became resistant to the ts mutant. It is noteworthy that many animals recovered after disease periods of 1–4 weeks.

TABLE II
COMPARISON OF NEUROVIRULENCE OF JHM wt AND JHM ts43
wt, JHM wild-type virus; ts, temperature-sensitive mutant.

<i>Age at time of infection ± 1 day</i>	<i>Virus</i> 4×10^3 pfu/rat <i>I.C.</i>	<i>Diseased/total</i>	<i>Range of incubation time (days)</i>	<i>Recovery from disease</i>	<i>Type of disease</i>
4	wt	7/10	3–5	none	APE
	ts43	26/26	10–17	2/13	APE < SDE
10	wt	8/10	3–6	none	APE
	ts43	22/43	14–112	11/22	SDE
15	wt	7/12	4–11	none	APE/AE
	ts43	1/12	92	–	LDE

Antiviral immunity and development of SDE

Neuropathological examination of clinically healthy rats which were dissected 30–40 days p.i., often revealed demyelinating lesions, although no infectious virus was recoverable from such animals. Further detailed studies on the kinetics of virus growth, occurrence of neutralizing antibodies and distribution and type of lesions, indicated that the development of demyelinating lesions was preceded by an AE, which did not lead to a clinically recognizable disease (Fig. 3). For this experiment, rats were infected at the age of 21–24 days with uncloned JHM virus. Groups of clinically healthy rats were randomly selected and sacrificed for investigation as shown on the time scale in Fig. 3. Within 3–12 days p.i., infectious virus could be isolated from CNS tissue of clinically healthy animals. During this early period, most of these rats revealed a neuropathologically and clinically silent AE. Later in infection, when an antiviral immune response was measurable, no infectious virus could be isolated. However, demyelinating plaques were detected in many rats which did not show a clinical disease.

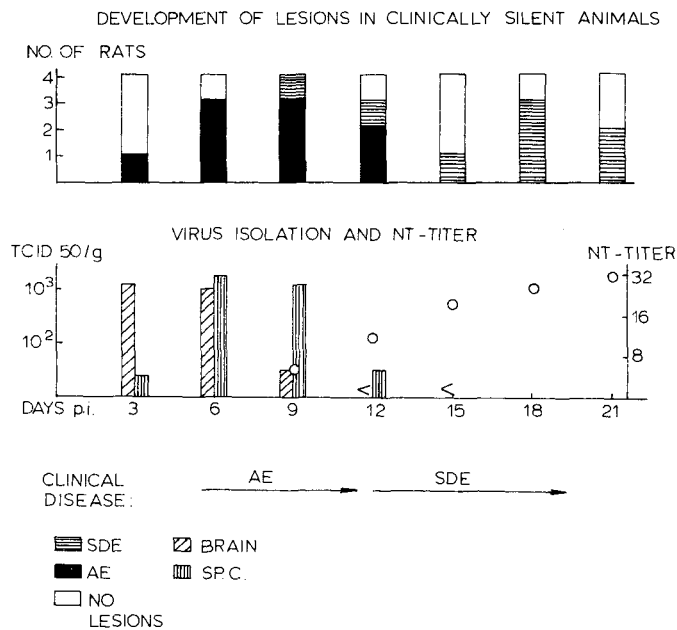


Fig. 3. Development of lesions, virus growth and antiviral immune response in clinically silent rats. Animals were infected with uncloned JHM virus at an age of 21–24 days.

These observations suggest that, in addition to the biological properties of the virus and to the host age, the antiviral immune response may modify the JHM-induced disease course. To test this hypothesis, we infected suckling rats born from mothers which were already immune against JHM virus (Fig. 4). The animals were inoculated at an age of 4–5 days with the mutant ts6. Non-immune suckling rats infected under the same conditions died within 5–15 days from a typical APE. Suckling rats born from immune mothers, however, developed high rates of SDE after prolonged incubation times. Infection of suckling rats which were born from mothers immunized by purified inactivated virus led to a similar high rate of SDE with a

prolonged onset. These results indicate that the antiviral immune response can indeed modify the disease process.

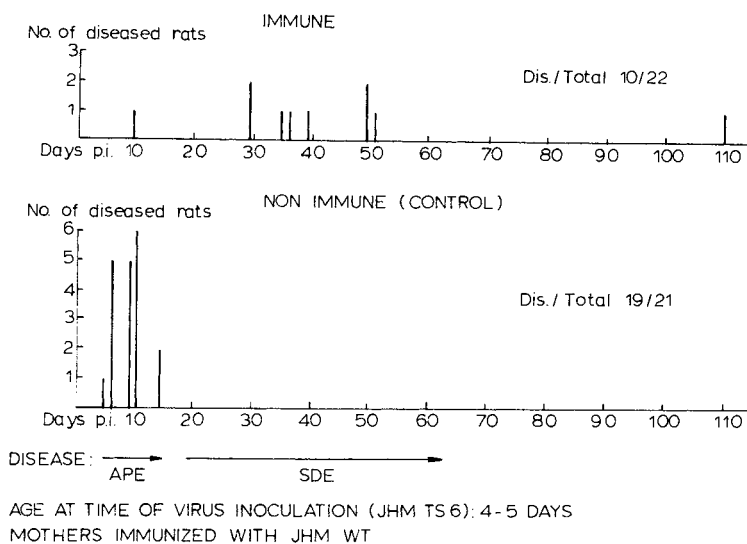


Fig. 4. Influence of maternal immunity to JHM virus on the development of CNS disease in suckling rats.

Possible involvement of reactive lymphocytes in development of SDE

In order to determine whether cell-mediated immune reactions might play a role in JHM virus-induced demyelination, experiments were performed in Lewis rats, an inbred strain which is genetically characterized and susceptible for EAE. The inoculation of JHM virus into Lewis rats led to the same disease patterns as described in the previous sections. In animals with SDE, we noticed a high number of perivascular cuffs which were not observed to such an extent during our experiments with outbred rats. Such cellular infiltrations consisted predominantly of mononuclear cells (Fig. 2B). This interesting observation prompted us to test lymphocytes from SDE animals for their ability to be stimulated with myelin basic protein (MBP) and viral antigen. As summarized in Table III, lymphocytes from Lewis rats with AE derived from peripheral blood, spleen and thymus could only be slightly stimulated by either myelin basic protein or inactivated purified virus. Animals which developed SDE after a prolonged incubation time, however, showed many perivascular cuffs in the CNS tissue and revealed an antiviral immune response indicated by neutralizing antibodies and virus-specific lymphoblast stimulation. Moreover, lymphoblasts incorporated [^3H]thymidine on cultivation with myelin basic protein. Such stimulated lymphocytes were transferred to normal recipients in order to investigate the possibility of transferring the SDE disease process. Perivascular cuffs were found in several animals similar to those seen in rats with SDE (Fig. 5). Moreover, slight clinical changes consisting of weight loss, ataxic gait and hindleg paresis were observed. These preliminary results indicate that, during the disease process, lymphocytes sensitized against neuroantigens may contribute to the development of primary demyelination, in addition to the antiviral immune response.

TABLE III
 ACUTE AND SUBACUTE CNS-DISEASE IN LEWIS RATS
 Infection with JHM-virus at an age of 30 days.

	<i>Acute encephalomyelitis</i>	<i>Subacute demyelinating encephalomyelitis</i>
Onset of disease	3-9 days p.i.	12 days p.i.
Perivascular cuffing	Slight (0-4/5 sections)	Strong (> 10/5 sections)
Neutr. antibody titer	1:8	1:16-1:48
Lymphoblast Transformation in vitro by JHM-virus	Stimulation index ± 2	6-10 \times stimulation index
by MBP	Stimulation index ≤ 2	2-8 \times stimulation index

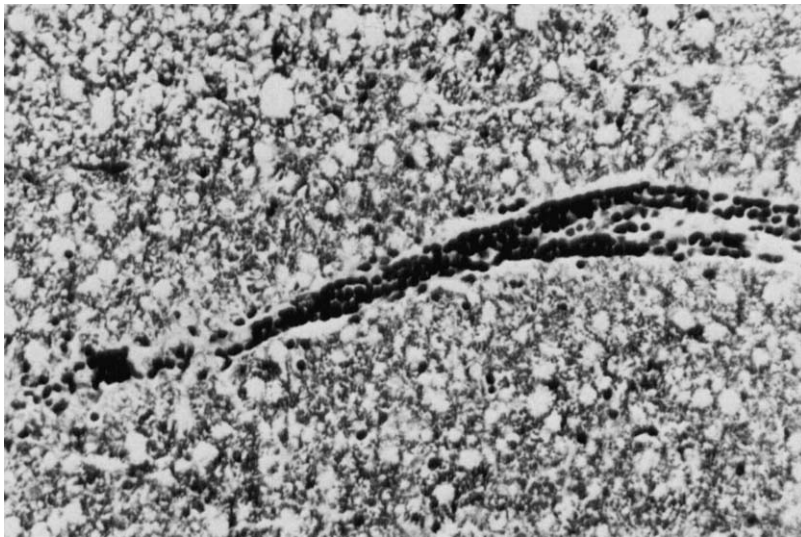


Fig. 5. Infiltration in the spinal cord consisting of mononuclear cells. Rat dissected 5 days post-adoptive transfer of lymphocytes from a rat with SDE. Stimulation by culture with MPB. HE staining, $\times 250$.

DISCUSSION

The rate and onset of demyelinating encephalomyelitis induced in rats infected with JHM virus is influenced by biological properties of the virus, the age of the host at time of infection and the immune status of the host. This framework forms the basis for further studies on the pathogenesis of virus induced demyelination.

The uncloned virus induced both acute and subacute CNS diseases. The development of such different disease courses may be due to a genetically heterogenous virus population,

consisting of clones which vary in cell tropism and growth properties. Clones which were randomly selected from tissue-culture-adapted virus were no longer capable of inducing SDE. Temperature-sensitive mutants, however, induced high rates of SDE, and the age of the animal at the time of infection was an important parameter influencing the outcome of disease. These alterations in the virulence of ts mutants are conceivably the result of impaired virus growth at the host body temperature, which enabled the animals to survive the acute stage of infection without clinical manifestation of an APE or AE. In addition, ts-mutants might be restricted in their cell tropism within the host. Knobler et al. (1981) recently demonstrated that a ts mutant of JHM virus has a predilection for replication in oligodendroglia cells, whereas wild type virus also replicates in neurons. Viral antigen was predominantly detectable only in the white matter of the CNS of animals with demyelinating encephalomyelitis or chronic infection (Weiner, 1973; Nagashima et al., 1978 and 1979; Stohlman and Weiner, 1981). Virus particles were only detectable by electron microscopy in degenerating oligodendroglia cells (Nagashima et al., 1978; Lampert et al., 1973).

Several observations indicate that the antiviral immune response may lead to conditions allowing the virus to persist in the CNS provided no clinical disease develops within the first weeks p.i. Development of SDE is probably preceded by a clinically silent AE, as our studies on the kinetics of virus growth and lesions suggest. Demyelinating plaques were only detectable at a time when no infectious virus could be isolated from clinically healthy animals and when an antiviral immune response was measurable.

Further support of the hypothesis that an immune response to the infectious process plays a pathogenic role comes from experiments with suckling rats fostered by mothers which were immune to JHM virus. Under conditions where normal rats clearly developed a fatal APE, rats reared by immune mothers developed high rates of SDE after a prolonged incubation. This type of experiment was only successful if a ts mutant was used for the challenging virus. This noteworthy shift in disease-course may not be mediated only by the continuous presence of antiviral antibodies, since lymphoid cells are also known to be transferred from the mother during the suckling period and to migrate through the gut (Seelig and Beer, 1978). It is conceivable that JHM infection, in the presence of an antiviral immunity, may confine virus replication to the more susceptible oligodendroglia cells and prevent the development of a fatal disease during the acute state of infection.

The occurrence of perivascular infiltrations in rats with SDE suggests a possible immunopathological mechanism in the pathogenesis of primary, virus-induced demyelination. Lymphocytes derived from these animals could be stimulated not only by virus antigen, but also by myelin basic protein. Moreover, adoptive transfer of such stimulated lymphocyte cell populations clearly led to CNS infiltration and clinical signs similar to those found in EAE. Therefore, infection of CNS tissue by JHM virus could lead to disturbances in the blood-brain barrier and breakdown or modification of myelin from infected cells, which might consequently result in sensitization of lymphoid cells against both viral and neuroantigens. These observations have to be followed by further experiments in order to characterize the functional role of different lymphocyte cell populations and their role in virus-induced demyelination.

SUMMARY

The murine coronavirus JHM is highly neurotropic for mice and rats. In rats, CNS diseases ranging from acute panencephalitis (AE) to subacute demyelinating encephalomyelitis (SDE) are observed. SDE develops after an incubation time of several weeks to months. Neuropa-

thologically, this disease is characterized by plaques of primary demyelination in selected areas of the CNS, and perivascular infiltrations. The incidence of SDE depends on properties of the virus clone used for infection and on host factors, such as age, immune status and genetic background. First experiments indicate that during viral infection, lymphocytes are sensitized against myelin basic protein and that this may contribute to the pathogenesis of demyelinating lesions in addition to the antiviral immune response.

ACKNOWLEDGEMENTS

We thank Margaret Sturm and Hanna Wege for excellent technical assistance and Helga Kriesinger for secretarial help. This work was supported by the Deutsche Forschungsgemeinschaft and Humboldt-Stiftung.

REFERENCES

- Bailey, O.T., Pappenheimer, A.M., Cheever, F.S. and Daniels, J.B. (1949) A murine virus (JHM) causing disseminated encephalomyelitis with extensive destruction of myelin II. *Pathology. J. exp. Med.*, 90: 195–212.
- Cheever, F.S., Daniels, J.B., Pappenheimer, A.M. and Bailey, O.T. (1949) A murine virus (JHM) causing disseminated encephalomyelitis with extensive destruction of myelin: I. Isolation and biological properties of the virus. *J. exp. Med.*, 90: 181–194.
- Fleury, H.J.A., Sheppard, R.D., Bornstein, M.B. and Raine, C.S. (1980) Further ultrastructural observations of virus morphogenesis and myelin pathology in JHM virus encephalomyelitis. *Neuropath. appl. Neurobiol.*, 6: 165–179.
- Haspel, V.M., Lampert, P.W. and Oldstone, M.B.A. (1978) Temperature-sensitive mutants of mouse hepatitis virus produce a high incidence of demyelination. *Proc. nat. Acad. Sci. U.S.A.*, 75: 4033–4036.
- Herndon, R.M., Griffin, D.E., McCormick, U. and Weiner, L.P. (1975) Mouse hepatitis virus-induced recurrent demyelination. *Arch. Neurol.*, 32: 32–35.
- Knobler, R.L., Dubois-Dalcq, M., Haspel, M.V., Claysmith, A.P., Lampert, P.W. and Oldstone, M.B.A. (1981) Selective localization of wild type and mutant mouse hepatitis virus (JHM strain) antigens in CNS tissue by fluorescence, light and electron microscopy. *J. Neuroimmunol.*, 1: 81–92.
- Lampert, P.W., Sims, J.K. and Kniazeff, A.J. (1973) Mechanism of demyelination in JHM virus encephalomyelitis. Electron microscopic studies. *Acta Neuropath.*, 24: 76–85.
- Nagashima, K., Wege, H., Meyermann, R. and ter Meulen, V. (1978) Corona virus induced subacute demyelinating encephalomyelitis in rats: a morphological analysis. *Acta Neuropath.*, 44: 63–70.
- Nagashima, K., Wege, H., Meyermann, R. and ter Meulen, V. (1979) Demyelinating encephalomyelitis induced by a long-term corona virus infection in rats. *Acta Neuropath.*, 45: 205–213.
- Powell, H.C. and Lampert, P.W. (1975) Oligodendrocytes and their myelin-plasma membrane connections in JHM mouse hepatitis virus encephalomyelitis. *Lab. Invest.*, 33: 440–445.
- Richert, J.R., Driscoll, B.F., Kies, M.W. and Alvord, E.C. (1979) Adoptive transfer of experimental allergic encephalomyelitis: incubation of rat spleen cells with specific antigen. *J. Immunol.*, 122: 494–496.
- Robb, J.A., Bond, C.W. and Leibowitz, J.L. (1979) Pathogenic murine coronaviruses. III. Biological and biochemical characterization of temperature-sensitive mutants of JHMV. *Virology*, 94: 385–399.
- Seelig, L.L. and Beer, A.E. (1978) Transepithelial migration of leukocytes in the mammary gland of lactating rats. *Biol. Reprod.*, 17: 730–744.
- Sorensen, O., Percy, D. and Dales, S. (1980) In vivo and in vitro models of demyelinating diseases. III. JHM virus infection of rats. *Arch. Neurol.*, 37: 478–484.
- Stohlman, S.A. and Weiner, L.P. (1981) Chronic central nervous system demyelination in mice after JHM virus infection. *Neurol.*, 31: 38–44.
- Ter Meulen, V. and Hall, W.W. (1978) Slow virus infections of the nervous system: virological, immunological and pathogenetic considerations, *J. gen. Virol.*, 41: 1–25.
- Wege, H., Müller, A. and ter Meulen, V. (1978) Genomic RNA of the murine coronavirus JHM. *J. gen. Virol.*, 41: 217–227.

- Wege, H., Siddell, S. and ter Meulen, V. (1982) The biology and pathogenesis of coronaviruses. *Current Top. Microbiol. Immunol.*, 99: 165–200.
- Weiner, L. (1973) Pathogenesis of demyelination induced by a mouse hepatitis virus (JHM virus). *Arch. Neurol.*, 28: 293–303.
- Weiner, L. and Stohlman, S.A. (1978) Viral models of demyelination. *Neurol.*, 28: 111–114.
- Wisniewski, H.M. (1977) Immunopathology of demyelination in autoimmune diseases and virus infections. *Brit. Med. Bull.*, 33: 54–59.