

Available online at www.sciencedirect.com

ScienceDirect

journal homepage: www.elsevier.com/locate/radcr

Case Report

Primary borderline mucinous tumor of the testis with postoperative metastasis: A rare case report [☆]

Yingyu Shi, Ling Song, Yan Luo^{*}

Department of Ultrasound, West China Hospital, Sichuan University, No.37 Guo Xuexiang, Chengdu, Sichuan, 610041, China

ARTICLE INFO

Article history:

Received 7 April 2023

Revised 16 May 2023

Accepted 22 May 2023

Keywords:

Mucinous cystadenoma

Testis

Case

ABSTRACT

Primary borderline mucinous tumor of the testis is extremely rare and belongs to the ovarian epithelial type. Testicular borderline mucinous tumor is intermediate in malignancy between benign mucinous cystadenoma and mucinous carcinoma, and their clinical treatment is mainly based on radical testicular resection. The reported cases with PBMTs have a good prognosis with no cases of recurrence or metastasis after surgery reported. However, we herein report a 21-year-old male who may be the first reported case of PBMT of the testis with postoperative tumor metastasis.

© 2023 The Authors. Published by Elsevier Inc. on behalf of University of Washington.

This is an open access article under the CC BY-NC-ND license (<http://creativecommons.org/licenses/by-nc-nd/4.0/>)

Introduction

Testicular borderline mucinous tumors are rare forms of ovarian epithelial tumors [1]. They possess malignant potential, and all reported cases have had a positive prognosis [2–6]. Here, we report a patient who initially received a misdiagnosis of benign mucinous tumor of the testis but later developed tumor metastasis after surgical intervention. Further examination of the pathological slides confirmed the diagnosis of testicular borderline mucinous tumor.

Case report

A 21-year-old male patient experienced gradual testicular enlargement over 1 year. The patient clearly indicated no sensa-

tions of fever or pain in the testis and had no history of trauma or infection. The patient reported a generally good state of health. During the physical examination, the clinical physician noted swelling of the right scrotum with normal skin color, texture, no rash, and no tenderness. Testicular ultrasound revealed abnormal morphology of the right testis with a cystic mass measuring approximately 54 × 35 × 52 mm in the lower part of the testis, with some normal testicular parenchymal echogenicity seen in the upper part. The mass had clear boundaries, regular shape, and internal irregular septations of varying thickness. Color Doppler flow imaging showed linear blood flow signals above the septum (Fig. 1).

Considering the risk of malignant tumors in the testis, we performed a radical orchiectomy for the patient. Preoperative serological examination showed an elevated level of beta-human chorionic gonadotropin (β -HCG) at 433.37 mIU/mL (normal range <3.81 mIU/mL), an elevated level of lactate de-

[☆] Competing Interests: The authors of this manuscript declare that we have no financial and personal relationships with other people or organizations that can inappropriately influence our work.

^{*} Corresponding author.

E-mail address: yanluo@scu.edu.cn (Y. Luo).

<https://doi.org/10.1016/j.radcr.2023.05.051>

1930-0433/© 2023 The Authors. Published by Elsevier Inc. on behalf of University of Washington. This is an open access article under the CC BY-NC-ND license (<http://creativecommons.org/licenses/by-nc-nd/4.0/>)

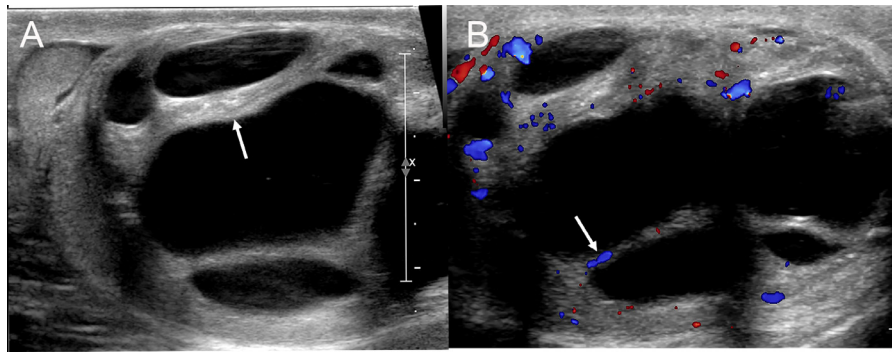


Fig. 1 – Primary borderline mucinous tumor of the testis: Ultrasound examination showed a cystic mass with clear boundaries and internal irregular septations of varying thickness (A, the arrow) and linear blood flow signals above the septum (B, the arrow) in Color Doppler flow imaging.

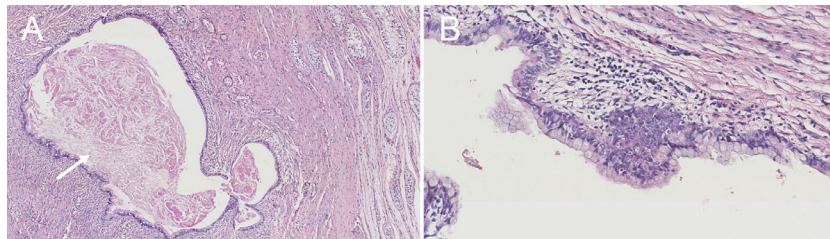


Fig. 2 – Histologically, the picture A showed the cyst filled with mucinous material (the arrow; HE, x5) and the picture B demonstrated that the wall of the cavity was lined by single or 2 layers of columnar mucinous epithelium (HE, x20).

hydrogenase (LDH) at 320 IU/L (normal range 110-220IU/L), and normal level of alpha-fetoprotein (AFP).

Postoperative pathological examination revealed a primary mucinous tumor in the testis (Fig. 2). The tumor appeared cystic with gelatinous material. Many septa were visible inside the cyst. Under the microscope, the tumor was found to be a multilocular cyst with mucinous secretions in the chambers. At the edge of the tumor, single or multiple layers of columnar epithelium were observed. The specimen's spermatic cord was not involved in the tumor. Immunohistochemical examination was not performed.

During a phone follow-up 3 months postorchietomy, the patient reported no discomfort. However, 6 months postoperatively, the patient presented with coughing. imaging studies revealed multiple metastases in the lungs, pancreas, and retroperitoneum (Fig. 3). The patient refused treatment and requested to be discharged. A revision of the pathological diagnosis to borderline mucinous tumor was made upon re-examination of the pathology slides.

Discussion

Mucinous tumor of the testis is a rare ovarian-type tumor with borderline mucinous tumor being intermediate in malignancy between benign mucinous tumor and mucinous carcinoma. Prognosis for most cases of borderline mucinous cystadenoma of the testis is favorable with limited postoperative recurrence

and metastasis. However, our case is a rare and highly invasive borderline mucinous cystadenoma of the testis.

Pathological examination is the diagnostic gold standard, and its results directly impact postoperative follow-up timing and frequency. Pathological specimens of borderline mucinous cystadenoma show single or multiple cystic lesions with an uneven cyst wall thickness. Under the microscope, the cyst wall is mainly composed of columnar epithelium with a few atypical hyperplasia, slight inflammation, or calcification. Conversely, benign primary mucinous cystadenoma shows tight cell connections of the cyst wall under the microscope without atypical hyperplasia and cells lacking nuclear atypia [7].

Misdiagnosis of benign mucinous cystadenoma can occur if malignant features are not identified during pathological examination. In previous literature reports, immunohistochemical staining of mucinous cystadenoma showed mostly positive results for CK7 (cytokeratin 7) and CK20 (cytokeratin 20) [8]. Immunohistochemical examination can differentiate between mucinous cystadenoma and serous cystadenoma, but it is challenging to differentiate between benign mucinous cystadenoma, borderline mucinous cystadenoma, and mucinous cystadenocarcinoma.

Therefore, it is crucial to consider imaging and laboratory test results from multiple perspectives. Testicular mucinous tumor needs to be distinguished from serous cystadenomas and teratomas on ultrasound. When encountering a case with a thick-walled cystic mass in the testis, one should be cautious about differentiating between teratomas and mucinous

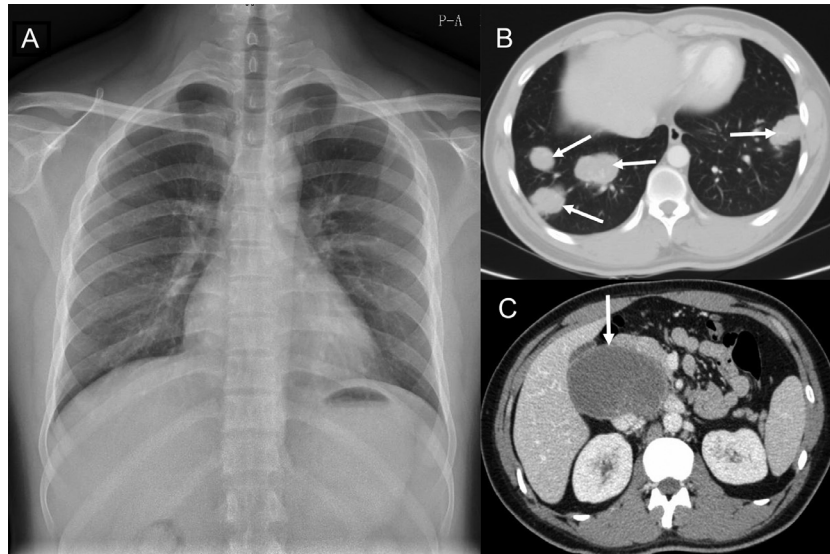


Fig. 3 – The chest X-ray image of the patient showed no obvious signs of abnormality before the operation (A) and 6 months after the operation, the contrast enhanced CT scan revealed multiple metastases in the lungs, pancreas, and retroperitoneum. (B and C, the arrows).

cystadenomas. And the septations showed uneven thickness and CDFI revealed punctate or linear flow signals within the septa. These features are considered malignant signs in cystic tumors of the testis.

The appearance of tissues under the microscope remains crucial. Ultrasound examination is the primary imaging modality for clinical diagnosis of testicular tumors. A preoperative imaging examination confirming a testicular mucinous tumor warrants unilateral radical orchiectomy to ensure the patient's prognosis. The patient's age was taken into consideration, and total orchiectomy was advised. However, erroneous pathology results led to neglected follow-up examinations, and the patient's prognosis is now poor.

This case highlights the importance of considering imaging and laboratory test results from multiple perspectives, especially in cases where pathological indications suggest benign conditions. Even with a benign pathology report, regular postoperative follow-up is crucial for determining the patient's actual condition and prognosis.

In conclusion, a comprehensive approach to diagnosis and postoperative management is vital for improving the accuracy of testicular mucinous tumor diagnosis, and management.

Patient consent

The study was approved by West China Hospital of Sichuan University Biomedical Research Ethics Committee. The patients had given their written informed consent.

REFERENCES

- [1] Amin MB. Selected other problematic testicular and paratesticular lesions: rete testis neoplasms and pseudotumors, mesothelial lesions and secondary tumors. *Mod Pathol* 2005;18(S2):S131–45. doi:10.1038/modpathol.3800314.
- [2] Wang Z, Cao H. Borderline mucinous tumor of testis: a case report. *Asian J Surg* 2021;44(10):1336–7. doi:10.1016/j.asjsur.2021.06.052.
- [3] Menon S, Desai S, Ahmed S. Primary borderline mucinous neoplasm of the testis: a case report and literature review. *Indian J Urol* 2012;28(2):224. doi:10.4103/0970-1591.98476.
- [4] Funada S, Yoshida T, Ito M, Kono F, Segawa T. Primary Borderline mucinous tumors of the testis: a case report and literature review. *Case Rep Oncol Med* 2015;2015:1–3. doi:10.1155/2015/863745.
- [5] Ulbright TM, Young RH. Primary mucinous tumors of the testis and paratestis: a report of nine Cases. *Am J Surg Pathol* 2003;27(9):1221–8. doi:10.1097/00000478-200309000-00005.
- [6] Hsieh A, Miller M, He W, Shin D. Serous borderline tumor of the testis and associated magnetic resonance imaging findings. *Urol Case Rep* 2017;14:30–2. doi:10.1016/j.eucr.2017.06.007.
- [7] Nokubi M, Kawai T, Mitsu S, Ishikawa S, Morinaga S. Mucinous cystadenoma of the testis. *Pathol Int* 2002;52(10):648–52. doi:10.1046/j.1440-1827.2002.01409.x.
- [8] Kim G, Kwon D, Na HY, Kim S, Moon KC. Mucinous cystadenoma of the testis: a case report with immunohistochemical findings. *J Pathol Transl Med* 2017;51(2):180–4. doi:10.4132/jptm.2016.08.30.