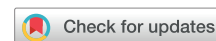



Since January 2020 Elsevier has created a COVID-19 resource centre with free information in English and Mandarin on the novel coronavirus COVID-19. The COVID-19 resource centre is hosted on Elsevier Connect, the company's public news and information website.

Elsevier hereby grants permission to make all its COVID-19-related research that is available on the COVID-19 resource centre - including this research content - immediately available in PubMed Central and other publicly funded repositories, such as the WHO COVID database with rights for unrestricted research re-use and analyses in any form or by any means with acknowledgement of the original source. These permissions are granted for free by Elsevier for as long as the COVID-19 resource centre remains active.

# New Pulmonary Infiltrates Observed on Computed Tomography-Based Image Guidance for Radiotherapy Warrant Diagnostic Workup for Coronavirus Disease 2019



Graham W. Warren, MD, PhD,<sup>a,\*</sup> Vun-Sin Lim, PhD,<sup>b</sup> Mudit Chowdhary, MD,<sup>c</sup> Gaurav Marwaha, MD,<sup>c</sup> Osama Mostafa Abd Elbadee, MD, PhD,<sup>d</sup> Esra Korkmaz Kirakli, MD,<sup>e</sup> Charlotte Billiet, MD, PhD,<sup>f,g</sup> Alexandra Giraldo Marin, MD,<sup>h</sup> Monica Ramos, MD,<sup>h</sup> Morten Hiul Suppli, MD, PhD,<sup>i</sup> Gwendolyn J. McGinnis, MD, MS,<sup>j</sup> Alex A. Adjei, MD, PhD<sup>k</sup>

<sup>a</sup>Department of Radiation Oncology, Medical University of South Carolina, Charleston, South Carolina

<sup>b</sup>International Association for the Study of Lung Cancer, Denver, Colorado

<sup>c</sup>Department of Radiation Oncology, Rush University Medical Center, Chicago, Illinois

<sup>d</sup>Radiotherapy Department, South Egypt Cancer Institute, Assuit, Egypt

<sup>e</sup>Department of Radiation Oncology, Dr. Suat Seren Chest Diseases and Surgery Research and Training Hospital, Ismir, Turkey

<sup>f</sup>Department of Radiation Oncology, Iridium Network, Antwerp, Belgium

<sup>g</sup>Center for Oncological Research (CORE), Integrated Personalized and Precision Oncology Network (IPPON), University of Antwerp, Antwerp, Belgium

<sup>h</sup>Department of Radiation Oncology, Vall d'Hebron University Hospital, Barcelona, Spain

<sup>i</sup>Department of Oncology, Copenhagen University Hospital, Rigshospitalet, Copenhagen, Denmark

<sup>j</sup>Department of Radiation Oncology, University of Texas MD Anderson Cancer Center, Houston, Texas

<sup>k</sup>Department of Oncology and Pharmacology, Mayo Clinic, Rochester, Minnesota

Received 24 February 2021; revised 21 May 2021; accepted 8 June 2021

Available online - 22 June 2021

## ABSTRACT

**Introduction:** Screening for coronavirus disease 2019 (COVID-19) exposure, coupled with engaged decision making to prioritize cancer treatment in parallel with reducing risk of exposure and infection, is crucial in the management of COVID-19 during cancer treatment. After two reported case studies of imaging findings during daily computed tomography (CT)-based image-guided radiotherapy (RT) scans, a call for submission of anonymized case reports was published with the objective of rapidly determining if there was a correlation between the onset of new pulmonary infiltrates found during RT and COVID-19. We hereby report the results of the aggregate analysis.

**Methods:** Data of deidentified case reports for patients who developed biochemically confirmed COVID-19 during RT were submitted through an online portal. Information requested included a patient's sex, age, cancer diagnosis and treatment, and COVID-19 diagnosis and outcome. Coplanar CT-based imaging was requested to reveal the presence or absence of ground-glass opacities or infiltrates.

**Results:** A total of seven reports were submitted from Turkey, Spain, Belgium, Egypt, and the United States.

Results and imaging from the patients reported by Suppli et al. and McGinnis et al. were included for a total of nine patients for analysis. All patients were confirmed COVID-19 positive using polymerase chain reaction-based methods or nasopharyngeal swabs. Of the nine patients analyzed, abnormalities consistent with ground-glass opacities or infiltrates were observed in eight patients.

**Conclusions:** This is the largest case series revealing the potential use of CT-based image guidance during RT as a tool for identifying patients who need further workup for COVID-19. Considerations for reviewing image guidance for new pulmonary infiltrates and immediate COVID-19 testing

\*Corresponding author.

**Disclosure:** The authors declare no conflict of interest.

Address for correspondence: Graham W. Warren, MD, PhD, Department of Radiation Oncology, Medical University of South Carolina, 169 Ashley Avenue, MSC 318, Charleston, SC 29425 E-mail: [warrengw@musc.edu](mailto:warrengw@musc.edu)

© 2021 International Association for the Study of Lung Cancer. Published by Elsevier Inc. All rights reserved.

ISSN: 1556-0864

<https://doi.org/10.1016/j.jtho.2021.06.005>

in patients who develop new infiltrates even without COVID-19 symptoms are strongly encouraged.

© 2021 International Association for the Study of Lung Cancer. Published by Elsevier Inc. All rights reserved.

*Keywords:* COVID-19; Computed tomography; Radiotherapy; Ground-glass opacities

## Introduction

In the previous year, the coronavirus disease 2019 (COVID-19) caused by the severe acute respiratory syndrome coronavirus 2 has spread to all corners of the globe. By mid-May 2021, global tracking through Johns Hopkins University estimates more than 165 million cases worldwide, including approximately 33 million cases in the United States, 25 million cases in India, 15 million cases in Brazil, and more than 1 million cases in 25 other countries.<sup>1</sup> Approximately 3.4 million deaths have already been attributable to COVID-19, and the COVID-19 pandemic is accelerating as third waves across multiple countries through early 2021. Although COVID-19 is most often associated with severe acute respiratory syndrome, it can affect a wide spectrum of organ systems with substantial effects on the lungs, heart, gastrointestinal tract, kidneys, circulatory system, immune system, and even the brain.<sup>2,3</sup> Cancer treatment has been disrupted by the COVID-19 pandemic including delays in screening that may ultimately lead to substantial changes in survival patterns owing to delays in starting or pauses of active treatment and patient reticence to address medical issues for fear of contracting COVID-19.<sup>4,5</sup> Addressing COVID-19 during cancer treatment requires close coordination across health systems to accurately screen for COVID-19 exposure and infection, coupled with engaged decision making to prioritize cancer treatment in parallel with reducing risk of exposure.<sup>6</sup> Furthermore, patients with cancer who develop COVID-19 require careful consideration of the urgency to treat cancer while balancing the need to manage COVID-19 and risking exposure to other patients with cancer.

Screening for COVID-19 in the general population is based on assessing exposure, symptoms, and testing using polymerase chain reaction (PCR) or serologic antibody-based assays.<sup>7</sup> People suspected of infection can receive further testing including radiologic thoracic imaging to evaluate for the presence of pulmonary infiltrates. A recent Cochrane review across 34 studies suggested a pooled sensitivity of 89.9% and specificity of 61.1% for computed tomography (CT)-based imaging.<sup>8</sup> Nevertheless, authors noted a high or unclear risk of bias. In April 2020, two separate groups reported case studies of imaging findings during daily CT-based

image-guided radiotherapy (RT) scans.<sup>9,10</sup> A subsequent call for submission of anonymized case reports was published to try and ascertain if similar findings were observed during RT.<sup>11</sup> Results of submissions are reported in the subsequent texts.

## Methods

A call for aggregation of deidentified case reports for patients who developed biochemically confirmed COVID-19 during RT was published in April 2020.<sup>11</sup> The primary objective was to determine whether there was a correlation between the onset of new pulmonary infiltrates found during RT and a diagnosis of COVID-19. Submitting groups would send anonymized data through an online link. Data requested included a patient's sex, age, cancer diagnosis, histologic evaluation, cancer stage, chemotherapy agent, planned RT dose, completed RT dose, method of COVID-19 diagnosis, date of COVID-19 diagnosis relative to the start of RT, date of COVID-19 symptoms relative to the start of RT, any COVID-19 symptoms, and data related to patient care and outcome. Reporting for outcome was at the discretion of the submitting contributors as a free text field. Coplanar CT-based imaging was requested to reveal the presence or absence of ground-glass opacities or infiltrates. Because of the expected variability of imaging quality among contributors and different institutional practices for daily image verification, there were no stipulations regarding select imaging and contributors were allowed to submit representative images at their own discretion. Furthermore, because deidentified data were reported such that subjects could not be identified, this study is exempt as supported by the Code of Federal Regulations section 45, part 46.

## Results

A total of seven reports were submitted through the online portal representing cases from Turkey, Spain, Belgium, Egypt, and the United States. The case of patient one was subsequently published<sup>12</sup> and included in this report with author's permission under the Creative Commons Attribution License. Results and imaging from the patients reported by Suppli et al.<sup>9</sup> and McGinnis et al.<sup>10</sup> were included for a total of nine patients for analysis (Table 1). The nine patients presented included four females and one patient with metastatic disease. All patients were confirmed COVID-19 positive using PCR-based methods or nasopharyngeal swabs. All nine patients were diagnosed with lung cancer, including four with squamous cell carcinoma and five with adenocarcinoma.

The cancer treatment characteristics and COVID-19 outcomes are reported in Table 2. Chemotherapy was

Table 1. Patient Characteristics

Patient	Sex	Age	Cancer Diagnosis	Histologic Classification	Cancer Stage	Method of COVID-19 Diagnosis
1 (Kirakli et al. <sup>12</sup> )	M	61	Lung	AC	T4N2M1	PCR
2	M	72	Lung	SCC	T4N2M0	NPS
3	M	65	Lung	SCC	T4N0M0	PCR
4	F	74	Lung	AC	T3N2M0	PCR
5	M	66	Lung	AC	TxN3M0	NPS
6	F	63	Lung	SCC	T4N0M0	PCR
7	F	77	Lung	SCC	T1cN2M0	NPS
8 (Suppli et al. <sup>9</sup> )	M	74	Lung	AC	T3N2M0	PCR
9 (McGinnis et al. <sup>10</sup> )	F	63	Lung	AC	Recurrent	PCR

AC, adenocarcinoma; COVID-19, coronavirus disease 2019; F, female; M, male; NPS, nasopharyngeal swab; PCR, polymerase chain reaction; SCC, squamous cell carcinoma.

used as a part of cancer treatment for seven patients, and one patient was on a trial for immunotherapy in combination with stereotactic ablative RT. The planned course of RT was completed by three patients, with the remaining patients having treatment interrupted or discontinued. Symptoms were noted in six patients with fever the most common symptom present in all six patients. Hospitalization occurred in seven patients, including one patient who was hospitalized without

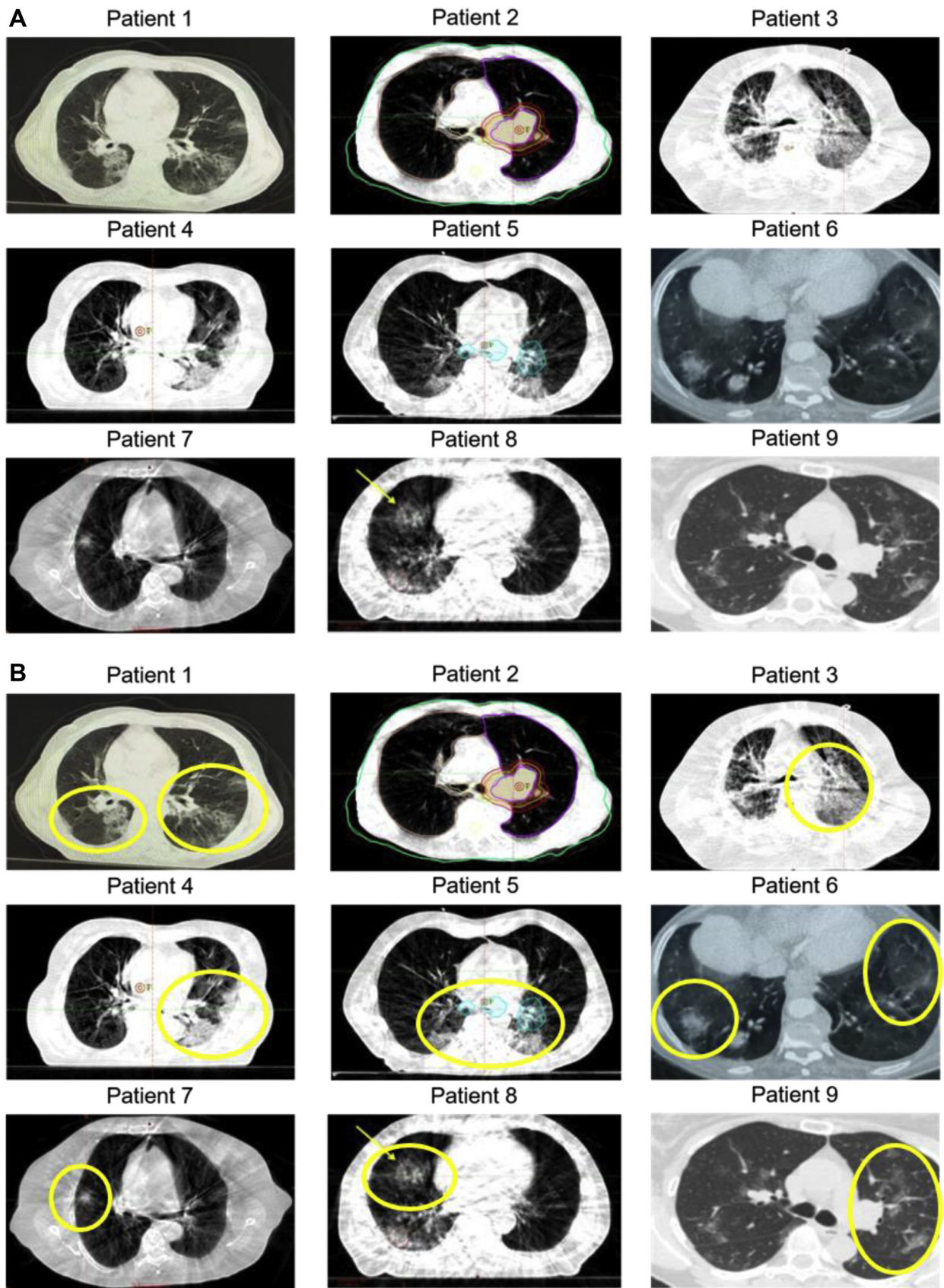
symptoms as part of standard local policy. As of the date of data submission, deaths were reported in two patients.

Figure 1 reveals CT findings submitted as screenshots for each patient. Images submitted by contributors were analyzed, and it was decided to present representative axial images for consistency across all patients (Fig. 1A). Of nine sets of patient images, abnormalities consistent with ground-glass opacities or infiltrates were observed

Table 2. Cancer Treatment and COVID-19 Outcomes

Patient	Planned RT Dose (Gy)	RT Dose Completed	Chemotherapy	COVID-19 Symptoms	Hospitalized	Overall Patient Outcome
1 (Kirakli et al. <sup>12</sup> )	20	0	None	None	Yes	CT findings before starting RT, asymptomatic but hospitalized owing to local policy, symptoms 48 h after CT simulation, discharged from hospital after 20 d
2	60	60	Carboplatin, paclitaxel	Fever, cough	Yes	Completed RT as inpatient, chemotherapy held after COVID-19 diagnosis, discharged from hospital after 2 consecutive negative tests
3	60	46	Carboplatin, paclitaxel	None	Yes	Admitted for neutropenia and esophagitis (not COVID-19), oncology treatment resumed as an inpatient, additional COVID-19 exposure while hospitalized, death from COVID-19
4	55	50	Cisplatin, pemetrexed	Fever	Yes	Recovered
5	66	24	Cisplatin, pemetrexed	Fever, cough, loss of smell/taste	Yes	RT interrupted, 4 wk hospitalization with severe illness at the time of submission
6	60	38	Cisplatin, etoposide	Fever	No	Self-isolating at home
7	60	60	Carboplatin, etoposide	Fever, cough	Yes	Completed RT 4 d before COVID-19 diagnosis, discharged to rehabilitation facility after 5 d, 2 negative tests 1 mo after
8 (Suppli et al. <sup>9</sup> )	60	18	Platinum doublet	Fever, cough, fatigue, myalgia	Yes	Death from respiratory failure 6 d after symptoms
9 (McGinnis et al. <sup>10</sup> )	50	50	None	None	No	Asymptomatic, completed SABR

COVID-19, coronavirus disease 2019; CT, computed tomography; RT, radiotherapy; SABR, stereotactic ablative radiotherapy.



**Figure 1.** Cross-sectional imaging of patients. Representative axial images are displayed. (A) Submitted axial images are displayed for each patient. Images submitted were not altered for enhancement but formatted for size and fit within the figure. (B) Areas with ground-glass opacities or infiltrates are highlighted in yellow for each patient. Patient 2 had no observed infiltrates or ground-glass opacities on any submitted images. Patient 1 (Kirakli et al.<sup>12</sup>); patient 8 (Suppli et al.<sup>9</sup>); patient 9.<sup>10</sup>

in eight patients (Fig. 1B). Only one patient (patient 2) had no observable opacities or infiltrates on submitted images.

## Discussion

Initial reports suggest that patients with lung cancer who develop COVID-19 have observable infiltrates or ground-glass opacities that can be detected during CT-based image guidance for RT. Data do not support guidance on how to manage patients or whether RT procedures should be disrupted. Furthermore, data are insufficient to provide guidance on any COVID-19 outcomes. Nevertheless, data do support the conclusion that new ground-glass opacities or pulmonary infiltrates observed during CT-based image guidance warrant further diagnostic evaluation for COVID-19.

Screening patients during RT setup procedures has been discussed as a potentially useful tool for detecting COVID-19.<sup>13</sup> In a letter to the editor, analysis of temperature screening yielded a comparable detection rate as compared with CT screening at the time of RT setup, both approximately 0.5%.<sup>14</sup> A typical course of conventional RT could consist of 2 to 3 weeks for consultation and RT setup and 5 to 7 weeks for RT treatment. This results in 7 to 10 weeks of potential exposure time for a typical patient within a RT department. Patients can be exposed before or during treatment, and a single point-of-care assessment is likely to misrepresent risk in the entirety of treatment. For patients receiving daily or weekly CT-based image guidance, this would enable screening both at the time of RT setup with a CT simulation and repeated assessments for the 5 to 7 weeks of treatment. Monitoring CT scans for changes suggesting ground-glass opacities or infiltrates may not add any time or burden to treatment staff but would require additional time for people responsible for image review. This could represent an added time burden for physicians. Nevertheless, the reward for this added time could be an increased detection of COVID-19 exposure and a secondary system for alerting clinicians and patients for dedicated COVID-19 screening. Increased early detection is anticipated to reduce overall exposure within an oncology clinic and ultimately reduce impact on effective cancer treatment.

The objective of this aggregation of cases was to rapidly determine if there was a correlation between the onset of new pulmonary infiltrates found during RT and COVID-19.<sup>11</sup> The nine cases presented suggest that there is a correlation and support consideration of further COVID-19 screening and workup for any patients exhibiting new infiltrates during the pandemic. There are several limitations to any interpretation beyond this conclusion. There were no data collected on patients who did not have COVID-19, thus limiting the ability to

estimate any sensitivity or specificity for new pulmonary infiltrates. Though most patients exhibited symptoms, there are likely many COVID-19-positive patients who were asymptomatic and who were never screened for COVID-19. It was recognized early that responses were anticipated to be multinational and that submission of CT-based images used for RT would have a wide range of institution-specific technical capability and standard practice procedures. For this reason, the request for images was liberal and did not require specific image quality or anatomical representation. Although this limits the quality of interpretation, the observation that eight of nine patients had new observable pulmonary infiltrates across a spectrum of technical capability and practice strengthens the potential use of CT-based image guidance as a potential screening tool for COVID-19. It is also important to note that method of COVID-19 detection was described as “nasopharyngeal swabs” in three reports. Although PCR was the likely method, it is possible that alternative tests, such as rapid antigens using nasopharyngeal swabs, were used, and potential variations in accuracy among different tests were not available.

To the authors' knowledge, this is the largest case series revealing the potential use of CT-based image guidance during RT as a tool for identifying patients who need further workup for COVID-19. It is anticipated that collecting a large structured data set providing strong estimates of sensitivity, specificity, and with well-defined imaging criteria would take a moderately long time and limit access to information that could immediately benefit patients during the ongoing pandemic. Two recommendations arise from these cases. First, radiation oncologists and RT departments should strongly consider reviewing image guidance for new pulmonary infiltrates and consider immediate COVID-19 testing in patients who develop new infiltrates even without COVID-19 symptoms. Second, substantially more data are needed to determine the sensitivity and specificity of these findings and the temporal nature. Although highly effective COVID-19 vaccines are available at the time of completing this report, there is substantial variability in vaccine distribution and uptake across different countries, and it may take years before a substantial number of individuals are vaccinated globally to achieve herd immunity. It is anticipated that COVID-19 infection may become endemic or seasonal, akin to the common influenzas. Thus, these findings are anticipated to remain relevant for several years.

## CRedit Authorship Contribution Statement

**Graham W. Warren:** Conceptualization, Methodology, Formal analysis, Writing-original draft preparation, reviewing, and editing, Visualization, Supervision

**Vun-Sin Lim:** Methodology, Data curation, Project administration, Editing

**Mudit Chowdhary, Gaurav Marwaha, Osama Mostafa Abd Elbadee, Esra Korkmaz Kirakli, Charlotte Billiet, Alexandra Giraldo Marin, Monica Ramos, Morten Hiul Suppli, Gwendolyn J. McGinnis:** Investigation, Resources

**Alex A. Adjei:** Conceptualization, Methodology, Writing-original draft preparation, Supervision

## References

1. Johns Hopkins University (JHU). COVID-19 dashboard by the Center for Systems Science and Engineering (CSSE). <https://coronavirus.jhu.edu/map.html>. Accessed December 11, 2020.
2. Wadman M, Couzin-Frankel J, Kaiser J, Maticic C. How does coronavirus kill? Clinicians trace a ferocious rampage through the body, from the brain to toes. *Science*. <https://www.sciencemag.org/news/2020/04/how-does-coronavirus-kill-clinicians-trace-ferocious-rampage-through-body-brain-toes>. Accessed May 10, 2021.
3. Gupta A, Madhavan MV, Sehgal K, et al. Extrapulmonary manifestations of COVID-19. *Nat Med*. 2020;26:1017-1032.
4. Sharpless NE. COVID-19 and cancer. *Science*. 2020;368:1290.
5. Bakouny Z, Hawley JE, Choueiri TK, et al. COVID-19 and cancer: current challenges and perspectives. *Cancer Cell*. 2020;38:629-646.
6. Dingemans AC, Soo RA, Jazieh AR, et al. Treatment guidance for patients with lung cancer during the coronavirus 2019 pandemic. *J Thorac Oncol*. 2020;15:1119-1136.
7. Dinnes J, Deeks JJ, Adriano A, et al. Cochrane COVID-19 Diagnostic Test Accuracy Group. Rapid, point-of-care antigen and molecular-based tests for diagnosis of SARS-CoV-2 infection. *Cochrane Database Syst Rev*. 2020;8:CD013705.
8. Islam N, Salameh JP, Leeftang MM, et al. Cochrane COVID-19 Diagnostic Test Accuracy Group. Thoracic imaging tests for the diagnosis of COVID-19. *Cochrane Database Syst Rev*. 2020;(11):CD013639.
9. Suppli MH, Riisgaard de Blanck S, Elgaard T, Josipovic M, Pøhl M. Early appearance of coronavirus disease 2019 associated pulmonary infiltrates during daily radiotherapy imaging for lung cancer. *J Thorac Oncol*. 2020;15:1081-1084.
10. McGinnis GJ, Ning MS, Nitsch PL, et al. Rapid detection of asymptomatic coronavirus disease 2019 by computed tomography image guidance for stereotactic ablative radiotherapy. *J Thorac Oncol*. 2020;15:1085-1087.
11. Warren GW, Adjei AA. A call for rapid submission of data for aggregate review: can daily radiotherapy imaging be used as a potential screen for coronavirus disease 2019? *J Thorac Oncol*. 2020;15:876-877.
12. Kirakli EK, Erdem S, Yılmaz H. RT. Imaging as an unintended COVID-19 diagnostic tool: can be used for screening before thoracic RT? *Clin Case Rep Int*. 2021;5:1210.
13. Vitullo A, De Santis MC, Marchianò A, Valdagni R, Lozza L. The simulation-CT: radiotherapy's useful tool in the race against COVID-19 pandemic. A serendipity approach. *Radiother Oncol*. 2020;147:151-152.
14. Nevens D, Billiet C, Weytjens R, et al. The use of simulation-CTs as a coronavirus disease 2019 screening tool during the severe acute respiratory syndrome coronavirus 2 pandemic. *Radiother Oncol*. 2020;151:17-19.