

## Original Article



# Time-lapse imaging of sentinel lymph node using indocyanine green with near-infrared fluorescence imaging in early endometrial cancer

Hyun Jin Choi, Tae-Joong Kim, Yoo-Young Lee, Jeong-Won Lee, Byoung-Gie Kim, Duk-Soo Bae

Department of Obstetrics and Gynecology, Samsung Medical Center, Sungkyunkwan University School of Medicine, Seoul, Korea

## OPEN ACCESS

Received: Dec 1, 2015

Revised: Dec 18, 2015

Accepted: Dec 23, 2015

### Correspondence to

Tae-Joong Kim

Department of Obstetrics and Gynecology, Samsung Medical Center, Sungkyunkwan University School of Medicine, 81 Irwon-ro, Gangnam-gu, Seoul 06351, Korea.  
E-mail: tj28.kim@gmail.com

Copyright © 2016. Asian Society of Gynecologic Oncology, Korean Society of Gynecologic Oncology

This is an Open Access article distributed under the terms of the Creative Commons Attribution Non-Commercial License (<http://creativecommons.org/licenses/by-nc/4.0/>) which permits unrestricted non-commercial use, distribution, and reproduction in any medium, provided the original work is properly cited.

### ORCID

Hyun Jin Choi

<http://orcid.org/0000-0003-4058-9094>

Tae-Joong Kim

<http://orcid.org/0000-0002-9693-9164>

## ABSTRACT

**Objective:** Indocyanine green with near-infrared fluorescence imaging (NIR-ICG) is a new tracer modality in the limelight used for lymphatic mapping. The advantage of this method is to provide real-time image during surgery. To use ICG for image guided lymph node dissection, a surgeon needs to know initial appearing time and duration.

**Methods:** A 52-year-old woman undertook surgery diagnosed with endometrial cancer. She had no past medical history and her body mass index was 25.3 kg/m<sup>2</sup>. Preoperative magnetic resonance imaging examination revealed 2.7 cm sized cancerous mass in the endometrial cavity with superficial myometrial invasion without lymph node enlargement. Four mL (1.25 mg/mL) of ICG solution was prepared for injection. For each site, 1 mL of solution was injected superficially, 2–3 mm into the cervical submucosa and another 1 mL was injected deep, 1–2 cm into the stroma of the cervix [1,2]. We recorded video with 30° 10 mm scope equipped with a specific lens and light source emitting both visible and NIR light (KARL STORZ GmbH & Co. KG, Tuttlingen, Germany).

**Results:** Pelvic lymph node was visualized from around 5 minutes. ICG was dispersed into organs after hysterectomy (53 minutes after ICG injection), yet we could clearly identify sentinel lymph node (SLN). Pathology revealed endometrioid adenocarcinoma grade I, myometrial invasion with less than half of myometrium and no lymph node metastasis.

**Conclusion:** Cervical injection of ICG provides good visualization of SLN from 5 minutes to over an hour. Our film gives an idea about time management to make a plan for surgery and not to miss SNLs.

**Keywords:** Endometrial Neoplasms; Fluorescence; Laparoscopy; Indocyanine Green; Lymph Nodes; Time Management

Yoo-Young Lee

<http://orcid.org/0000-0002-6951-4558>

Jeong-Won Lee

<http://orcid.org/0000-0002-6945-0398>

Byoung-Gie Kim

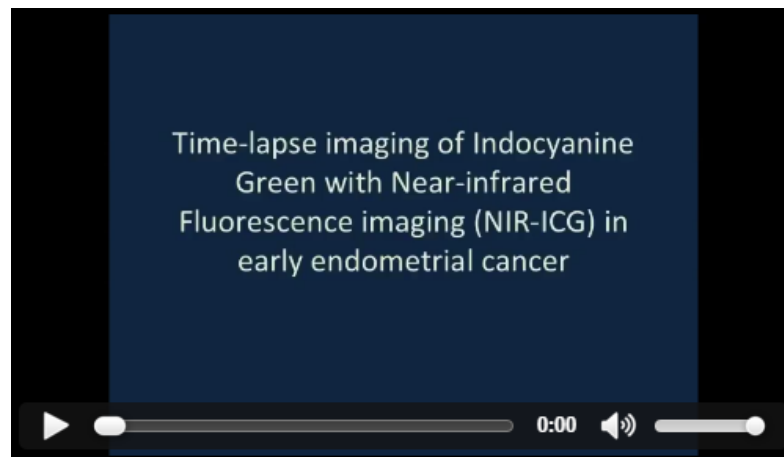
<http://orcid.org/0000-0002-0572-8450>

**Conflict of Interest**

No potential conflict of interest relevant to this article was reported.

## VIDEO CLIP

Time-lapse imaging of sentinel lymph node using indocyanine green with near-infrared fluorescence imaging in early endometrial cancer.



Video can be found with this article online at <http://ejgo.org/src/sm/jgo-27-e27-s001.mp4>.

## REFERENCES

1. Abu-Rustum NR, Khoury-Collado F, Pandit-Taskar N, Soslow RA, Dao F, Sonoda Y, et al. Sentinel lymph node mapping for grade 1 endometrial cancer: is it the answer to the surgical staging dilemma? *Gynecol Oncol* 2009;113:163-9.  
[PUBMED](#) | [CROSSREF](#)
2. How J, Gotlieb WH, Press JZ, Abitbol J, Pelmus M, Ferenczy A, et al. Comparing indocyanine green, technetium, and blue dye for sentinel lymph node mapping in endometrial cancer. *Gynecol Oncol* 2015;137:436-42.  
[PUBMED](#) | [CROSSREF](#)