


# The Application of Modified Kite Flap: A Novel Technique for Reconstruction of Defects in Areas with High Tension

Qiaochu Zhou 

Department of Dermatology, Wenzhou Hospital of Integrated Traditional Chinese and Western Medicine, Affiliated Hospital of Integrated Traditional Chinese and Western Medicine of Shanghai University, Wenzhou, Zhejiang, People's Republic of China

Correspondence: Qiaochu Zhou, Wenzhou Hospital of Integrated Traditional Chinese and Western Medicine, Affiliated Hospital of Integrated Traditional Chinese and Western Medicine of Shanghai University, 75 Jinxiu, Wenzhou, Zhejiang, 325000, People's Republic of China, Tel +86-13906653000, Fax +86 57788217398, Email transferzhou@sina.com

**Objective:** It is challenging to reconstruct defects resulting from surgical procedures in areas with high tension. We present modified kite flaps that allowed us to reconstruct the defect with high mechanical tension.

**Methods:** With the combination of advancement and rotation, the defect using bilateral modified kite flaps closes with significantly reduced tension. The double flap not only advances but also rotates the flap. This technique retained and exploited the limbs of the flaps, which were often removed with the traditional V-Y flaps.

**Results:** Eleven patients have had their surgical defects repaired using this technique, and the results were satisfactory. A follow-up period of three months or longer was conducted. There were no perioperative complications, and major anatomic landmarks were reconstructed. All patients were satisfied with the functional recovery.

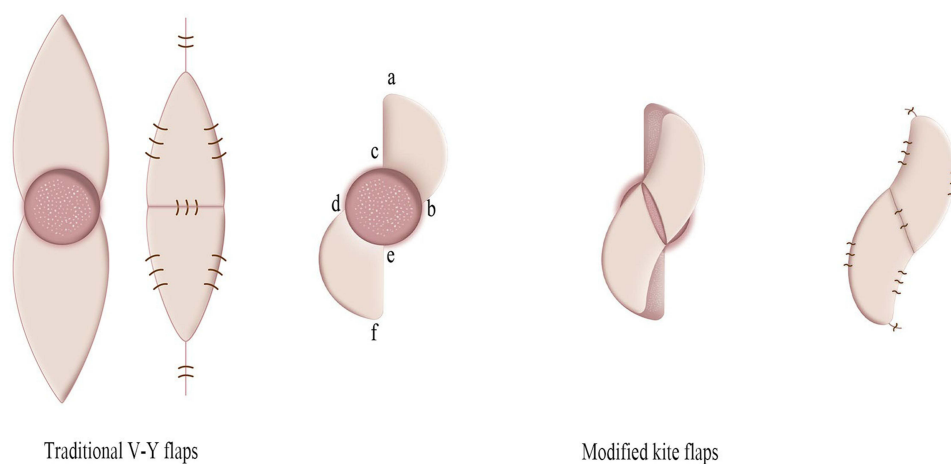
**Conclusion:** The modified method enables a significantly shortened advancement distance of flaps, more flexible flap movement, and sacrifice of healthy tissue to be minimal, and significantly diminished tension for closure. Approximately half the width and length of traditional V-Y flaps were used in this flap donor. Preserving the flap limbs, which were often removed with the traditional V-Y flaps, was also applied to fill defects. Modified kite flaps are a suitable option for the repair of defects in areas with high tension.

**Keywords:** skin defects, kite flap, V-Y flap, flap, surgery

## Introduction

Primary wound closure is not possible in many cases of complex defects. Through the use of flaps, ideal results can be obtained in these situations. Reconstructive surgery depends on the size and location of the defects. Various methods are available to close moderate and small defects, such as rhomboid flaps, keystone flaps, and bilobed flaps. Each with its advantages and disadvantages. Rhomboid flaps are commonly used techniques. Rhomboid flaps may be used in some regions, such as the axilla, genital region, or nipple-areola, but their distortion effects should be avoided.<sup>1</sup> Using fasciocutaneous perforators, Keystone island flaps have a trapezoidal shape and a growing array of applications in reconstructive surgeries for the closure of defects. The Keystone Island flap has the advantage of a low complication rate and a quick recovery time.<sup>2,3</sup> However, a study with wound tension and closability with keystone flaps, V-Y flaps, and primary closure revealed that the data raise questions about the biomechanical benefits of keystone flaps.<sup>4</sup> Normally, a bilobed flap is used to reconstruct round defects.<sup>5</sup> Bilobed flaps with different modifications could be considered in the reconstruction of reconstructions of the trunk, foot defects, and facial defects.

For larger defects, it is useful to close defects and reconstruct areas using skin flap techniques such as kite flaps (also known as V-Y flaps). Despite many options, it is still challenging to reconstruct defects resulting from surgical procedures in areas with high tension. The surgical defects are complicated by the inherently higher tension in these areas created by the relative inflexibility of the skin, such as nasofacial, chest, shoulder back, and limb areas. Moderate to



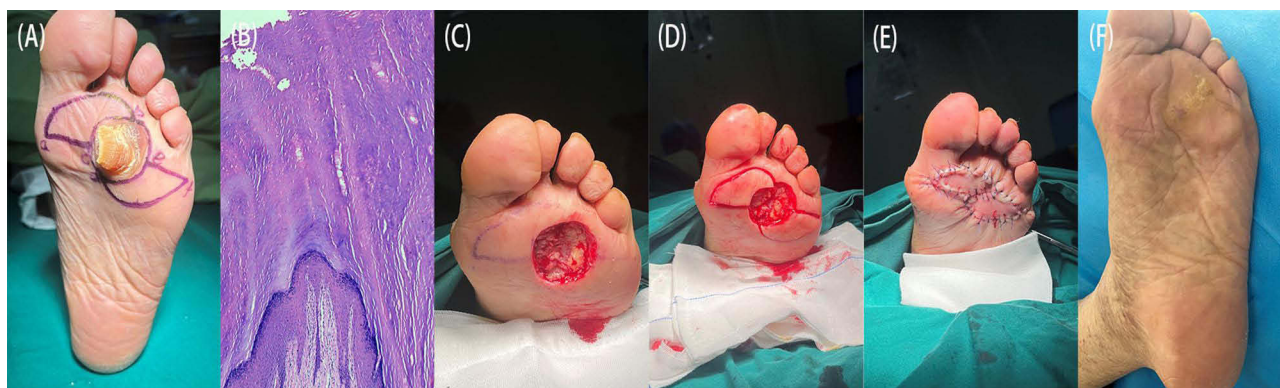
**Figure 1** Schematic diagram of traditional V-Y flaps and modified kite flaps. Marking the endpoints of the flaps as a-f.

large defects, especially in tension-prone areas, the mobility and the ability to cover up large defects of traditional kite flaps may be reduced. Prepared for wound closure would need larger grafts, and the sacrifice of healthy tissue was increasing. Wound closure tension affects flap blood supply and survival, and dehiscence and wound edge necrosis are caused by high closure tension. In such cases, we argue that modified kite flaps might be advantageous for areas of high mechanical tension (Figure 1).

## Methods

Eleven patients aged 29–93 years old had their surgical defects repaired using our modified technique. The treatment using modified kite flaps for reconstruction of defects in areas with high tension was performed for all eleven patients. Both a clinical and a pathological diagnosis were made for each patient. A giant cutaneous horn was diagnosed in one patient, three congenital melanocytic nevi in three others, four basal cell carcinomas in four others, and three squamous cell carcinomas in three others. The skin defects in two cases were located in the nasofacial, three cases in the lower back, two cases in the upper back, and four cases in the plantar surface. The technique was approved by the ethical committee of Wenzhou Hospital of Integrated Traditional Chinese and Western Medicine.

Here is an example of the surgical approach taken in a typical case. An 84-year-old woman presented with a 5-year history of a giant cutaneous horn lesion developing from a nodule on her left plantar (Figure 2A). She had experienced pain during walking, but no other symptoms. Physical examination revealed a yellowish horny hyperkeratotic lesion with a base of about 3.7 cm in diameter, and no ulceration or regional lymphadenopathy. The modified kite flap was designed.



**Figure 2** Preoperative view (A) pathology showed squamous epithelial hyperplasia, keratinized structures (B) a defect with high tension (C) modified kite flaps were used for repairing (D) modified kite flaps repaired the large defect (E) 3 months follow-up, excellent cosmetic and functional results received (F).

The width of the flap was slightly higher than half of the diameter of the resection range, achieving about 2.4cm. The length of the flaps on both sides (ie the sum of the two) to reach a ratio of 1.5 times the diameter of the resection range, both achieving about 2.8cm. An excision of the patient's cutaneous horn was performed, and a histopathological examination was conducted. Findings revealed squamous epithelial hyperplasia, keratinized structures, and a prominent granular layer (Figure 2B). At the base of the lesion, there were no malignant findings.

During the operation, a defect with high mechanical tension required reconstruction (Figure 2C). The flaps for reconstructive surgery depend on the size and location of the defects and traditional V-Y advancement flaps frequently have more than two times the surgical defect's width. For large defects with high mechanical tension, the traditional V-Y advancement flap may require more healthy tissue sacrifice. It left a long scar.<sup>6</sup> This resulted in a difficult suture of this defect or an increase in the operation time and postoperative complications. Traditionally, kite flaps lacked mobility, so improvements were needed.<sup>7</sup> For this defect condition, reconstruction with modified kite flaps was the consideration. To address this issue, we modified the traditional kite flaps with the combined application of rotation flaps (Figure 2D). The incision line of two approximately triangular flaps that were located on either side of the midline of the defect was designed. The double flaps, which differed from traditional V-Y advancement flaps with opposing bottom edges, were staggered relative to each other, which was beneficial for flap rotation.

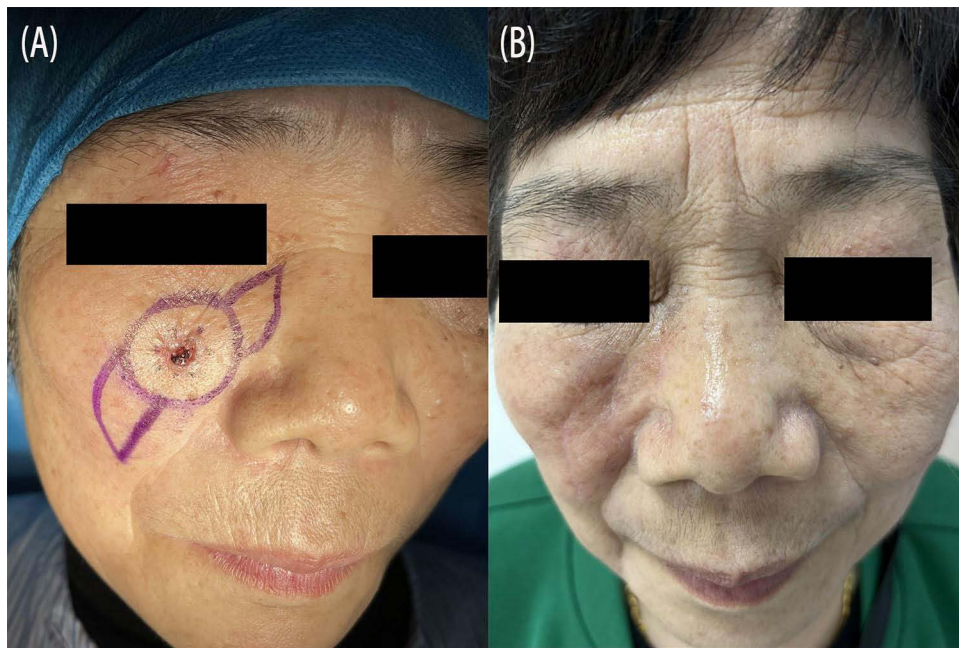
Before surgery, repeatedly tug the patient's skin lesion and surrounding normal skin tissue with fingers to gauge the tension that will remain after the skin lesion is completely removed, and simulate the post-surgical state, while taking into account the patient's subjective feelings. We start by ensuring that the width of the flap limbs is broader. Then, the width of the flap should then be estimated at its broadest point, so that the width of the flap is slightly higher than half of the diameter of the resection range, achieving a ratio of 0.6 to 0.7 times. Determine the length of the flap by measuring the distance between its point a and point c, as well as its point e and point f, and cause the length of the flaps on both sides (ie the sum of the two) to reach a ratio of 1.5 to 1.8 times the diameter of the resection range.

The skin was sliced along the flap design line. The first was separated from the curved line (points a to b and d to f) tissue to the superficial fascial layer. There was a wedge-shaped incision that gradually extended to the pedicle, nearing two-thirds of the flap. It was then separated from the midline (points a to c and e to f). Full loosening of the subcutaneous tissue increased the rotational mobility of the flaps. The limbs (points b and d) were broader. When the flaps were sutured, the limbs were retained with a certain degree of stretching as needed. Comparatively, to traditional V-Y flaps, the flap limbs (points b and d) have a greater curvature of convex lines. This technique retained and exploited the limbs of the flaps, which were often removed using the traditional V-Y flaps. After adequate freeing of the flaps, bilateral flaps were not only advanced along the midline but also rotated and slid with the tips of the flaps close to the midline (points c and e) as the axis (Figure 2E). At the 3-month follow-up, the patient showed excellent cosmetic and functional results (Figure 2F).

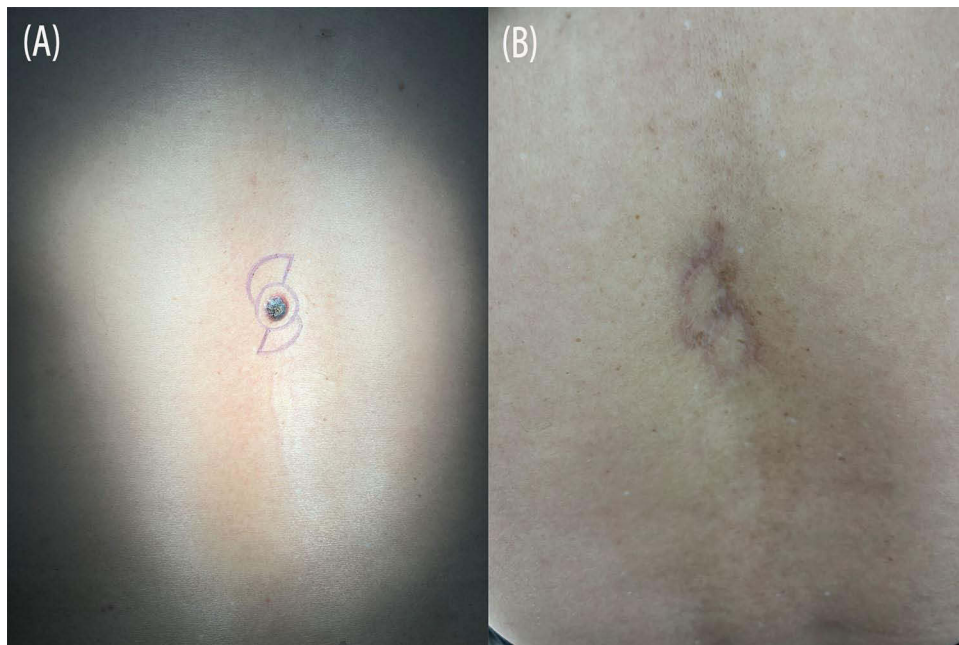
## Results and Discussion

Using modified kite flaps, all eleven patients achieved satisfactory postoperative results. A follow-up period of three months or longer was conducted. There were no perioperative complications, and major anatomic landmarks were reconstructed. All patients were satisfied and had excellent functional recovery. The effective repair by this technique was achieved and the scars were inconspicuous and acceptable. The outcomes of cosmetic and functional evaluations were good treatment results in patients (Figures 3 and 4).

Reconstructive surgery to repair defects in high-tension areas is challenging. A series of skin grafts and flap procedures for resurfacing surgical defects have been described. Large wounds can be repaired with free flaps and pedicled flaps, especially when local tissue is insufficient. Pedicled flaps for multilayer reconstruction was the solution to cover very large and complex defects.<sup>8</sup> Free flaps are suitable for large deep wounds with extensive bone exposure. It should be noted that its thickness will bury the tumor, and it requires a prolonged operation under general anesthesia. A study with pedicled flaps versus free flaps for back reconstruction demonstrated that the operation time with pedicled flaps required is significantly lower.<sup>9</sup> In full-thickness skin grafting, defects can be surgically repaired, but it requires skin from the donor site, whose color and texture do not match the surrounding skin. In specific areas, such as the plantar area, the flap procedure has the advantage of withstanding friction and pressure much better than full-thickness skin grafting.



**Figure 3** A 71-year-old woman had basal cell carcinoma on her nasofacial with a 2-year history. A biopsy was obtained from the skin lesion and confirmed the diagnosis. **(A)** Preoperative view of the patient. **(B)** Postoperative view 5 months after surgery.



**Figure 4** A 63-year-old man had basal cell carcinoma on the midline of the lower back with a 10-year history. A biopsy was obtained from the skin lesion and confirmed the diagnosis. **(A)** Preoperative view of the patient. **(B)** Postoperative view 3 months after surgery.

For instance, two long arc incisions will be made in the clockwise or counterclockwise directions to form an O–Z bilateral rotation flap. However, when the defect to be repaired is too large or under high tension, the rotation flap’s pivot point is overly tight, thereby limiting flap movement. Further flap movement requires larger flaps, and the corresponding flap preparation requires a larger donor area and longer incision. Additionally, this results in a longer operative time and a higher risk of surgical bleeding and complications.

Under significantly elevated defect closure tension, the flap may experience tip ischemia and necrosis. A V-Y flap has been proposed to overcome this pitfall to some extent due to the retained vascular pedicles of the island pedicle flap. The traditionally designed V-Y flap also requires a large donor area for a complete reconstruction, especially double-reverse V-Y flaps. There should be a slight difference between the width of the traditional V-Y advancement flap and the width of the primary surgical defect during the surgery, often, the length should be more than two times as long as the primary surgical defect's width. To reduce dog ear deformity, the limbs of traditional V-Y advancement flaps are often removed, and healthy tissue needs to be sacrificed. In the case of high-tension tissue defects requiring skin tissue repair, removal of the limbs of the double V-Y flap is a waste. In contrast, with the combination of advancement and rotation, our method preserves the limbs of the flaps and the defect of bilateral flaps closes with significantly reduced tension. In addition, the skin extensibility of the flap tip can be fully exerted during suturing.

There are diverse benefits to using our method to close high-tension tissue defects. First, the double flaps not only advance but also rotate. Therefore, the flap is required to slide a significantly shorter distance and move more flexibly. The tension of the closing process is distinctly reduced compared with that of the traditional method. Moreover, the size of the flap to be prepared using this approach is approximately half that of traditional V-Y flaps, with less sacrifice of the healthy tissue. After this, the traditional method often requires the removal of a distal portion of the limbs of the flap.<sup>10</sup> Using this technique, the skin is more extensible at the tip of a rotational flap, removal of the distal portion is rarely necessary, and shorter operational periods. With a significantly smaller donor area than traditional double V-Y flaps, the technique minimizes both the amount of surgical effort needed to carry out the flap as well as tension on the edges of the flap after it has been placed.

Based on our experience, the width of the flaps and the length of the flaps can be modified in accordance with the correction of flap rotation. A small increase in flap width may cause the length to decrease proportionately. This little modification feature makes the skin flap design more adaptable to various circumstances and defects in various areas. This requires more research and investigations in the future.

Depending on the use and site, other different modifications of the V-Y flap have emerged, such as the biplanar-pivoted V-Y flap, the bipedicle V-Y "cup" flap, and the modified unilateral pedicled V-Y advancement flap. With its biplanar pivot and extended mobility, the biplanar-pivot V-Y flap offers excellent coverage of defects in the medial canthal region.<sup>11</sup> The reconstruction of constricted ears using preauricular flap advancement combined with bilateral cartilage flaps made use of its deformed tissue and surrounding skin.<sup>12</sup> In our study, we believe modified kite flaps are a useful surgical procedure for the reconstruction of high-tension tissue defects.

## Conclusion

In conclusion, the modified technique enables a significantly shortened advancement distance and more flexibility of the flaps. The sacrifice of healthy tissue is minimal, and this technique significantly relieves tension on the closure line. Modified kite flaps are a suitable option for the repair of defects in areas with high tension and have a high potential.

## Ethical Approval

All procedures were performed in compliance with relevant laws and institutional guidelines and the technique was approved by the ethical committee of Wenzhou Hospital of Integrated Traditional Chinese and Western Medicine (2023008).

## Informed Consent

Written informed consent was obtained from the patient for publishing all photographic materials and case details.

## Disclosure

The author reports no conflicts of interest in this work.

## References

1. Altun S, Çakır F, Öztan M, Okur M, Bal A. Do rhomboid flaps provide more elongation than Z-plasty flaps? An experimental study. *J Plast Surg Hand Surg.* 2018;52(3):148–152. doi:10.1080/2000656X.2017.1372287
2. Aithal SS, Loganathan E, Shekar R. Keystone island flap for reconstructive surgery-A novel approach. *J Cutan Aesthet Surg.* 2022;15(3):315–318. doi:10.4103/JCAS.JCAS\_167\_21
3. Lo Torto F, Frattaroli JM, Kaciulyte J, et al. The keystone flap: a multi-centric experience in elderly patients treatment. *J Plast Reconstr Aesthet Surg.* 2022;75(1):226–239. doi:10.1016/j.bjps.2021.08.043
4. Donovan LC, Douglas CD, Van Helden D. Wound tension and ‘closability’ with keystone flaps, V-Y flaps and primary closure: a study in fresh-frozen cadavers. *ANZ J Surg.* 2018;88(5):486–490. doi:10.1111/ans.14163
5. Skaria AM. Birhombic flap, a modified bilobed flap, for repair of nasal defect. *J Eur Acad Dermatol Venereol.* 2013;27(3):e357–e362. doi:10.1111/j.1468-3083.2012.04688.x
6. Rapstine ED, Knaus WJ, Thornton JF. Simplifying cheek reconstruction: a review of over 400 cases. *Plast Reconstr Surg.* 2012;129(6):1291–1299. doi:10.1097/PRS.0b013e31824ecac7
7. Wu Y, Peng J, Luo X, Wang T. The application of modified kite flap in repairing facial skin defects after tumor resection. *Ann Plast Surg.* 2022;88(1):59–62. doi:10.1097/SAP.0000000000003008
8. Scaglioni MF, Meroni M, Fuchs B. Combination of four pedicled flaps for multilayer reconstruction of massive pelvic defect: a case report. *Microsurgery.* 2023;43(8):842–846. doi:10.1002/micr.31051
9. Komagoe S, Watanabe T, Komatsu S, Kimata Y. Pedicled flaps versus free flaps for back reconstruction. *Ann Plast Surg.* 2018;81(6):702–707. doi:10.1097/SAP.0000000000001590
10. Oh SH, Kwon H, Kim SJ, et al. Bilateral interdigitated Pacman flap for round and oval facial defects. *J Craniomaxillofac Surg.* 2018;46(6):1032–1036. doi:10.1016/j.jcms.2018.04.012
11. Karthik N, Hwang CJ, Perry JD. Biplanar-pivoted V-Y flap for reconstruction of medial canthal defects. *Ophthalmic Plast Reconstr Surg.* 2022;38(6):583–587. doi:10.1097/IOP.0000000000002215
12. Zhu J, Xiao Y, Sun M, Wang Y, Lü C, Xue C. Reconstruction of constricted ears by combing bilateral cartilage flaps bridging with V-Y advancement flap. *J Plast Reconstr Aesthet Surg.* 2023;77:162–166. doi:10.1016/j.bjps.2022.11.052

Clinical, Cosmetic and Investigational Dermatology

Dovepress

**Publish your work in this journal**

Clinical, Cosmetic and Investigational Dermatology is an international, peer-reviewed, open access, online journal that focuses on the latest clinical and experimental research in all aspects of skin disease and cosmetic interventions. This journal is indexed on CAS. The manuscript management system is completely online and includes a very quick and fair peer-review system, which is all easy to use. Visit <http://www.dovepress.com/testimonials.php> to read real quotes from published authors.

Submit your manuscript here: <https://www.dovepress.com/clinical-cosmetic-and-investigational-dermatology-journal>