

Internal carotid artery dissection following self-manipulation: A case report

SAGE Open Medical Case Reports
Volume 10: 1–5
© The Author(s) 2022
Article reuse guidelines:
sagepub.com/journals-permissions
DOI: 10.1177/2050313X221122451
journals.sagepub.com/home/sco



Kurt Piening, Nicholas M Piening  and Andy Chiou

Abstract

Arterial dissections are a common cause of stroke in young patients. Dissection occurs when the structure of the arterial wall is compromised, allowing blood to collect between layers as an intramural hematoma. Symptoms of cervical artery dissection may include pain, Horner syndrome, cranial and cervical neuropathies, and pulsatile tinnitus. Treatment varies depending on the severity of symptoms but generally includes anticoagulation with surgical therapy reserved for patients with progressive neurologic symptoms or symptom recurrence while on maximum medical therapy. Here, we present the case of a traumatic internal carotid artery dissection with significant narrowing of the artery in a healthy 26-year-old female after self-manipulation of the neck. She developed Horner syndrome secondary to her dissection. Our patient was initially treated with anticoagulation and transitioned to clopidogrel and atorvastatin for outpatient treatment. Six-month follow-up computed tomography angiography showed complete resolution of her dissection. She had overall significant improvement in her symptoms with only mild residual ptosis on the follow-up examination. While the presentation of a patient with neurologic sequelae from a cervical artery dissection causing stroke is a well-known phenomenon, the mechanical cause in this particular case is rare. There have been several case reports in the literature detailing cervical artery dissections following cervical manipulative therapy by trained professionals (i.e. chiropractors, physical therapists, osteopathic physicians) but none occurring from self-manipulation of the neck. This case report details successful treatment of a rare case of internal carotid dissection following self-manipulation with appropriate medical therapy.

Keywords

Surgery, cardiovascular

Date received: 29 April 2022; accepted: 9 August 2022

Introduction

Arterial dissections are a cause of stroke in young patients. Dissection occurs when the structural integrity of the arterial wall is compromised, allowing blood to collect between layers as an intramural hematoma. Hemorrhage may result from an intimal tear or rupture within the vasa vasorum.^{1,2} Subintimal dissections can cause luminal stenosis or occlusion, in contrast to subadventitial dissections that mainly result in dissecting aneurysm formation.³

Dissections can occur spontaneously or from trauma. A “traumatic” dissection may be caused by neck or head movement; this could be something as trivial as bouts of coughing/sneezing or sudden deceleration. It could also be a much more significant trauma, such as a motor vehicle accident or a non-penetrating injury to the head or neck.⁴ When associated with trauma, there is compression and stretching of the carotid artery against the cervical vertebrae leading to intimal tearing. The incidence has been quoted between 0.08%

and 3.7% over the past several decades and appears relatively stable with 4% of the dissections related to severe trauma affecting younger patients (~40 years old).^{5,6}

Ischemic symptoms manifest in the following ways: intramural hematoma expansion causing hemodynamically significant narrowing or complete occlusion and subintimal thrombogenic factors leak into the bloodstream and subsequent thrombus formation. Symptoms of cervical or cerebral artery dissection (CeAD) can include pain, Horner syndrome, cranial and cervical neuropathies, and pulsatile tinnitus. Management varies depending on the severity of the symptoms but will typically include antithrombotics with

Department of Surgery, The University of Illinois College of Medicine Peoria, Peoria, IL, USA

Corresponding Author:

Nicholas M Piening, Department of Surgery, The University of Illinois College of Medicine Peoria, Peoria, IL, USA.
Email: nmpiening@gmail.com



Creative Commons Non Commercial CC BY-NC: This article is distributed under the terms of the Creative Commons Attribution-NonCommercial 4.0 License (<https://creativecommons.org/licenses/by-nc/4.0/>) which permits non-commercial use, reproduction and distribution of the work without further permission provided the original work is attributed as specified on the SAGE and Open Access pages (<https://us.sagepub.com/en-us/nam/open-access-at-sage>).

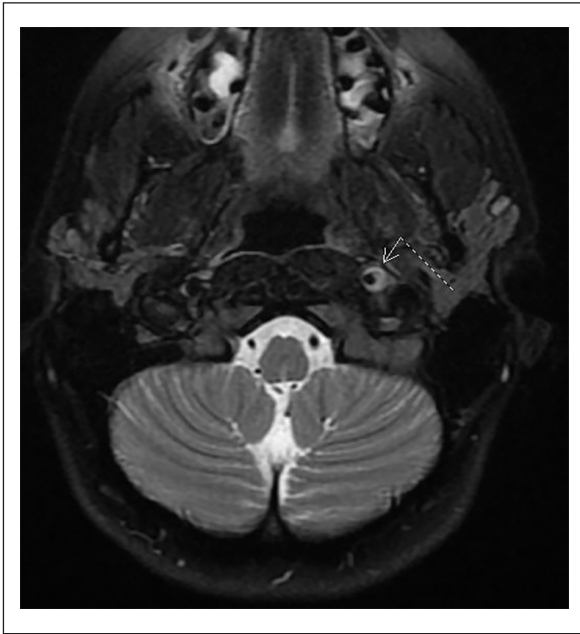

Image 1. MRI showing partially circumferential dissection-related thrombus within the left cervical internal carotid artery near the skull base.

endovascular therapy reserved for patients with progressive neurologic symptoms or symptom recurrence while on maximum medical therapy. Intravenous thrombolysis has also been reported as safe for treatment of cervical artery dissection (CAD). Endovascular interventions include mechanical thrombectomy or emergency stenting. We describe a patient with traumatic dissection of her internal carotid artery (ICA) secondary to self-manipulation causing the neurologic sequelae of Horner syndrome.

Case presentation

This is a case of a healthy 26-year-old female with no past medical history or prior history of neck pain who does not take any medications who presented to the Emergency Department (ED) for evaluation following identification of abnormalities on magnetic resonance imaging (MRI)/magnetic resonance angiography (MRA) of the head and neck as well as computed tomography angiography (CTA) of the head and neck.

Four days prior to admission, our patient was exercising. In between her exercises, she recalls cracking her neck using a combination of extension side bend and rotation. The following day, our patient noted some droop of her left eyelid and her left pupil was smaller and less reactive than her right. She was evaluated by Ophthalmology as an outpatient and referred for MRI of the brain and MRA of the head and neck which discovered a partially circumferential dissection-related thrombus within the left ICA near the skull base that resulted in mild degree of luminal narrowing of the left

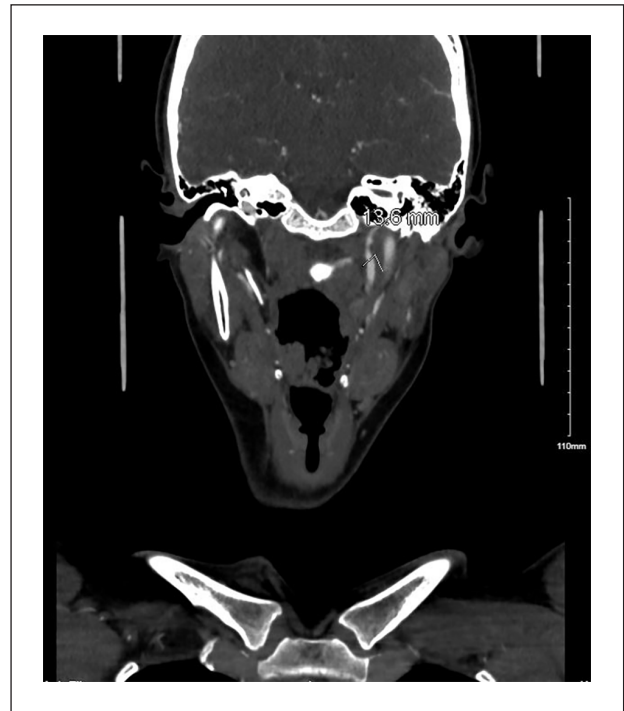


Image 2. CTA showing 50% narrowing over a 14-mm length in the left ICA representing an area of dissection.

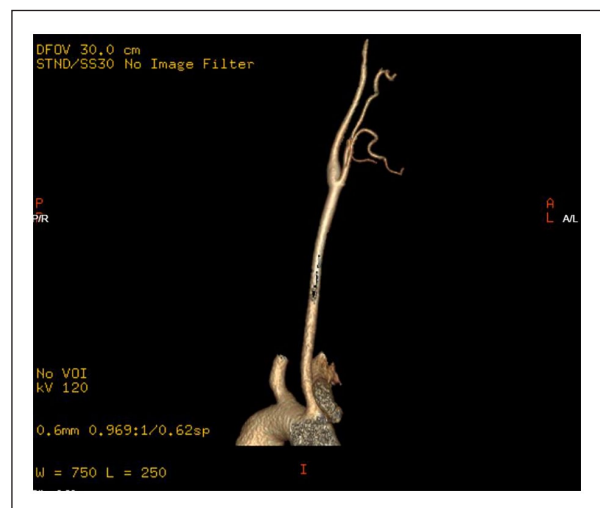


Image 3. Three-dimensional reconstruction of the patient's left ICA, demonstrating a dissection.

cervical internal carotid near the skull base without vessel occlusion or significant vessel narrowing (Image 1).

A CTA was then performed for further evaluation due to concern for progression of disease with findings of a distal 14mm of the left-sided cervical carotid showing irregularity of the lumen and approximately a 50% narrowing over a 14-mm length that may represent an area of dissection (Images 2 and 3). No false lumen or intimal flap was demonstrated;

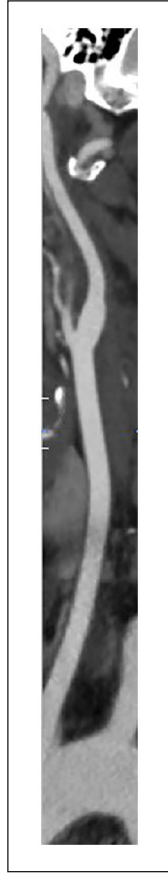

Image 4. Follow-up CTA demonstrating resolution of the dissection.

however, there was likely stretching and hypoperfusion of the sympathetic fibers within the carotid wall.⁷

On admission, our patient complained of a mild “aching” behind her left eye. She denied symptoms of headaches, neck pain, neck stiffness, extremity paresthesias, anesthetics, or focal motor deficits. The patient has no history of diabetes or hypertension. She is a lifelong non-smoker.

The patient was admitted and placed acutely on a heparin drip in case any intervention was to be required. The patient was discharged on atorvastatin and clopidogrel per Neurology preference. A 6-month follow-up CTA and carotid duplex were performed showing no evidence of carotid or vertebral artery (VA) dissection (Image 4). The left ICA now has a normal appearance and is fully reconstituted. She now only complains of mild eyelid droop that worsens with fatigue.

Discussion

The incidence of carotid artery dissection is 2.5–3/100,000 per year.⁸ Carotid artery dissection accounts for 2% of ischemic strokes. In the younger population, carotid artery dissection is responsible for up to 20% of strokes.⁹ Cervical manipulative therapy (CMT) has been associated with

carotid artery dissection with an incidence stated between 1 in 20,000 and 1 in a million spinal manipulations causing a severe adverse event.¹⁰ The mechanism for injury is with extension and lateral flexion of the head, and the ICA can become fixed in place, abutting the upper cervical vertebrae allowing for potential injury.¹¹ While a number of case–control studies suggest that manipulations of the neck and cervical spine are associated with carotid artery dissections, there have been additional case-crossover studies that found no excess risk of stroke following chiropractic care.¹² However, without prospective cohort or randomized studies, the current literature suggests carotid artery dissections are a rare but serious complication of cervical manipulations.¹³ In fact, dissections originally thought to be associated with CMT are more predominant in the VA. In an extensive literature review performed by Haneline et al.¹⁴ considering studies reporting CMT-related CADs which distinguished between the occurrence of dissection in ICA compared to VA, 34 cases, 8 (24%) involving the ICA and 26 (76%) the VA, were found. Arterial dissections resulting from manipulation have historically been reported to be associated with connective tissue disorders, although this seems to have been unsubstantiated in the more current literature.^{15–17} According to the largest series of patients with CeAD, Debette et al. found that a family history of CeAD was very rare and was associated with carotid location and elevated cholesterol levels. Of the 2000 patients with CeAD included in the series, a history of connective tissue disorders was found to be rare and occurred in patients without a family history of CeAD (2 Vascular Ehlers-Danlos Syndrome (vEDS), 1 Marfan syndrome, 1 classic Ehlers-Danlos Syndrome (EDS), 1 hypermobile EDS, 1 osteogenesis imperfecta).¹⁸ The clinical presentation and prognosis of strokes due to carotid artery dissection are influenced by several factors including the severity of stenosis, site of dissection, and amount of collateral circulation. Up to 80% of patients will develop focal neurological deficit within 1 month of dissection.¹⁵ While the presentation of a patient with neurologic sequelae from a CAD causing stroke is a well-known phenomenon, the mechanical cause in this particular case is rare. As previously discussed, there have been several reports in the literature detailing ICA dissection following CMT by providers trained in manipulation techniques. According to a retrospective study performed by Plachinski et al., CMT-associated CeADs were uncommon and only a small fraction of the cases were identified at their institution. Similar to our patient, CeADs were more often vertebral and occurred in patients who were generally younger, without an extensive active smoking history. In addition, CMT-associated CeAD outcomes did not differ from spontaneous CeADs.¹⁹ In rebuke, Bowler et al. evaluated the effect of CMT on blood flow in the ICA and VAs, and no evidence that blood flow in this group is adversely affected by placing the cervical spine in a manipulation position was found. However, this is a study sample of

healthy, asymptomatic individuals without the presence of symptoms requiring manipulation therapy, and therefore, it is not possible to generalize the results to a symptomatic population.²⁰

The typical patient with an ICA dissection presents with pain, partial Horner syndrome, and cerebral or retinal ischemia. This classic triad is found in less than one-third of patients with carotid artery dissections.^{21,22} Horner syndrome is a well-documented manifestation of internal carotid artery dissection (ICAD), but it is observed in less than half of the patients.^{21,22} Facial anhidrosis is absent because the sympathetic plexus that innervates the facial sweat glands surrounds the external carotid artery.^{13,22} In addition, the lower cranial nerves can also be affected, particularly the hypoglossal nerve followed by cranial nerves IX, X, XI, and V.²² This may be due to hypoperfusion of vasa nervorum or by direct compression of the cranial nerve by mural hematoma in close proximity to the nerve itself. There is little to be performed in the way of preventive interventions other than reduction of risk factors such as hypertension, smoking, and oral contraceptive pill (OCP) use. However, some literature does suggest that aggressive screening for traumatic blunt carotid and vertebral injuries is warranted and may even result in cost reduction due to decreased costs of long-term disability. In regard to systematic screening for mutations leading to connective tissue diseases in patients with CeAD, Debette et al. do not believe it is clinically justified for monosymptomatic cases due to rarity.^{18,23} It, however, should be encouraged for any provider evaluating a patient with neck pain to perform a thorough physical examination to detect subtle findings such as ptosis or anisocoria.

Conclusion

In conclusion, ICA dissection can present with pain, partial Horner syndrome, and cerebral or retinal ischemia. This case report details successful treatment of a rare case of internal carotid dissection following self manipulation. ICA dissection does not typically present with this mechanism of injury, so patients with neck trauma should be judiciously screened for vascular injury. In addition, patients with traumatic ICA dissection from cervical manipulation are found to be associated with connective tissue disorders, and thus patients should be screened appropriately. Finally, we encourage any provider evaluating a patient with neck pain or headaches to perform a thorough physical examination to assess any subtle findings that may indicate an evolving neurologic condition like an ICA dissection.

Acknowledgements

We would like to thank Dr Chiou for his support and assistance in the preparation and finalization of this manuscript. My co-first author Nicholas worked alongside me in literature review, crafting, and finalization of this manuscript and submission.

Declaration of conflicting interests

The author(s) declared no potential conflicts of interest with respect to the research, authorship, and/or publication of this article.

Ethics approval

Our institution does not require ethical approval for reporting individual cases or case series.


Funding

The author(s) received no financial support for the research, authorship, and/or publication of this article.

Informed consent

Written informed consent was obtained from the patient(s) for their anonymized information to be published in this article.

ORCID iD

Nicholas M Piening  <https://orcid.org/0000-0003-1415-4038>

References

1. Pannone A, Lucchetti G, Stazi G, et al. Internal carotid artery dissection in a patient with Behçet's syndrome. *Ann Vasc Surg* 1998; 12(5): 463–467.
2. Volker W, Dittrich R, Grewe S, et al. The outer arterial wall layers are primarily affected in spontaneous cervical artery dissection. *Neurology* 2011; 76: 1463–1471.
3. Citardi M and Batra P. Imaging of the internal carotid artery and adjacent skull base with three-dimensional CT angiography for preoperative planning and intraoperative surgical navigation. *Skull Base* 2007; 16: A109.
4. Mohan IV. Current optimal assessment and management of carotid and vertebral spontaneous and traumatic dissection. *Angiology* 2014; 65(4): 274–283.
5. Lleva P, Ahluwalia BS, Marks S, et al. Traumatic and spontaneous carotid and vertebral artery dissection in a level 1 trauma center. *J Clin Neurosci* 2012; 19(8): 1112–1114.
6. Thanvi B, Munshi SK, Dawson SL, et al. Carotid and vertebral artery dissection syndromes. *Postgrad Med J* 2005; 81(956): 383–388.
7. Alonso Formento JE, Fernández Reyes JL, Envid Lázaro BM, et al. Horner's syndrome due to a spontaneous internal carotid artery dissection after deep sea scuba diving. *Case Rep Neurol Med* 2016; 2016: 5162869.
8. Schievink WI, Mokri B and Whisnant JP. Internal carotid artery dissection in a community. Rochester, Minnesota, 1987–1992. *Stroke* 1993; 24(11): 1678–1680.
9. Schievink WI, Mokri B and Michael O'Fallon W. Recurrent spontaneous cervical-artery dissection. *N Engl J Med* 1994; 330: 393–397.
10. Vickers A and Zollman C. ABC of complementary medicine. The manipulative therapies: osteopathy and chiropractic. *BMJ* 1999; 319(7218): 1176–1179.
11. Haneline MT, Croft AC and Frishberg BM. Association of internal carotid artery dissection and chiropractic manipulation. *Neurologist* 2003; 9(1): 35–44.

12. Cassidy JD, Boyle E, Côté P, et al. Risk of carotid stroke after chiropractic care: a population-based case-crossover study. *J Stroke Cerebrovasc Dis* 2017; 26(4): 842–850.
13. Biller J, Sacco RL, Albuquerque FC, et al. Cervical arterial dissections and association with cervical manipulative therapy: a statement for healthcare professionals from the American Heart Association/American Stroke Association. *Stroke* 2014; 45(10): 3155–3174.
14. Haneline MT and Lewkovich GN. An analysis of the etiology of cervical artery dissections: 1994 to 2003. *J Manipulative Physiol Ther* 2005; 28(8): 617–622.
15. Schievink WI. Spontaneous dissection of the carotid and vertebral arteries. *N Engl J Med* 2001; 344: 898–906.
16. Schievink WI, Wijdicks EF, Michels VV, et al. Heritable connective tissue disorders in cervical artery dissections: a prospective study. *Neurology* 1998; 50(4): 1166–1169.
17. Grond-Ginsbach C and Debette S. The association of connective tissue disorders with cervical artery dissections. *Curr Mol Med* 2009; 9(2): 210–214.
18. Familial occurrence and heritable connective tissue disorders in cervical artery dissection. *Neurology* 2016; 87(23): 2500.
19. Plachinski SJ, Gliedt JA, Sacho R, et al. Spinal manipulative therapy and cervical artery dissection: a retrospective comparison with spontaneous, traumatic, and iatrogenic etiologies at a single academic medical center. *Clin Neurol Neurosurg* 2021; 209: 106941.
20. Bowler N, Shamley D and Davies R. The effect of a simulated manipulation position on internal carotid and vertebral artery blood flow in healthy individuals. *Man Ther* 2011; 16(1): 87–93.
21. Biousse V, D'Anglejan-Chatillon J, Massiou H, et al. Head pain in non-traumatic carotid artery dissection: a series of 65 patients. *Cephalalgia* 1994; 14(1): 33–36.
22. Silbert PL, Mokri B and Schievink WI. Headache and neck pain in spontaneous internal carotid and vertebral artery dissections. *Neurology* 1995; 45(8): 1517–1522.
23. Debette S and Germain DP. Neurologic manifestations of inherited disorders of connective tissue. *Handb Clin Neurol* 2014; 119: 565–576.