

# Characterization of the parasite-induced lesions in the posterior segment of the eye

Nagwa Mostafa El-Sayed, Elmeya Hassan Safar

Ocular lesions are frequently associated with different parasitic infections. The classes of infection include protozoa, nematodes, cestodes, and ectoparasites. Ocular parasitic infections can manifest in any part of the eye; the disease manifestations are frequently characterized as either posterior or anterior eye disease. Parasite-induced lesions may be due to damage directly caused by the parasite, indirect pathology caused by toxic products or the immune response initiated by infectious parasitism. This review characterized the parasite-induced lesions in the posterior segment of the eye. Prompt diagnosis and early treatment of these lesions can reduce ocular morbidity. The method of the literature search was conducted on PubMed, Elsevier Scopus database, and Google Scholar with no limitation on the year of publication databases. It was limited to English articles published for ocular lesions in clinical studies and was focused on parasitic infections of the eye.

**Key words:** Ocular lesions, parasitic infections, posterior segment

Ocular lesions caused by different parasites in human are more prevalent in geographical areas where environmental factors and poor sanitary conditions favor the parasitism between man and animals. Dietary history, travel history to endemic areas, clinical features of inflammatory eye diseases, and advances of diagnosis are important to determine the source of infection.<sup>[1]</sup> Parasitic organisms can infect the eye either by direct introduction through trauma or surgery, by extension from infected adjacent tissues, or by hematogenous dissemination to the eye.<sup>[2]</sup>

Ophthalmic manifestations of parasitic infections may involve either the anterior or posterior segment of the eye. Posterior segment involvement includes choroiditis, retinichoroiditis, retinal vasculitis, retinal hemorrhage, central retinal vein thrombosis, papilledema, retinal detachment, orbital cysts and optic atrophy that lead to permanent retinal damage and visual loss.<sup>[3-5]</sup> Establishing the diagnosis of parasitic infections of the eye is accomplished by a combination of the clinical history, clinical examination, and accurate identification of the causative organism. A combination of antiparasitic drugs and surgery is the usual therapeutic approach to most parasitic eye infections.

## Protozoa Involving the Posterior Segment of the Eye

### Toxoplasmosis

Toxoplasmosis is caused by the protozoan parasite *Toxoplasma gondii*. Infection may be acquired through ingestion

Department of Medical Parasitology, Research Institute of Ophthalmology, Giza, Egypt

**Correspondence to:** Prof. Nagwa Mostafa El-Sayed, Research Institute of Ophthalmology, 2 El-Ahram Street, P.O. Box: 90, Giza, 12556, Egypt. E-mail: nag.elsaka@yahoo.com

Manuscript received: 20.05.15; Revision accepted: 31.10.15

raw infected meat, contaminated vegetables or water, blood transfusion, organ transplantation and congenitally, across the placenta from the mother to the fetus.<sup>[6,7]</sup> *T. gondii* infects up to a third of the world population<sup>[8]</sup> and toxoplasmic retinochoroiditis is the most common cause of posterior uveitis.<sup>[3]</sup>

Toxoplasmic retinochoroiditis occur either immediately or later after the initial infection or in reactivation.<sup>[9,10]</sup> Recurrent attacks of toxoplasmic retinochoroiditis result from rupture of dormant cysts in the retina and release of viable parasites that induce necrosis and inflammation or hypersensitivity reaction to parasite antigen.<sup>[11]</sup> Moreover, it was found that *T. gondii* infection induced DNA damage in retinal cells.<sup>[12]</sup> The intensity of damage to retina and choroid depends on the severity of the infection and the associated inflammatory reaction. Within the retina, lysosomal and other autolytic enzymes released by inflammatory cells predominantly macrophages and lymphocytes are thought to contribute to the pathogenic mechanisms of retinal tissue damage.<sup>[13]</sup>

Clinical diagnosis of toxoplasmic retinochoroiditis is based upon ophthalmoscopic examination. Typical fundus abnormalities present as the grey-white focus of retinal necrosis with adjacent choroiditis, vasculitis, hemorrhage, and vitreitis [Fig. 1].<sup>[14]</sup> Active inflammation lasts about 6 weeks, at which time the lesion begin to regress, leaving behind

### Access this article online

#### Website:

www.ijo.in

#### DOI:

10.4103/0301-4738.176028

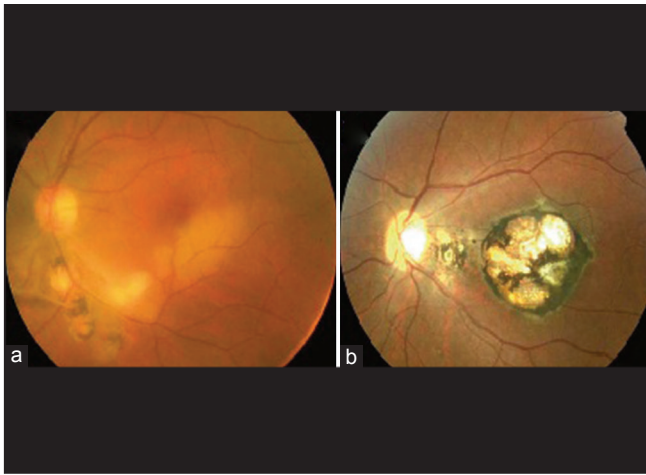
### Quick Response Code:



This is an open access article distributed under the terms of the Creative Commons Attribution-NonCommercial-ShareAlike 3.0 License, which allows others to remix, tweak, and build upon the work non-commercially, as long as the author is credited and the new creations are licensed under the identical terms.

**For reprints contact:** reprints@medknow.com

**Cite this article as:** El-Sayed NM, Safar EH. Characterization of the parasite-induced lesions in the posterior segment of the eye. Indian J Ophthalmol 2015;63:881-7.



**Figure 1:** (a) Fundus photograph of the left eye of a patient with ocular toxoplasmosis shows an active focus of retinochoroiditis adjacent to old pigmented scars inferotemporally and an area of retinal whitening along the inferior temporal arcade consistent with a diagnosis of branch retinal artery occlusion. (b) Fundus photograph shows congenital toxoplasmosis involving the macula

a characteristic macular pigmented scar on the retina.<sup>[15]</sup> However, atypical lesions also occur, including punctate outer retinitis, neuroretinitis, and papillitis and their toxoplasmic origin may be demonstrated by laboratory testing or by a positive response to specific treatment.<sup>[16]</sup>

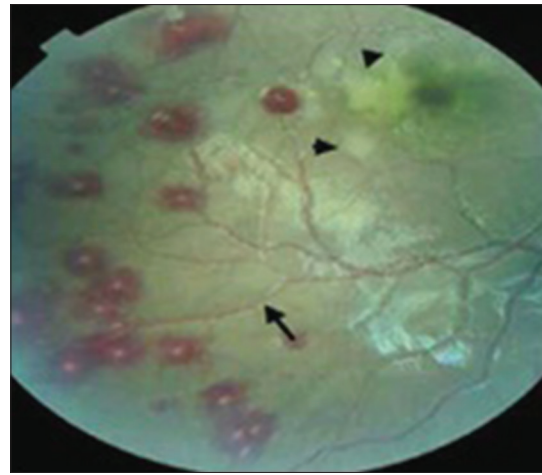
Laboratory diagnosis of toxoplasmosis is based on detection of antibodies and *T. gondii* DNA using polymerase chain reaction (PCR) that support clinical findings.<sup>[17]</sup> The combination of pyrimethamine and sulfadiazine remains the mainstay for treatment and prophylaxis of toxoplasmosis.<sup>[18]</sup>

### Malaria

Malaria is a mosquito-borne infectious disease caused by intraerythrocytic protozoa of the genus *Plasmodium*. Ocular manifestations associated with malaria were recorded by several investigators.<sup>[4,19]</sup> Malarial retinopathy consists of four main components: Retinal whitening; vessel discoloration of retinal vessels to orange or white; hemorrhages; and papilledema [Fig. 2].<sup>[20]</sup> Cotton wool spots are also seen and are distinct from retinal whitening. The vessel changes and pattern of retinal whitening appear to be unique to this disease.<sup>[4]</sup> The central mechanism causing malarial retinopathy appears to be a microvascular obstruction that strongly supports the sequestration of erythrocytes in small blood vessels.<sup>[21]</sup> Other eye-related findings include amaurosis fugax, optic neuritis, glaucoma, panuveitis, oculomotor paralysis, and cortical blindness. It is held that retinal hemorrhage is a poor prognostic indicator in cerebral malaria.

The pathogenesis of disease with respect to malaria can generally be traced to problems related to the physical effects of the parasite (microvascular obstruction and hemolysis) and the direct metabolic effects of the parasite (tissue hypoxia and hypoglycemia). In addition, retinal hemorrhage is thought to be a consequence of anemia.<sup>[22]</sup>

Papilledema and retinal hemorrhages can be visualized with an ordinary direct ophthalmoscope while the retinal whitening and vessel abnormalities that are found in the peripheral retina



**Figure 2:** Retinal features of cerebral malaria, revealing multiple white centered hemorrhages, macular whitening (indicated by black triangles) and orange discoloration of vessels (indicated by the black arrow)

require indirect ophthalmoscopy.<sup>[4]</sup> The definitive diagnosis of malaria is made by microscopic identification of the parasite in the blood smear. Several methods can be used alternatively including serological immunoassays, antigen-based rapid diagnostic tests, and molecular amplification methods.<sup>[23-25]</sup> Treatment of ocular manifestations relies on treating the systemic infection.

### Visceral leishmaniasis

Leishmaniasis is a tropical infection caused by the protozoan, belonging to the group of *Leishmania* that causes Old World and New World disease. These are typically divided into the cutaneous, mucocutaneous, visceral, viscerotropic, and disseminated disease. Visceral leishmaniasis or kala - azar is a systemic disease caused by *Leishmania donovani* parasite. The concurrent presence of visceral leishmaniasis with ocular involvement has been reported.<sup>[26]</sup>

Ocular leishmaniasis is a sight-threatening condition that needs to be rapidly recognized and treated to avoid permanent visual loss. It can present with retinochoroiditis, central retinal vein thrombosis, papilledema, and flame-shaped retinal hemorrhages. Retinal changes in visceral leishmaniasis include focal retinal whitening, cotton wool spots, hemorrhages, as well as increased vessel tortuosity.<sup>[5]</sup> There are few case reports of ocular leishmaniasis. In 2003, in Spain, a patient with the sudden visual loss caused by retinal hemorrhage was presented. On a systemic evaluation, he was found to have visceral leishmaniasis and treated with pentavalent antimonials.<sup>[27]</sup>

Retinal changes are observed by retinal photography. Laboratory diagnosis of visceral leishmaniasis is made by direct demonstration of organisms on tissue smears or biopsy, culture on Novy-MacNeal-Nicolle medium, the demonstration of the parasite in splenic or bone marrow aspirate where amastigote can be seen or immunodiagnosis by demonstration of parasite antigen.<sup>[28]</sup> Treatment of choice is pentavalent antimony-containing compounds.<sup>[29]</sup>

### Giardiasis

Giardiasis is the most common waterborne parasitic infection of the human intestine worldwide. The etiological agent,

*Giardia duodenalis* (syn. *Giardia intestinalis*, *Giardia lamblia*), is a flagellated, binucleated protozoan parasite which infects a wide array of mammalian hosts.<sup>[30]</sup> *Giardia* is transmitted through the ingestion of cysts in contaminated food or water, or directly via the fecal/oral route. Giardiasis can present with a broad range of clinical manifestations from asymptomatic to acute or chronic diarrheal disease.

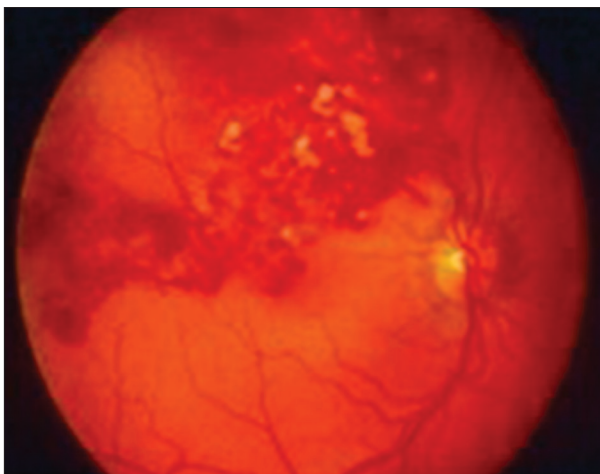
Ocular complications such as iridocyclitis, choroiditis, and retinal hemorrhages have been reported to be associated with giardiasis. Khalifa *et al.*<sup>[31]</sup> described a "salt and pepper" degeneration (punctuate areas of normal hyperpigmentation on a light yellow pink-retina) involving the retinal pigmented epithelium in children suffering from Giardiasis [Fig. 3]. These lesions are thought to be caused by damage to the cells of the retina, accompanied by the release of pigment granules in retinal layers, where they can be seen as blackish dots.<sup>[32]</sup> The possibility of direct invasion by the parasite is not thought to be part of the pathogenesis. It has been suggested that the pigmented degeneration may result from toxic metabolites produced by the parasites.<sup>[33]</sup> Enteric inflammation may lead to uveitis via a triggering agent that crosses intestinal mucosa. Extraintestinal manifestations are considered immunologically mediated, with circulating immune complexes found in patients with ocular involvement.<sup>[34]</sup> Molecular mimicry and human leukocyte antigen-B27 have also been implicated, whereby antigenic cross-reactivity results in antibody production against host cells.<sup>[35]</sup>

Finding of *Giardia* cyst stage in the fecal smear or identification of *Giardia* antigen may help support the diagnosis of ocular giardiasis. However, ocular giardiasis is generally made by exclusion and demonstration of improvement in ocular findings following a course of treatment with anti-giardial agents.<sup>[36]</sup> Metronidazole or albendazole is the treatment of choice.

## Nematodes Infections Involving the Posterior Segment of the Eye

### Toxocariasis

*Toxocara canis* and *Toxocara cati*, which infect dogs and cats respectively, may cause infection in humans with a wide spectrum of clinical symptoms and morbidity. Humans,



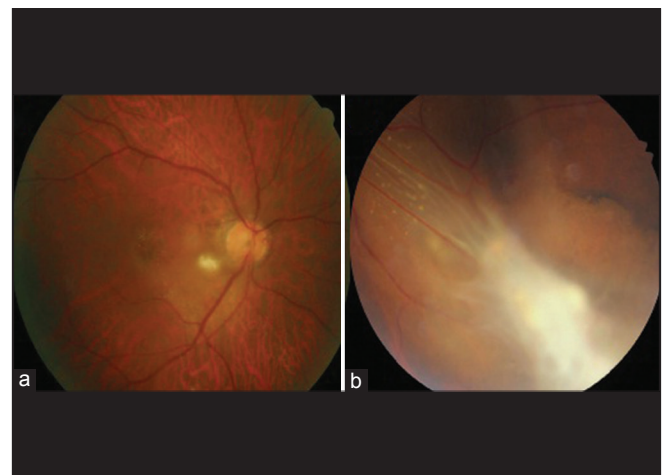
**Figure 3:** Typical salt and pepper appearance of the retina in a child infected with *Giardia lamblia*

typically children, acquire the infection by ingestion of the embryonated eggs usually from contaminated raw vegetables or infected raw meat, and or contaminated water. Dog ownership and pica (geophagia) have been highly associated with *Toxocara* infection.<sup>[37,38]</sup>

Ocular larva migrans is typically caused by migration of *Toxocara* larvae through the choroidal and retinal vessels into the posterior segment of the eye, or occasionally through the optic nerve via the central nervous system.<sup>[39,40]</sup> Ocular toxocariasis is unilateral disease in 90% of patients, which typically presents as retinal granuloma, a yellowish or whitish inflammatory mass in the posterior pole or peripheral retina. Granuloma itself or other comorbid conditions such as an epiretinal membrane, macular edema, and retinal detachment can lead to permanent retinal damage and visual loss [Fig. 4].<sup>[41]</sup>

Diagnosis of ocular toxocariasis depends on a combination of the clinical diagnosis through the identification of typical features by fundoscopy, the finding of specific antibodies in the aqueous humor, and histopathologic identification of dead larvae in the center of eosinophilic granuloma of surgically obtained specimens. The method of choice for routine diagnosis is the enzyme-linked immunosorbent assay (ELISA) using the excretory-secretory antigens of infective larvae of *T. canis*.<sup>[38,42]</sup> Imaging modalities can provide additional information in many patients.<sup>[43]</sup> Optical coherence tomography of posterior granulomas usually demonstrates a highly reflective mass located above retinal pigment epithelium.

Ocular toxocariasis can be treated medically or surgically, depending on the severity of intraocular inflammation and comorbid conditions. Medical therapy with a systemic or topical corticosteroid is effective to reduce intraocular inflammation and may reduce vitreous opacification and membrane formation, but it has limited efficacy to resolve structural complications in the retina. Antihelminthic treatment by albendazole, diethylcarbamazine can also be used, particularly with concomitant extra-ocular toxocariasis symptoms. Surgical removal or laser photocoagulation and



**Figure 4:** Fundus photographs of retinal granuloma in patients with ocular toxocariasis. (a) Posterior pole granuloma appears as an oval, white lesion in the posterior pole of the retina. (b) Peripheral granuloma presents with an amorphous whitish mass with tractional membrane and retinal detachment

cryotherapy can be used to destroy ocular granulomas. The successful surgical outcome was achieved in patients with epiretinal membrane, vitreous opacity, and retinal detachment by providing structural modification, i.e., membrane peeling, removing vitreous opacification, or retinal reattachment that result in stability or improvement in visual function.<sup>[41,42,44]</sup>

### Oncocerciasis

Onchocerciasis, also known as river blindness, is an insect-borne disease, caused by a nematode worm, *Onchocerca volvulus*. It is the second leading infectious cause of blindness. Ocular onchocerciasis is characterized either as posterior or anterior eye disease that correlate with the location of microfilariae. The predominant ocular findings are punctate keratitis, sclerosing keratitis, iridocyclitis, retinichoroiditis, and optic atrophy.<sup>[45]</sup> Retinichoroiditis is due to the presence or migration of microfilariae in these layers of the eye as well as the host's response to the migration. The lesions usually involve both eyes and typically appear as focal areas of depigmentation with atrophy of the retinal pigment epithelium [Fig. 5].<sup>[14]</sup> Subretinal fibrosis may occur in advanced lesions. In addition, peripapillary chorioretinitis can result in optic nerve dysfunction secondary to optic nerve edema and optic neuritis, leading to optic atrophy and eventually blindness.<sup>[46,47]</sup> Induction of posterior ocular onchocerciasis is thought to involve autoimmune responses and cross-reactive proteins. *O. volvulus* protein was found to be cross-reactive with a 44-kDa human retinal protein.<sup>[48,49]</sup>

Slit lamp examination can be used to visualize the ocular findings associated with onchocerciasis. However, typically nematodes are not visualized, and the classic lesions in the setting of an appropriate history and antecedent skin findings can lead to the correct diagnosis. Serology can also be used to detect exposure to *O. volvulus* with high sensitivity and specificity. ELISA and western blot techniques have been used to quantitatively detect antibodies to *O. volvulus* antigens in the skin, tears, and urine. It has shown that a serum antibody test card using recombinant antigens was successfully used to detect *O. volvulus*-specific IgG4.<sup>[50]</sup> A positive IgG4 result indicates active infection. Antigen detection dipstick assays,

PCR, ultrasound of the nodules, and sclerocorneal biopsy have also been suggested to confirm the diagnosis.<sup>[51]</sup>

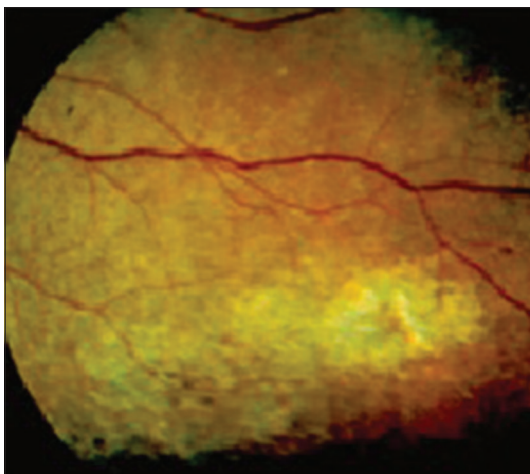
Ivermectin is the most acceptable drug used for mass treatment of onchocerciasis. It has been shown to delay the development of optic atrophy and reduce the visual field loss.<sup>[45,52]</sup> Moreover, chorioretinal lesions may be treated surgically by vitrectomies or laser photocoagulation.

## Cestodes Involving the Posterior Segment of the Eye

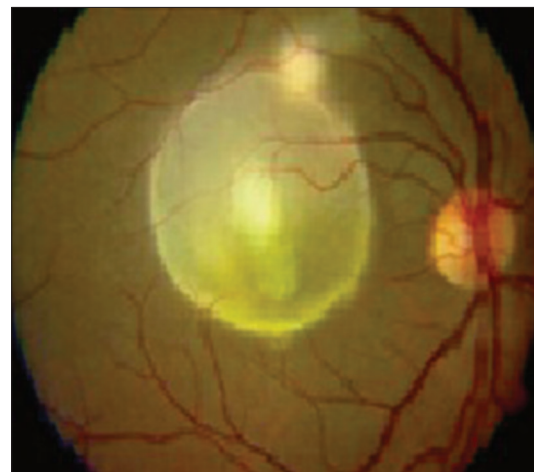
### Ocular cysticercosis

Human cysticercosis is a parasitic infection caused by *Cysticercus cellulosae* larvae of *Taenia solium* (pork tapeworm). It is acquired by ingestion of contaminated food containing ova of *T. solium*. Human cysticercosis mainly affects the central nervous system causing focal neurological deficit and signs of increased intracranial pressure. Ocular involvement is well recognized and includes orbital intraocular, subretinal, and optic nerve lesions.<sup>[53,54]</sup> *Cysticercus* larva found its way to the eye through the posterior ciliary artery and enter the subretinal space at the retina and reach the vitreous humor as a free floating cyst [Fig. 6].<sup>[14]</sup> Intraocular cysticercosis in posterior segment usually presents with reduction of vision, seeing floaters, subretinal cysts, and associated retinal detachment. The cysticercus lesion gradually increases in size, and may lead to blindness. It can even mimic with retinoblastoma.<sup>[55]</sup> When the intact cyst remains viable, it evokes a little or no inflammatory response. Once the cyst ruptures, an antigenic toxic material leaks from the cyst and induces an inflammatory reaction, such as vitritis, uveitis, and sometimes endophthalmitis.

While cysticercosis may be detected by clinical examination, imaging studies may be useful in some situations. In one case report, a B-scan revealed a subretinal subchoroidal cyst with a thick wall containing well defined intracystic echogenic entities representing scolices, and associated retinal detachment.<sup>[56]</sup> In addition, magnetic resonance imaging (MRI) of the orbit<sup>[57]</sup> and supporting investigations such as serology (ELISA, immunoblot) was found to be confirming the suspicion for cysticercosis.



**Figure 5:** Fundus photograph of a patient with onchocerciasis shows peripheral chorioretinal changes with pigment dispersion and focal areas of atrophy



**Figure 6:** Fundus photograph in a patient with cysticercosis shows a live submacular translucent cyst with clear media

Initial medical treatment of intraocular cysticercosis with antihelminthic drugs like albendazole or praziquantel has not proven to be particularly useful. Consequently, surgical removal of the parasite is the treatment of choice.<sup>[58]</sup> The identification is confirmed by histological examination. It is possible to carry out mitochondrial DNA analysis on histopathologic sections.<sup>[59]</sup>

### Ocular hydatid cysts

Hydatid disease is caused by larvae of the dwarf tapeworm of dog (*Echinococcus granulosus*). The oncospheres that hatch from ingested eggs penetrate the intestine and can then be carried, via the portal and systemic circulations, to almost any organ of the body, where they may develop into hydatid cysts.<sup>[60]</sup> Orbital hydatid cysts cause 1–2% of all hydatid lesions.<sup>[61]</sup> Usually, orbital hydatid cysts are located in retrobulbar tissues, either within the muscle cone (up to 60%) or outside in the superolateral or superomedial angles. The orbital hydatid cyst is generally unilateral. Most affected are children and young adults.<sup>[62]</sup> Orbital hydatid cysts usually present in the form of slowly progressing painless unilateral proptosis.<sup>[61]</sup> The most common presenting clinical symptoms and signs are nonpulsatile, nontender proptosis, visual disturbances, disc swelling, diplopia, chemosis, eyelid edema, and conjunctivitis.<sup>[63]</sup> Loss of vision is probably related to optic nerve dysfunction secondary to the pressure effects caused by the large size of the cyst.<sup>[62]</sup>

Diagnosis of orbital hydatid cyst is by computed tomography and MRI. The only definite treatment for orbital hydatid cyst is surgical removal without rupture. Postoperative treatment with albendazole is of great importance if there is spillage intraoperatively to prevent secondary dissemination with local recurrence.<sup>[62]</sup>

### Ocular coenurosis

Coenurosis is caused by infection with *Coenurus cerebralis*, the larval stage of the canine tapeworm *Taenia multiceps* species. Human infection results from accidental ingestion of eggs in contaminated food or water. Eggs hatch, lodge into subcutaneous tissue, eyes or brain, and coenuri develop over approximately 90 days.<sup>[64]</sup> It is suggested that the larvae enter the eye by way of ciliary arteries or direct inoculation to the conjunctiva. *Coenurus* can develop in the vitreous humor and may affect retina and choroid. The degree of damage to vision depends on the size of the coenurus and the extent of choroidoretinal lesions. The ophthalmic findings related to severe optic neuritis and/or early stage neuroretinitis that attributed to direct stimulation during larval migration from capillaries radiating the optic disc, or immune pathological reactions or toxic reaction.<sup>[65]</sup>

The onset of inflammatory responses results in a red and painful eye, followed by the development of glaucoma, retinal fibrosis, and ultimately blindness as the final result of the infection. Diagnosis of ocular coenurosis can only be achieved by surgical removal. The anthelmintic albendazole and corticosteroids are often used to treat ocular lesions.<sup>[66]</sup>

### Internal Ophthalmomyiasis

Ophthalmomyiasis is an ocular invasion by parasitic larvae (maggots) of certain flies in the order *Diptera*.<sup>[67]</sup> It affects humans either directly by laying eggs or depositing

larvae on the conjunctiva or the eyeball, or indirectly, through dirty hands or the bites of infected insects. Internal posterior ophthalmomyiasis is characterized by a different clinical course from asymptomatic ophthalmomyiasis, with accidental discovery to a sudden loss of vision due to severe uveitis and retinal detachment. In the subretinal space, larvae can grow to up to 3–5 mm.<sup>[68]</sup> Subretinal tracks are a recognized manifestation of posterior segment internal ophthalmomyiasis leading to vision abnormalities, which initially prompted the patient to seek medical evaluation. Subretinal tracks are usually unilateral, but bilateral subretinal tracks were also reported.<sup>[69,70]</sup>

Early recognition of this condition, when tumors and other conditions remain suspect, may preclude unnecessary invasive surgical procedures, including enucleation.<sup>[69]</sup> Ophthalmoscopy of the affected eye disclosed characteristic subretinal depigmented linear tracks and a larva within the vitreous. On ultrasound scan, a mobile foreign structure was detected.<sup>[68]</sup> The treatment of choice is laser photocoagulation or vitrectomy with larva removal and intraocular steroids.<sup>[71]</sup>

### Conclusion

Better awareness among optometrists and ophthalmologists could result in earlier diagnosis of ocular lesions induced by the parasitic infection, leading to earlier treatment and prevention of severe vision loss.

### Financial support and sponsorship

Nil.

### Conflicts of interest

There are no conflicts of interest.

### References

1. Nimiri AR, Saliem A, Ibrahim IA. Ophthalmic parasitosis: A review article. *Interdiscip Perspect Infect Dis* 2012;2012:587402.
2. El-Sayed NM, Safar EH, Issa RM. Parasites as a cause of keratitis: Need for increased awareness. *Aperito J Ophthalmol* 2015;1:103.
3. El-Sayed NM, Ismail KA. Role of intracellular adhesion molecules-1 (ICAM-1) in the pathogenesis of toxoplasmic retinochoroiditis. *J Mol Pathophysiol* 2012;1:37-42.
4. Beare NA, Taylor TE, Harding SP, Lewallen S, Molyneux ME. Malarial retinopathy: A newly established diagnostic sign in severe malaria. *Am J Trop Med Hyg* 2006;75:790-7.
5. Maude RJ, Ahmed BU, Rahman AH, Rahman R, Majumder MI, Menezes DB, *et al.* Retinal changes in visceral leishmaniasis by retinal photography. *BMC Infect Dis* 2014;14:527.
6. Yazar S, Eser B, Yay M. Prevalence of anti-*Toxoplasma gondii* antibodies in Turkish blood donors. *Ethiop Med J* 2006;44:257-61.
7. El-Sayed NM. Recent updates in transfusion transmitted parasitic diseases. *Aperito J Bacteriol Virol Parasitol* 2015;2:110.
8. Vallochi AL, Muccioli C, Martins MC, Silveira C, Belfort R Jr., Rizzo LV. The genotype of *Toxoplasma gondii* strains causing ocular toxoplasmosis in humans in Brazil. *Am J Ophthalmol* 2005;139:350-1.
9. Montoya JG, Remington JS. Toxoplasmic chorioretinitis in the setting of acute acquired toxoplasmosis. *Clin Infect Dis* 1996;23:277-82.
10. Vallochi AL, Goldberg AC, Falcai A, Ramasawmy R, Kalil J, Silveira C, *et al.* Molecular markers of susceptibility to ocular toxoplasmosis, host and guest behaving badly. *Clin Ophthalmol* 2008;2:837-48.

11. Commodaro AG, Belfort RN, Rizzo LV, Muccioli C, Silveira C, Burnier MN Jr, *et al.* Ocular toxoplasmosis: An update and review of the literature. *Mem Inst Oswaldo Cruz* 2009;104:345-50.
12. El-Sayed NM, Aly EM. *Toxoplasma gondii* infection can induce retinal DNA damage: An experimental study. *Int J Ophthalmol* 2014;7:431-6.
13. Jabs DA. Ocular toxoplasmosis. *Int Ophthalmol Clin* 1990;30:264-70.
14. Khairallah M, Kahloun R. Infections of the posterior segment: Parasitic and fungal infections. In: Tabbara K, El-Asrar AM, Khairallah M, editors. *Ocular Infections, Essentials in Ophthalmology*. Berlin, Heidelberg: Springer-Verlag; 2014. p. 135-54. DOI 10.1007/978-3-662-43981-4\_12.
15. Smith JR, Cunningham ET Jr. Atypical presentations of ocular toxoplasmosis. *Curr Opin Ophthalmol* 2002;13:387-92.
16. Holland GN. Ocular toxoplasmosis: New directions for clinical investigation. *Ocul Immunol Inflamm* 2000;8:1-7.
17. Antoniazzi E, Guagliano R, Meroni V, Pezzotta S, Bianchi PE. Ocular impairment of toxoplasmosis. *Parassitologia* 2008;50:35-6.
18. El-Sayed NM, Safar EH. A brief insight on anti-*Toxoplasma gondii* activity of some medicinal plants. *Aperito J Bacteriol Virol Parasitol* 2014;1:2.
19. Browning DJ. Patchy ischemic retinal whitening. *Ophthalmology* 2004;111:606-7.
20. White VA, Lewallen S, Beare N, Kayira K, Carr RA, Taylor TE. Correlation of retinal haemorrhages with brain haemorrhages in children dying of cerebral malaria in Malawi. *Trans R Soc Trop Med Hyg* 2001;95:618-21.
21. Maude RJ, Beare NA, Abu Sayeed A, Chang CC, Charunwatthana P, Faiz MA, *et al.* The spectrum of retinopathy in adults with *Plasmodium falciparum* malaria. *Trans R Soc Trop Med Hyg* 2009;103:665-71.
22. Kochar DK, Shubhakaran, Kumawat BL, Thanvi I, Joshi A, Vyas SP. Ophthalmoscopic abnormalities in adults with falciparum malaria. *QJM* 1998;91:845-52.
23. Doderer C, Heschung A, Guntz P, Cazenave JP, Hansmann Y, Senegas A, *et al.* A new ELISA kit which uses a combination of *Plasmodium falciparum* extract and recombinant *Plasmodium vivax* antigens as an alternative to IFAT for detection of malaria antibodies. *Malar J* 2007;6:19.
24. Nadjm B, Behrens RH. Malaria: An update for physicians. *Infect Dis Clin North Am* 2012;26:243-59.
25. Abdel-Wahab MM, Ismail KA, El-Sayed NM. Laboratory diagnosis of malaria infection in clinically suspected cases using microscopic examination, OptiMAL rapid antigen test and PCR. *PUJ* 2012;5:59-66.
26. Philips CA, Kalal CR, Kumar KN, Bihari C, Sarin SK. Simultaneous occurrence of ocular, disseminated mucocutaneous, and multivisceral involvement of leishmaniasis. *Case Rep Infect Dis* 2014;2014:837625.
27. Montero JA, Ruiz-Moreno JM, Sanchis E. Intraretinal hemorrhage associated with leishmaniasis. *Ophthalmic Surg Lasers Imaging* 2003;34:212-4.
28. Sundar S, Rai M. Laboratory diagnosis of visceral leishmaniasis. *Clin Diagn Lab Immunol* 2002;9:951-8.
29. Agrawal S, Rai M, Sundar S. Management of visceral leishmaniasis: Indian perspective. *J Postgrad Med* 2005;51 Suppl 1:S53-7.
30. Halliez MC, Buret AG. Extra-intestinal and long term consequences of *Giardia duodenalis* infections. *World J Gastroenterol* 2013;19:8974-85.
31. Khalifa EA, Kholoud EA, Ali AL, El-Mashad AM, Negm OE. Ocular changes in giardiasis: Human and experimental studies. *Tanta Med Sci J* 2007;2:119-31.
32. Corsi A, Nucci C, Knafelz D, Bulgarini D, Di Iorio L, Polito A, *et al.* Ocular changes associated with *Giardia lamblia* infection in children. *Br J Ophthalmol* 1998;82:59-62.
33. Pettoello Mantovani M, Giardino I, Magli A, di Martino L, Guandalini S. Intestinal giardiasis associated with ophthalmologic changes. *J Pediatr Gastroenterol Nutr* 1990;11:196-200.
34. Knox DL, King J Jr. Retinal arteritis, iridocyclitis, and giardiasis. *Ophthalmology* 1982;89:1303-8.
35. Turnbull AM, Lin Z, Matthews BN. Severe bilateral anterior uveitis secondary to giardiasis, initially misdiagnosed as a side effect of metronidazole. *Eye (Lond)* 2013;27:1225-6.
36. Kean B, Sun T, Ellsworth R. *Color Atlas/Text of Ophthalmologic Parasitology*. 1<sup>st</sup> ed. New York: Igaku-Shoin; 1991.
37. Good B, Holland CV, Taylor MR, Larragy J, Moriarty P, O'Regan M. Ocular toxocariasis in schoolchildren. *Clin Infect Dis* 2004;39:173-8.
38. Hare AQ, Franco-Paredes C. Ocular larva migrans: A severe manifestation of an unseen epidemic. *Curr Trop Med Rep* 2014;1:69-73.
39. Hayashi E, Akao N, Fujita K. Evidence for the involvement of the optic nerve as a migration route for larvae in ocular toxocariasis of *Mongolian gerbils*. *J Helminthol* 2003;77:311-5.
40. Kim YJ, Moon CH, Chang JH. Toxocariasis of the optic disc. *J Neuroophthalmol* 2013;33:151-2.
41. Ahn SJ, Ryoo NK, Woo SJ. Ocular toxocariasis: Clinical features, diagnosis, treatment, and prevention. *Asia Pac Allergy* 2014;4:134-41.
42. Magnaval JF, Glickman LT, Dorchies P, Morassin B. Highlights of human toxocariasis. *Korean J Parasitol* 2001;39:1-11.
43. Campbell JP, Wilkinson CP. Imaging in the diagnosis and management of ocular toxocariasis. *Int Ophthalmol Clin* 2012;52:145-53.
44. Barisani-Asenbauer T, Maca SM, Hauff W, Kaminski SL, Domanovits H, Theyer I, *et al.* Treatment of ocular toxocariasis with albendazole. *J Ocul Pharmacol Ther* 2001;17:287-94.
45. Etya'ale D. Vision 2020: Update on onchocerciasis. *Community Eye Health* 2001;14:19-21.
46. Egbert PR, Jacobson DW, Fiadoyor S, Dadzie P, Ellingson KD. Onchocerciasis: A potential risk factor for glaucoma. *Br J Ophthalmol* 2005;89:796-8.
47. Murphy RP, Taylor H, Greene BM. Chorioretinal damage in onchocerciasis. *Am J Ophthalmol* 1984;98:519-21.
48. Van der Lelij A, Rothova A, Stilma JS, Vetter JC, Hoekzema R, Kijlstra A. Humoral and cell-mediated immune response against human retinal antigens in relation to ocular onchocerciasis. *Acta Leiden* 1990;59:271-83.
49. McKechnie NM, Braun G, Connor V, Kläger S, Taylor DW, Alexander RA, *et al.* Immunologic cross-reactivity in the pathogenesis of ocular onchocerciasis. *Invest Ophthalmol Vis Sci* 1993;34:2888-902.
50. Weil GJ, Steel C, Liftis F, Li BW, Mearns G, Lobos E, *et al.* A rapid-format antibody card test for diagnosis of onchocerciasis. *J Infect Dis* 2000;182:1796-9.
51. Golden A, Steel C, Yokobe L, Jackson E, Barney R, Kubofcik J, *et al.* Extended result reading window in lateral flow tests detecting exposure to *Onchocerca volvulus*: A new technology to improve epidemiological surveillance tools. *PLoS One* 2013;8:e69231.
52. Osei-Atweneboana MY, Awadzi K, Attah SK, Boakye DA, Gyapong JO, Prichard RK. Phenotypic evidence of emerging ivermectin resistance in *Onchocerca volvulus*. *PLoS Negl Trop Dis* 2011;5:e998.
53. Sabti K, Show D, Wani V, Ajmi MA. Resolution of bilateral multifocal subretinal cysticercosis without significant inflammatory sequelae. *Can J Ophthalmol* 2001;36:2014-217.

54. Gulliani BP, Dadeya S, Malik KP, Jain DC. Bilateral cysticercosis of the optic nerve. *J Neuroophthalmol* 2001;21:217-8.
55. Agarwal B, Vemuganti GK, Honavar SG. Intraocular cysticercosis simulating retinoblastoma in a 5-year-old child. *Eye (Lond)* 2003;17:447-9.
56. Babalola O, Adu A, Akano A. Ocular cysticercosis in a 32-year-old man in Abuja: ultrasonic features as an aid in diagnosis. *Clin Ophthalmol* 2013;7:2275-9.
57. Chung GW, Lai WW, Thulborn KR, Menner C, Blair NP, Pulido JS. Magnetic resonance imaging in the diagnosis of subretinal cysticercosis. *Am J Ophthalmol* 2002;134:931-2.
58. Sharma T, Sinha S, Shah N, Gopal L, Shanmugam MP, Bhende P, *et al.* Intraocular cysticercosis: Clinical characteristic and visual outcome after vitreoretinal surgery. *Ophthalmology* 2003;110:996-1004.
59. Swastika K, Dewiyani CI, Yanagida T, Sako Y, Sudarmaja M, Sutisna P, *et al.* An ocular cysticercosis in Bali, Indonesia caused by *Taenia solium* Asian genotype. *Parasitol Int* 2012;61:378-80.
60. Mehta M, Sen S, Sethi S, Pushker N, Bajaj MS, Chandra M. Large orbital hydatid cyst presenting as subconjunctival mass. *Ann Trop Med Parasitol* 2010;104:601-4.
61. Somay H, Emon ST, Orakdogan M, Berkman MZ. A primary orbital hydatid cyst. *J Clin Neurosci* 2012;19:898-900.
62. Limaiem F, Bellil S, Bellil K, Chelly I, Mekni A, Khaldi M, *et al.* Primary orbital hydatid cyst in an elderly patient. *Surg Infect (Larchmt)* 2010;11:393-5.
63. Ciurea AV, Giuseppe G, Machinis TG, Coman TC, Fountas KN. Orbital hydatid cyst in childhood: A report of two cases. *South Med J* 2006;99:620-4.
64. Lescano AG, Zunt J. Other cestodes: Sparganosis, coenurosis and *Taenia crassiceps* cysticercosis. *Handb Clin Neurol* 2013;114:335-45.
65. Giadinis ND, Psychas V, Polizopoulou Z, Papadopoulos E, Papaioannou N, Komnenou AT, *et al.* Acute coenurosis of dairy sheep from 11 flocks in Greece. *N Z Vet J* 2012;60:247-53.
66. Acha PN, Szyfres B. Zoonoses and Communicable Diseases Common to Man and Animals: Parasitosis. 3<sup>rd</sup> ed., Vol. 3. Washington, D.C: PAHO; 2003. p. 163-4.
67. Safar EH. Ophthalmomyiasis. *J Arab Soc Med Res* 2008;3:257-65.
68. Umanets N, Pasyechnicova N, Levitskaya G. Internal posterior ophthalmomyiasis: A case report. *Retin Physician* 2012;9:47-9.
69. Currier RW, Johnson WA, Rowley WA, Laudenbach CW. Internal ophthalmomyiasis and treatment by laser photocoagulation: A case report. *Am J Trop Med Hyg* 1995;52:311-3.
70. Vine AK, Schatz H. Bilateral posterior internal ophthalmomyiasis. *Ann Ophthalmol* 1981;13:1041-3.
71. Lagacé-Wiens PR, Dookeran R, Skinner S, Leicht R, Colwell DD, Galloway TD. Human ophthalmomyiasis interna caused by *Hypoderma tarandi*, Northern Canada. *Emerg Infect Dis* 2008;14:64-6.