

A Rare Chest Wall Deformity after Usage of a Tissue Expander for Breast Reconstruction

Yukiko Kuramoto, MD
Tomoyuki Yano, MD, FACS
Masayuki Sawaizumi, MD
Kenta Tanakura, MD
Hiroki Miyashita, MD

Summary: A 2-stage breast reconstruction using a breast tissue expander and prosthesis is a simple method of breast reconstruction with little donor-site morbidity and short surgery time. In this report, we present a rare case of chest wall deformity, which appeared during breast skin expansion with tissue expander. We present a case of a 31-year-old woman who underwent a 2-stage breast reconstruction with a tissue expander and breast prosthesis. She had a former history of autologous microtia reconstruction using costal cartilages to create a framework of the ear at the age of 10. During expansion, the woman developed an abnormal hollowing of the chest wall. Even though it was difficult to select an ideal size for the breast prosthesis, an excellent breast shape was obtained by measuring the actual breast projection that we needed, using ultrasound sonography. The patient was satisfied with the final result. In this case, the patient suffered from a postoperative chest wall deformity due to cartilage harvesting. This unfavorable result highlights the need for careful preoperative evaluation of risk factors that may lead to chest wall deformity when patients will have tissue expansion as a part of breast reconstruction. When thoracic deformity occurs, surgeons should realize that choosing an adequate implant becomes rather difficult. Ultrasound sonography helps surgeons in measuring the actual breast projection preoperatively. (*Plast Reconstr Surg Glob Open* 2018;6:e1950; doi: 10.1097/GOX.0000000000001950; Published online 1 November 2018.)

A tissue expander is widely used in breast reconstruction after a mastectomy. The 2-stage breast reconstruction using a tissue expander with a following breast prosthesis is considered to be a simple procedure of breast reconstruction with less donor-site morbidity and a short surgery time. Nowadays, breast reconstruction using a tissue expander can be safely performed by plastic surgeons, but several complications are still observed with this procedure, such as hematoma, infection, and capsular contracture. These common complications are well described in the past literature.

In this report, we present a rare case of chest wall deformity, which appeared during breast skin expansion with tissue expander. We speculate that the deformity was related to the patient's history, where costal cartilage was

harvested for microtia surgery, which was performed in childhood. There are a few reports addressing chest wall deformity due to osteoporosis, use of an overinflated expander, or radiotherapy, but there are no reports describing chest wall deformity caused by a tissue expander with a patient who has formerly had microtia treatment.¹⁻⁵

CASE REPORT

A 31-year-old woman had a total mastectomy and sentinel lymph node biopsy for a T1aN0M0 Stage I breast carcinoma of the right side of the breast. The patient had a medical history of a microtia surgery using an autologous costal cartilage graft harvested from right side of the chest at the age of 10 (Fig. 1). Multiple costal cartilages were harvested to create an ear framework for microtia surgery. No other comorbidity was observed in this patient, and there was no history of preoperative radiotherapy to the breast.

A 2-stage breast reconstruction using a tissue expander and breast prosthesis was planned. A Natrelle 133-MV 11 tissue expander (Allergan Inc., Irvine, Calif.) was placed to the defect due to total mastectomy at the same time as a mastectomy was performed. A spindle-shaped 3.5 × 10 cm

From the Department of Plastic and Reconstructive Surgery, Cancer Institute Hospital, Tokyo, Japan.

Received for publication December 27, 2017; accepted July 27, 2018.

Copyright © 2018 The Authors. Published by Wolters Kluwer Health, Inc. on behalf of The American Society of Plastic Surgeons. This is an open-access article distributed under the terms of the Creative Commons Attribution-Non Commercial-No Derivatives License 4.0 (CCBY-NC-ND), where it is permissible to download and share the work provided it is properly cited. The work cannot be changed in any way or used commercially without permission from the journal. DOI: 10.1097/GOX.0000000000001950

Disclosure: *The authors have no financial interest to declare in relation to the content of this article. The Article Processing Charge was paid for by the authors.*

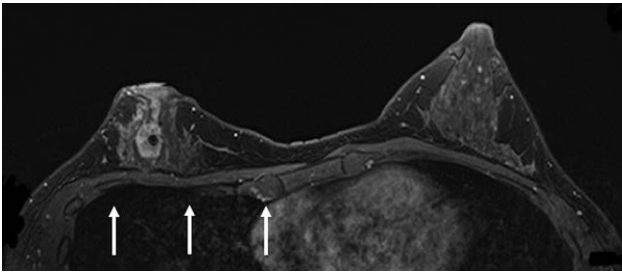


Fig. 1. Magnetic resonance imaging of the chest wall of our patient before mastectomy. White arrows show a slight depression deformity in the right chest wall.

breast skin including the nipple areola was resected. The size of the breast expander was selected according to the contralateral breast width, which was measured preoperatively. The tissue expander was placed under the pectoralis major muscle. The inferior border of the expander was placed symmetrical to the contralateral side of the breast. As there was no tension observed in the covering pectoralis major muscle over the tissue expander, we did not consider using AlloDerm to cover a part of the tissue expander. We used 80 ml of normal saline as the initial infusion volume. After obtaining the breast wound was healed, we injected 30 ml of normal saline into the tissue expander every 3 weeks. After 8 months, the expander reached a total volume of 280 ml. A preoperative chest x-ray examination showed a depression of the ribs under the tissue expander (Fig. 2). There was a noticeable chest wall depression deformity due to the tissue expander; there

was no respiratory dysfunction, no cardiac problem, and no complaint from the patient.

In our institute, there are no stocks of breast prostheses, and it is necessary for surgeons to make a preorder of breast prosthesis before surgery. Therefore, we use Vectra simulation (Canfield, 3D computed imaging system) and ultrasound sonography to determine a few suitable breast prostheses for the patient. With Vectra simulation, it seemed that Natrelle 410 MM 215 ml would be suitable as a breast prosthesis. With an ultrasound sonography evaluation of the chest wall depression deformity and actual projection of the tissue expander under the breast skin, we chose the projection F series prosthesis to achieve sufficient projection of the reconstructed breast. In detail, we made the patient in a sitting posture and performed ultrasound sonography evaluation to measure the actual vertical distance between the top of the tissue expander and the surface of the chest wall to determine the breast projection. Moreover, we chose the height F type prosthesis to compensate for the volume shortage of the upper breast area.

Finally, the second stage of this procedure was implemented using a Natrelle 410 FF 290 ml anatomical breast prosthesis (Allergan Inc.). A mesh-like capsulotomy was performed to ensure good extension of the breast skin, and the inframammary fold was reconstructed with some buried sutures during replacement of the breast prosthesis with the tissue expander. In addition, we used a sizer of MF 255 ml, which had the same projection as FF 290, during the operation to check the final volume and projection of the breast. Combined with preoperative ultrasound sonography evaluation and intraoperative sizer, we can easily

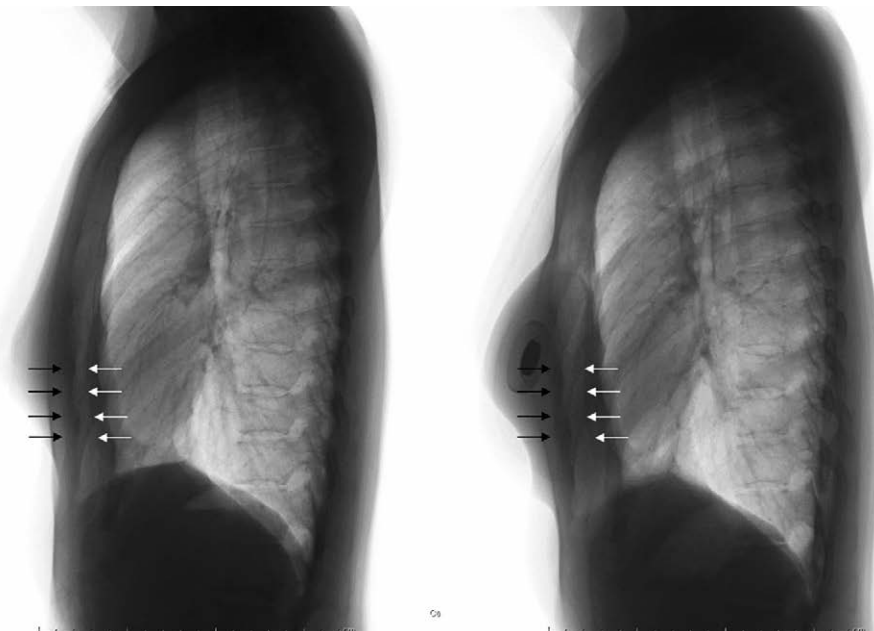


Fig. 2. A lateral chest x-ray image of the patient. The left-hand side shows the preoperative image, and the right-hand side shows the postoperative image with a breast expander. White arrows indicate the chest wall of the right side, surgery site, and black arrows indicate the chest wall of the left side, non-surgical site. A distance between white and black arrows became wider after the placement of a breast expander.

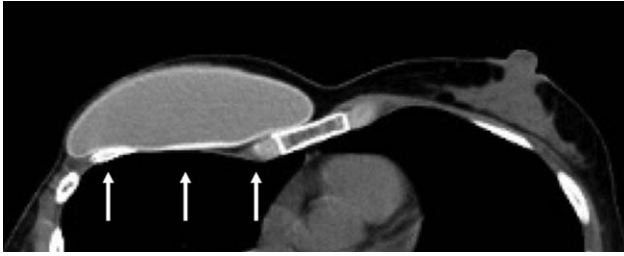


Fig. 3. Chest wall evaluation using computed tomography after the second surgery to place the breast prosthesis. White arrows indicate remarkable worsening of chest wall depression deformity after the surgery.

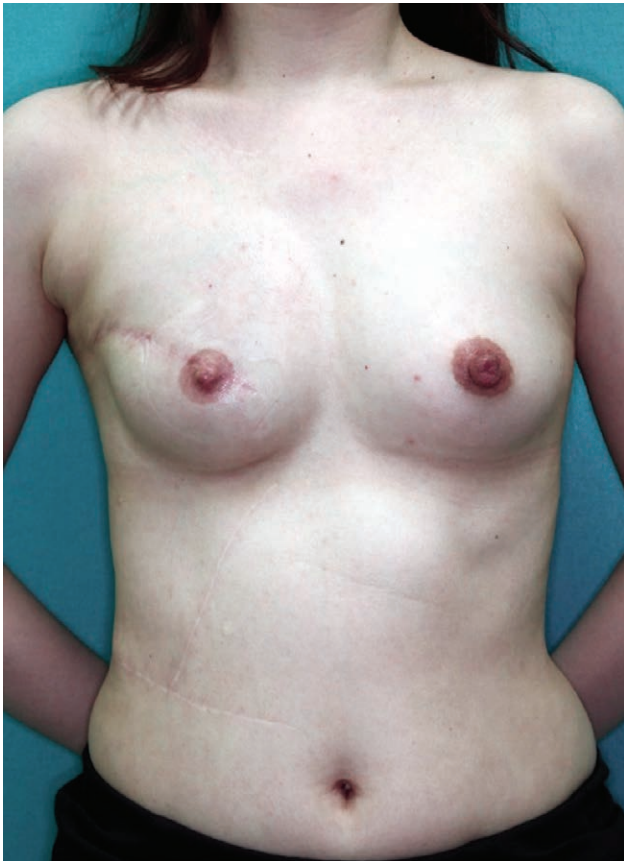

Fig. 4. Breast shape 6 months postoperatively. An excellent breast shape was obtained in this patient.

find and determine ideal type and size of breast prosthesis to the patient. The postoperative breast shape was evaluated using a computed tomography image (Fig. 3) and the Vectra system (Fig. 4). The patient had bilateral symmetry of the breast and excellent breast shape. The patient was satisfied with the final result (Fig. 5).

DISCUSSION

A 2-stage breast reconstruction using a prosthesis is one of the most commonly performed types of breast reconstruction,⁶⁻⁸ mainly because of its simple technique, short operating time, lack of donor-site morbidity, and quick patient recovery.

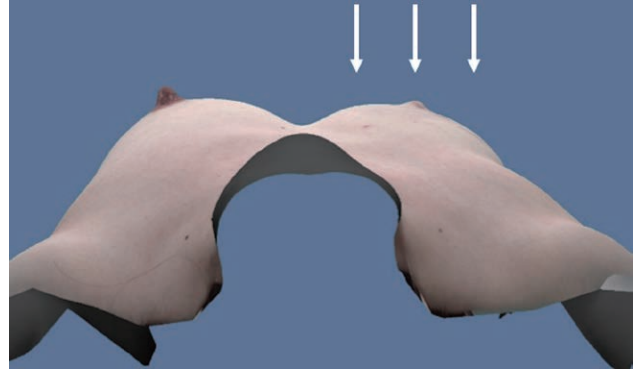


Fig. 5. 3D image of Vectra evaluation. White arrows show the reconstructed breast.

A chest wall deformity after tissue expansion has already been described in past literature. In 1991, Sinow et al.⁴ reported a prospective study on this kind of a chest wall deformity, using computed tomography imaging and a semiquantitative scale to measure the extent of deformity. They found that some form of rib deformity was observed in all of their patients, and moderate to strong rib depression was seen in 13% of their patients. Even an asymptomatic rib fracture was found in 1 patient. In these cases, all the tissue expanders had been overinflated up to a total volume that was 40–80% greater than the size of the final breast prosthesis. Moor et al.³ reported a similar study on tissue expanders; they also overinflated the expanders in all of their patients. Fifty-three percentage of their patients had some chest wall deformity, and they also found a statistically significant increase in the number of chest wall deformities compared with immediate reconstruction, which did not use tissue expanders. de Wildt et al.⁵ reported a case that resulted in a severe chest wall deformity after tissue expansion in a patient had undergone radiotherapy.

Microtia occurs in one out of about 8,000–10,000 births. There are some studies addressing donor-site problems. Ohara et al.⁹ reported that 14 of 22 patients (63.6%) who had undergone rib harvesting when younger than 9 years old showed postoperative chest-wall deformity; on the other hand, 2 of 10 patients (20.0%) who had undergone rib harvesting when older than 10 years old showed postoperative chest-wall deformity. These results imply that if a patient undergoes rib harvesting when younger than 10 there may be a risk of chest wall deformity owing to the immaturity of the rib structure. In our case, the patient had her rib harvesting at the age of 10. There was approximately 5 mm of depression deformity in the magnetic resonance images, but there was no noticeable deformity on the surface of the chest wall.

In our institute, we should make a preorder of breast prosthesis before surgery as we do not have any of stocks of a breast prosthesis. At this point, an ultrasound sonography was useful to measure the actual projection of the tissue expander and the thickness of the skin under the breast envelope preoperatively. We felt that the ultrasound sonography gave us practical information about

the true projection under the breast envelope, which we needed to choose an adequate breast prosthesis in the patient who suffered from severe chest wall deformity. We use Vectra simulation and ultrasound sonography to determine a few options of breast prosthesis for the patient, and a final decision of adequate prosthesis will be eventually decided by applying some sizers. When a tissue expander is used on a patient who has a possible risk of chest wall deformity, and if physician wants to reduce the risk of unfavorable complications, surgeons may consider having a longer interval between expansions, reducing the volume of each expander injection and the total volume of expansion, and carefully noticing patient complaints and symptoms about a patient chest wall shapes. In fact, we expanded the tissue expander with long interval and a small amount of injection each time to obtain soft and flexible breast skin expansion. We believe that chest wall deformity in this patient was mostly caused by chest wall structure weakness rather than overlying breast envelope tightness or contracture.

CONCLUSIONS

We found severe chest wall deformity after the usage of a tissue expander for breast reconstruction on a patient with a history of rib harvesting for microtia treatment in childhood. When there is a chest wall deformity, the choice and evaluation of the ideal size of a breast prosthesis becomes difficult. However, ultrasound sonography was useful and gave surgeons practical information for

choosing an adequate size of breast prosthesis for a patient with a chest wall deformity.

Yukiko Kuramoto, MD

3-8-31 Ariake, Koto-ku

Tokyo, Japan

E-mail: Yukiko.kuramoto@jfc.or.jp

REFERENCES

1. McKinney P, Edelson R, Terrasse A, et al. Chest-wall deformity following soft-tissue expansion for breast reconstruction. *Plast Reconstr Surg.* 1987;80:442–444.
2. Sariguney Y, Ayhan S, Eryilmaz T. Chest wall deformity after tissue expansion. *Scand J Plast Reconstr Surg Hand Surg.* 2008;42:108–109.
3. Moor EV, Wexler MR, Bar-Ziv Y, et al. Chest wall deformity following maximal tissue expansion for breast reconstruction. *Ann Plast Surg.* 1996;36:129–132.
4. Sinow JD, Halvorsen RA Jr, Matts JP, et al. Chest-wall deformity after tissue expansion for breast reconstruction. *Plast Reconstr Surg.* 1991;88:998–1004.
5. de Wildt RP, Stefania T, Rene R, et al. Substantial chest-wall deformity following tissue expansion after radiotherapy. *Eur J Plast Surg.* 2009;32:337–340.
6. Spear SL, Mesbahi AN. Implant-based reconstruction. *Clin Plast Surg.* 2007;34:63–73; abstract vi.
7. Hodgson EL, Malata CM. Implant-based breast reconstruction following mastectomy. *Breast Dis.* 2002;16:47–63.
8. Mesbahi AN, McCarthy CM, Disa JJ. Breast reconstruction with prosthetic implants. *Cancer J.* 2008;14:230–235.
9. Ohara K, Nakamura K, Ohta E. Chest wall deformities and thoracic scoliosis after costal cartilage graft harvesting. *Plast Reconstr Surg.* 1997;99:1030–1036.