

# Successful treatment of cardiac haemangiomas with oral propranolol: a case series of two patients

Ioannis Polymerou <sup>1</sup>, Tiina Ojala <sup>2</sup>, Pipina Bonou <sup>1</sup>, Laura Martelius<sup>3</sup>, and Aphrodite Tzifa<sup>1\*</sup>

<sup>1</sup>Department of Paediatric Cardiology and Adult Congenital Heart Disease, Mitera Hospital, Erithrou Stavrou, 15123 Athens, Greece; <sup>2</sup>Department of Pediatric Cardiology, Pediatric Research Center, New Children's Hospital, University of Helsinki, Helsinki University Hospital, Stenbäckinkatu 9, 00290 Helsinki, Finland; and <sup>3</sup>Department of Radiology, University of Helsinki, Helsinki University Central Hospital (HUCH), Stenbäckinkatu 9, 00290 Helsinki, Finland

Received 3 December 2018; first decision 8 January 2019; accepted 11 June 2019

## Background

Cardiac haemangiomas are extremely rare tumours with equivocal surgical outcomes. Haemangiomas appearing on other sites of the body have been successfully treated with oral propranolol. To the best of our knowledge, such treatment has not been tried to date for cardiac location of haemangiomas.

## Case summary

We report two cases of neonatal cardiac haemangiomas, and we describe their presentation and characteristics, as well as how these were successfully treated with oral propranolol, with complete regression of the tumours within the 1st year of life.

## Discussion

Despite the rarity of cardiac haemangiomas, their presentation and complications could be dramatic with side-effects spanning from intracardiac space occupying phenomena to Kasabach–Merritt syndrome. Propranolol therapy, having been established for long now in the treatment of skin haemangiomas, should also be considered in cases of cardiac haemangiomas, particularly in the neonatal and infantile population.

## Keywords

Cardiac tumour • Haemangioma • Propranolol • Neonatal • Infantile • Case series

## Learning points

- Neonatal/infantile cardiac haemangiomas may have similar characteristics to cutaneous haemangiomas.
- Oral propranolol has an established safety profile for this age group and a proved efficacy in treatment of cutaneous haemangiomas.
- Oral propranolol was effective in treating cardiac haemangiomas in our two cases and thus, we believe that it should be tried as a treatment option in similar cases.

## Introduction

Cardiac haemangiomas are extremely rare tumours with equivocal surgical outcomes.<sup>1</sup> Haemangiomas appearing on other sites of the body, predominantly the skin, have over the last 10 years been successfully treated with oral propranolol which has revolutionized their treatment and has demonstrated a very good safety profile.<sup>2</sup> To the best of our knowledge, such treatment has not been tried to date for cardiac location of haemangiomas.

We report two cases of neonatal cardiac haemangiomas that were successfully treated with oral propranolol, with complete regression

\* Corresponding author. Tel: +30 210 686 9788, Email: [atzifa@mitera.gr](mailto:atzifa@mitera.gr)

All authors contributed equally to the writing of this article.

Handling Editor: Richard Alexander Brown

Peer-reviewers: John Kanakakis and Hatem Soliman Aboumarie

Compliance Editor: Christian Fielder Camm

Supplementary Material Editor: Peregrine Green

© The Author(s) 2019. Published by Oxford University Press on behalf of the European Society of Cardiology.

This is an Open Access article distributed under the terms of the Creative Commons Attribution Non-Commercial License (<http://creativecommons.org/licenses/by-nc/4.0/>), which permits non-commercial re-use, distribution, and reproduction in any medium, provided the original work is properly cited. For commercial re-use, please contact [journals.permissions@oup.com](mailto:journals.permissions@oup.com)

of the tumours, hence we propose trial of propranolol in cases of neonatal or infantile haemangiomas before proceeding to other options.

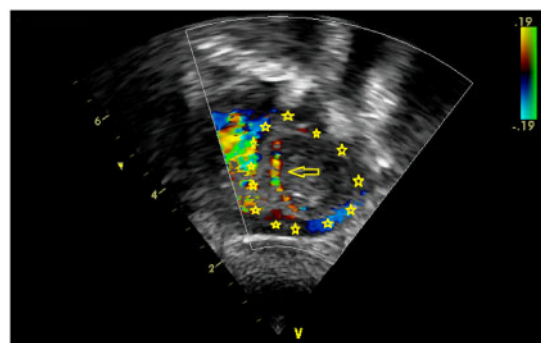
## Timeline

| Time                     | Events                                                                                                                                                                                                                                                                                                                                                          |
|--------------------------|-----------------------------------------------------------------------------------------------------------------------------------------------------------------------------------------------------------------------------------------------------------------------------------------------------------------------------------------------------------------|
| Case 1                   |                                                                                                                                                                                                                                                                                                                                                                 |
| Initial evaluation       | A female foetus was diagnosed with pericardial effusion that persisted and showed increase but no tamponade at 34 weeks of gestation. A cardiac mass was detected at 15 days of life. Cardiac haemangioma was diagnosed by magnetic resonance imaging (MRI) and clinical features of Kasabach–Merritt syndrome were seen at 45 days and propranolol was started |
| 3 days after treatment   | Improvement of thrombocytopenia and anaemia was noted                                                                                                                                                                                                                                                                                                           |
| 2 months after treatment | Reduction on the mass' size was observed                                                                                                                                                                                                                                                                                                                        |
| 12 months                | Complete resolution was demonstrated and propranolol was stopped                                                                                                                                                                                                                                                                                                |
| 4 years of follow-up     | There has been no relapse                                                                                                                                                                                                                                                                                                                                       |
| Case 2                   |                                                                                                                                                                                                                                                                                                                                                                 |
| Initial evaluation       | A female foetus was diagnosed with a cardiac tumour in the right atrium at a gestational age of 28 + 5 weeks                                                                                                                                                                                                                                                    |
| 2 months                 | Cardiac haemangioma was diagnosed by MRI and propranolol was started                                                                                                                                                                                                                                                                                            |
| 1 month after treatment  | Reduction on the mass' size was observed                                                                                                                                                                                                                                                                                                                        |
| 8 months after treatment | Complete resolution was demonstrated                                                                                                                                                                                                                                                                                                                            |
| 9 months                 | Propranolol was stopped                                                                                                                                                                                                                                                                                                                                         |
| 2 years of follow-up     | There has been no relapse                                                                                                                                                                                                                                                                                                                                       |

## Case presentation

### Case presentation 1

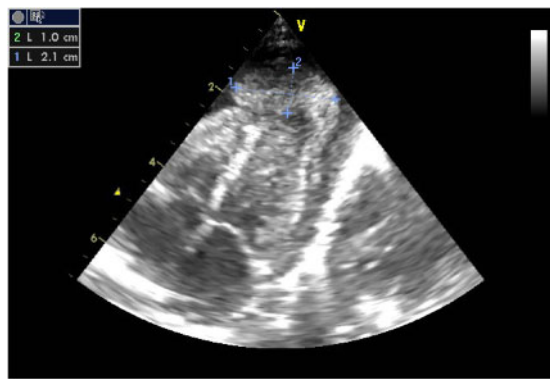
A female infant was diagnosed antenatally by ultrasound at 34 weeks of gestation with pericardial effusion that persisted and showed increase but no tamponade. Due to this finding the foetus was delivered by caesarean section at 37 + 2 weeks of gestation with a birthweight of 2530 g. On examination her heart sounds were normal with no murmurs and she had good volume pulses, with no respiratory distress or evidence of cardiac failure. Immediately, postnatally, the neonate had thrombocytopenia with platelet count as low as 22 000, haemorrhagic predisposition evident at venipuncture sites and



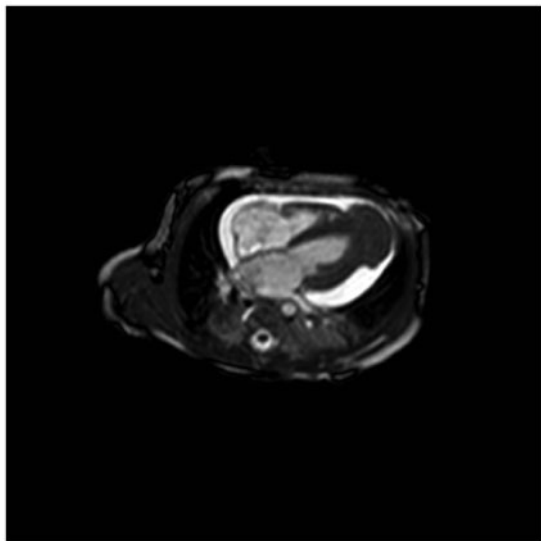
**Figure 1** Case 1: cardiac mass depicted at the apex of the heart with posterior tilt, demonstrating blood flow within it on an echocardiogram performed at 31 days of life. The yellow stars are outlining the borders of the mass and the yellow arrow is indicating the color doppler flow within the mass.

anaemia with Hb of 8 g/dL. She required several transfusions and was treated with intravenous (IV) immunoglobulin for 2 days and IV methylprednisolone at 4 mg/kg/day for 4 days, starting at the 3rd day of life. The pericardial effusion improved significantly and the neonate was discharged home at 15 days of life but was readmitted with tachypnoea, thrombocytopenia (platelets 90 000) and anaemia (Hb 8.1 g/dL) at 31 days of life. During this 2nd admission, a cardiac mass was detected by transthoracic echocardiography surrounding the apex of the left ventricle with obvious blood flow within it on colour Doppler (Figure 1). The mass appeared to be increasing in size and so was the pericardial effusion, despite treatment with corticosteroids. She had a full workup for all causes of thrombocytopenia including endocrinology tests, autoimmune tests, metabolic tests, bone marrow aspiration, and biopsy, with no abnormal findings.

She was referred to our hospital at 45 days of life for magnetic resonance imaging (MRI) of the heart, tissue characterization of the mass and further management. On admission her transthoracic echocardiogram showed a mass around 21 × 10 mm at the diaphragmatic border surrounding the apex of the left ventricle (Figure 2). The mass was very echogenic with no evidence of blood flow within it. The mass's echogenicity at that time resembled a large thrombus. Significant accumulation of pericardial fluid was noted. Magnetic resonance imaging tissue characterization suggested that the mass was consistent with haemangioma with thrombi within its crypts and measured 26 × 16 × 10 mm (Figure 3). Thrombosis explained the disappearance of flow within the haemangioma, that had been observed initially and in combination with the thrombocytopenia and anaemia, the diagnosis of Kasabach–Merritt syndrome was made.<sup>3</sup> No other haemangiomas were found during examination by chest computed tomography and abdominal ultrasound. The large pericardial effusion was drained to prevent tamponade; the aspirated fluid was blood-stained with Hb of 2 g/dL. It was decided to attempt treating the tumour with oral propranolol, starting at Day 48 of life, at a dose that was gradually titrated up to 3 mg/kg/day in three divided doses, along with a 2nd course of IV methylprednisolone at a dose of 1 mg/kg/day in two doses for 3 days. The response was immediate and within 3 days improvement of the thrombocytopenia and

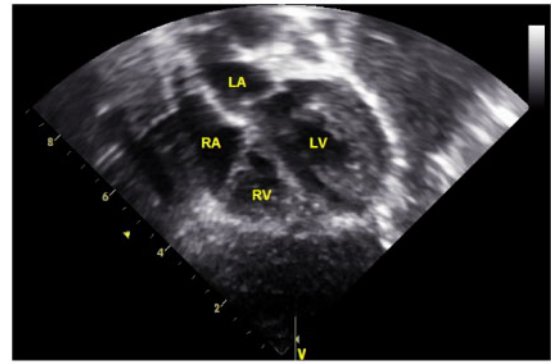


**Figure 2** Case 1: cardiac mass on echocardiogram at 45 days of life measuring  $10 \times 21$  mm.

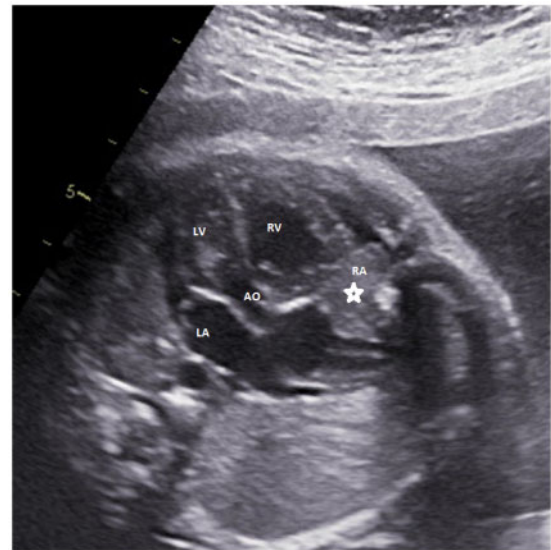

**Figure 3** Case 1: cardiac magnetic resonance imaging performed on the same day (Figure 2) was acquired.

anaemia were noted, with no recurrence of the effusion. Propranolol was continued at the same dose per kilogram. Interestingly, when propranolol had to be withheld for 5 days, subsequently to an episode of septicaemia and haemodynamic instability, the tumour started increasing again in size in its longitudinal diameter, and expanded over the diaphragmatic border of the right ventricle with a size of about  $34 \times 16$  mm. Propranolol was restarted and the size of the haemangioma eventually decreased to half of its original size within 3 months. The tumour completely disappeared within a year (Figure 4), when the decision was made for gradual discontinuation of therapy at the age of 14 months. Weaning was done by reducing from three doses per day to two doses per day for 1 week, then one dose per day for another week and then half of the single dose for the last week before stopping it completely. The child has been followed-up for the past 4 years with transthoracic echocardiograms



**Figure 4** Case 1: echocardiogram at 1 year of age showing no signs of residual haemangioma at the apex of the heart.

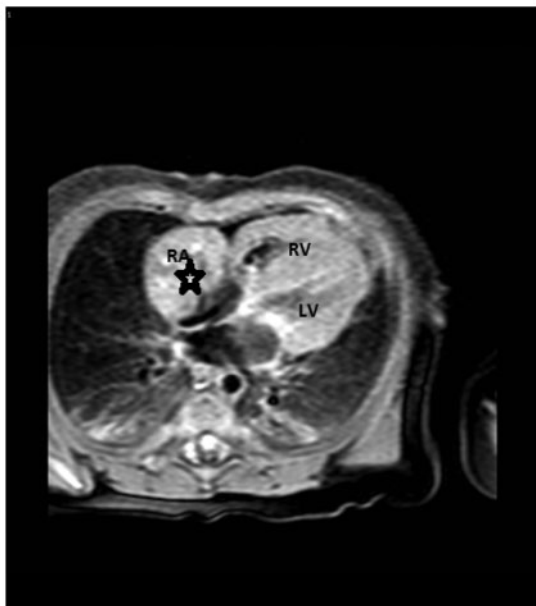


**Figure 5** Case 2: foetal echocardiogram at  $28 + 5$  weeks of gestation demonstrating a cardiac mass in the right atrium measuring  $11 \times 5$  mm. The star is marking the mass.

regularly and there has been no relapse of the haemangioma or further signs and symptoms of Kasabach–Merritt syndrome.

## Case presentation 2

A 38-year-old female was routinely followed-up by ultrasound during her 5th pregnancy when a foetal cardiac tumour was observed in the right atrium at a gestational age of  $28 + 5$  weeks. Previous pregnancies were uncomplicated. Foetal echocardiography confirmed an  $11 \times 15$  mm cardiac mass in the right atrium without haemodynamic compromise (Figure 5). A female neonate was born by vaginal delivery at  $38 + 6$  weeks of gestation weighing 3400 g. The patient was immediately transferred to the paediatric cardiac surgery intensive care unit for follow-up. A series of transthoracic echocardiograms

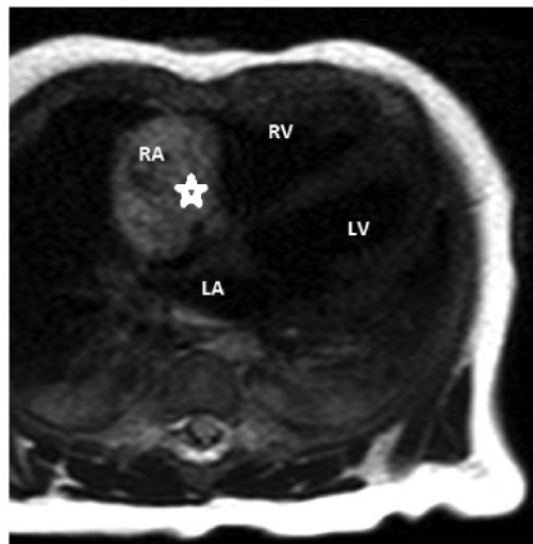


**Figure 6** Case 2: cardiac magnetic resonance imaging at 2 months of age showing a mass measuring 28 mm in diameter isointense on T1 sequence. The star is marking the mass.

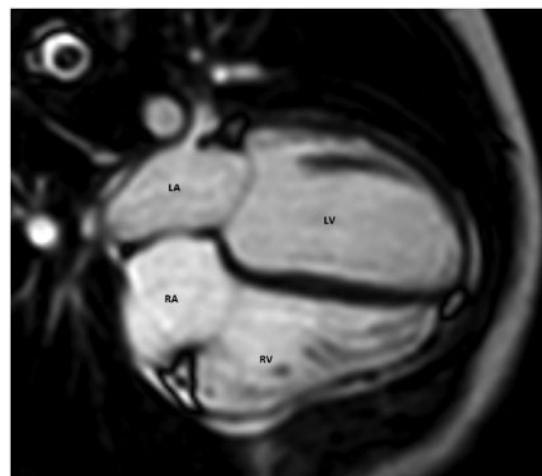
confirmed the prenatal diagnosis of a right atrial tumour originating from the opening of the right atrial appendage and also demonstrated increase of the tumour size during the 1st month of life, still with no haemodynamic compromise. Mild pericardial effusion was noted without inflow or outflow obstructions, arrhythmias or extracardiac anomalies. The neonate remained asymptomatic with a completely normal cardiovascular examination, and at the age of 2 months underwent cardiac MRI; that showed a mass measuring 28 mm in diameter, T1 isointense (Figure 6), T2 hyperintense, and highly vascular with inflow voids (Figure 7). In the 1st post perfusion images, strong enhancement appeared in the arterial phase. In the contrast enhanced images, the tumour was heterogenous (mostly strong enhancement), whilst it appeared isointense on the late-gad images. The diagnosis of infantile cardiac haemangioma was therefore suspected. No other haemangiomas were noted elsewhere. Oral propranolol was initiated at the age of 2 months and titrated to the dose of 3 mg/kg/day divided in three doses. Regression of the tumour size was noticed in consecutive transthoracic echocardiograms and finally the tumour disappeared completely at the age of 8 months. Propranolol was discontinued at the age of 9 months after normal cardiac MRI (Figure 8). The patient has been followed-up for 24 months since by transthoracic echocardiography, with no signs of relapse of the haemangioma.

## Discussion

Infantile haemangiomas of the skin are not a rare finding with a prevalence of 4–5% in term neonates.<sup>4</sup> However, as a cardiac tumour, haemangiomas are a rare occurrence in children, described only in a few



**Figure 7** Case 2: T2-cardiac magnetic resonance imaging sequence showing a hyperintense and highly vascular mass with inflow voids. The star is marking the mass.



**Figure 8** Case 2: cardiac magnetic resonance imaging at 8 months of age showing complete resolution of the atrial haemangioma.

case series. Given that the prevalence of cardiac tumours in children in general is as low as 0.0017–0.28% in autopsy series,<sup>5,6</sup> and the prevalence of haemangiomas is about 2.8–9% among cardiac tumours, one understands the rarity of this condition.<sup>1,7,8</sup>

The modern non-invasive imaging methods for detection of cardiac tumours have modified the approach to their diagnosis and management by allowing early and accurate detection.<sup>9</sup>

A comprehensive literature review by Weidong et al.<sup>1</sup> of 200 cardiac haemangiomas reported across all ages, and confirmed on histopathology following surgical resection found only 13 cases diagnosed in foetal life and 17 cases diagnosed between 0 and 9 years of age. All

other cardiac haemangiomas were diagnosed in adulthood, making infantile haemangiomas extremely rare. Microscopically, haemangiomas in general are usually divided into cavernous (haemangiomas composed of multiple, dilated, and thin-walled vessels), capillary (smaller capillary-like vessels), and arteriovenous types (dysplastic malformed arteries and veins). Cardiac haemangiomas often combine features of more than one subtype. Weidong *et al.* concluded that the cavernous type (51.1%) was the predominant subtype.

In the cases described in the literature thus far, treatment was either surgical resection or conservative follow-up and management of side-effects. Although cardiac haemangiomas are non-malignant tumours, they are frequently associated with adverse events caused by their size and location (obstructive phenomena, arrhythmias, syncope, angina, shortness of breath, and other cardiac tumour manifestations). They can also present with manifestations related to their nature, such as bleeding, which can lead to pericardial effusion if the location is in the pericardium. Their nature as vascular tumours also makes their resection more challenging due to the increased risk of bleeding.

Since the accidental discovery of propranolol's effectiveness in the treatment of infantile haemangiomas in 2008, the treatment of mainly skin lesions has been totally revolutionized.<sup>10</sup> Propranolol is a non-selective  $\beta$ -adrenergic receptor blocker.  $\beta$ -adrenergic receptors, including  $\beta_1$ -adrenergic and  $\beta_2$ -adrenergic receptors, are G-protein coupled receptors on endothelial cells that cause vasodilation, as well as overexpression of proangiogenic factors including VEGF and basic growth factor of fibroblasts (bFGF). The mechanism of action of propranolol in the treatment of infantile haemangiomas is still not entirely explained, but is thought to involve multiple processes including vasoconstriction, inhibition of angiogenesis and induction of apoptosis.<sup>11–14</sup> These effects are grouped into short-term, mid-term, and long-term effects.<sup>11</sup> The initial rapid involution of infantile haemangiomas during the first 1–3 days of propranolol treatment are likely related to its immediate vasoconstrictive effects and decrease in vasodilatory nitric oxide leading to softening.<sup>11,12</sup> Mid-term effects are mediated through inhibition of angiogenesis leading to progressive reduction in size due to a decrease in proangiogenic factors including VEGF, bFGF, and matrix metalloproteinases 2 and 9.<sup>11</sup> Long-term effects are thought to be due to induction of apoptosis in endothelial cells.<sup>11,15</sup>

Numerous studies regarding propranolol's effectiveness and safety profile have been published since. In a recent literature review,<sup>2</sup> Hagen *et al.* acknowledge the positive results of treatment with propranolol and report an acceptable side-effect profile, especially in healthy infants. Certain adverse effects are widely recognized, as attributed to its non-selective  $\beta$ -blocker activity. These include hypoglycaemia, hypotension, bradycardia, bronchospasm, sleep disturbances, and diarrhoea.<sup>10,16–18</sup>

To our knowledge, our described cases represent the 1st two cases in the literature where propranolol was tried and successfully treated cardiac haemangiomas with complete resolution of the cardiac tumours. Furthermore, propranolol—along with steroid therapy—was also effective in dealing with the sequelae of Kasabach–Merritt syndrome in our 1st case, although this is not the standard and has only been demonstrated in a few case reports of Kasabach–Merritt syndrome with extracardiac haemangiomas.<sup>19</sup>

The authors believe that infantile haemangiomas of the skin and the heart could have similar characteristics and behaviour. It is obviously difficult to accurately diagnose a haemangioma of the heart; however, the vascular characteristics of the tumour on MRI and echocardiogram, as well as the typical behaviour of rapid increase in size in the 1st weeks or months of life, should flag this up as a possible diagnosis. The authors' recommendation is that due to the low rate of side-effects of treatment with propranolol, the very quick response to treatment reported in our two cases of cardiac haemangiomas, similar to that of infantile haemangiomas of the skin, and the obvious risk of complications from surgical resection, all neonates and infants with cardiac tumours that resemble haemangiomas should receive a trial treatment with propranolol starting conservatively at 1 mg/kg/day in three divided doses and titrated up to 3 mg/kg/day in two to three divided doses for at least 4 weeks before considering surgical alternatives. If there is a response, the treatment should continue for the 1st year of life with subsequent tapering under continuous follow-up. As expected, there is no available data on recurrence of cardiac haemangiomas after discontinuation of propranolol therapy. Our two cases have been followed-up for 2 and 4 years, respectively and there has been no recurrence evident on echocardiography or MRI. Extrapolating data from case series on recurrence of haemangiomas of the skin, we could be looking at a 25% chance of recurrence; however, this number is affected by different variables like sex (more common in females), age at discontinuation of therapy (more common when it was stopped before 9 months of age comparing to 12–15 months of age) as well as factors concerning the tumours, like location and special tumour characteristics.<sup>20</sup> Mean age at initial rebound was 17 months,<sup>20</sup> which would justify a more close follow-up during the 1st months after discontinuation with echocardiograms and MRI.

## Conclusion

Despite the rarity of cardiac haemangiomas, their presentation and complications could be dramatic with side-effects spanning from intracardiac space occupying phenomena to Kasabach–Merritt syndrome. Propranolol therapy, having been established for long now in the treatment of skin haemangiomas, should also be considered in cases of cardiac haemangiomas, particularly in the neonatal and infantile population.

## Lead author biography



Dr Polymerou is a Paediatric Cardiologist in MITERA Hospital, Athens, Greece. He performed his undergraduate studies at the Aristoteles' University of Thessaloniki. He completed his training in Paediatrics in Athens, Greece and subspecialized in Paediatric Cardiology in England.



## Supplementary material

Supplementary material is available at *European Heart Journal - Case Reports* online.

**Slide sets:** A fully edited slide set detailing this case and suitable for local presentation is available online as [Supplementary data](#).

**Consent:** The author/s confirm that written consent for submission and publication of this case report including image(s) and associated text has been obtained from the patient in line with COPE guidance.

**Conflict of interest:** none declared.

## References

- Weidong L, Teng P, Hongfei X, Liang M, Yiming N. Cardiac hemangioma: a comprehensive analysis of 200 cases. *Ann Thorac Surg* 2015;**99**:2246–2252.
- Hagen R, Ghareeb E, Jalali O, Zinn Z. Infantile hemangiomas: what have we learned from propranolol? *Curr Opin Pediatr* 2018;**30**:499–504.
- Kelly M. Kasabach-Merritt phenomenon. *Pediatr Clin North Am* 2010;**57**:1085–1089.
- Munden A, Butschek R, Tom WL, Marshall JS, Poeltler DM, Krohne SE, Alió AB, Ritter M, Friedlander DF, Catanzarite V, Mendoza A, Smith L, Friedlander M, Friedlander SF. Prospective study of infantile haemangiomas: incidence, clinical characteristics and association with placental anomalies. *Br J Dermatol* 2014;**170**:907–913.
- McAllister HA Jr. Primary tumours of the heart and pericardium. *Pathol Annu* 1979;**14**:325–355.
- Nadas AS, Ellison RC. Cardiac tumors in infancy. *Am J Cardiol* 1968;**21**:363–366.
- Padalino MA, Vida VL, Boccuzzo G, Tonello M, Sarris GE, Berggren H, Comas JV, Di Carlo D, Di Donato RM, Ebels T, Hraska V, Jacobs JP, Gaynor JW, Metras D, Pretre R, Pozzi M, Rubay J, Sairanen H, Schreiber C, Maruszewski B, Basso C, Stellin G. Surgery for primary cardiac tumors in children, early and late results in a multicenter European Congenital Heart Surgeons Association Study. *Circulation* 2012;**126**:22–30.
- Delmo Walter EM, Javier MF, Sander F, Hartmann B, Ekkernkamp A, Hetzer R. Primary cardiac tumors in infants and children: surgical strategy and long-term outcome. *Ann Thorac Surg* 2016;**102**:2062–2069.
- Beroukhi RS, Prakash A, Valsangiacomo Buechel ER, Cava JR, Dorfman AL, Festa P, Hlavacek AM, Johnson TR, Keller MS, Krishnamurthy R, Misra N, Moniotte S, Parks WJ, Powell AJ, Soriano BD, Srichai MB, Yoo S-J, Zhou J, Geva T. Characterization of cardiac tumors in children by cardiovascular magnetic resonance imaging: a multicenter experience. *J Am Coll Cardiol* 2011;**58**:1044–1054.
- Léauté-Labrèze C, Dumas de la Roque E, Hubiche T, Boralevi F, Thambo JB, Taïeb A. Propranolol for severe hemangiomas of infancy. *N Engl J Med* 2008;**358**:2649–2651.
- Rotter A, de Oliveira ZNP. Infantile hemangioma: pathogenesis and mechanisms of action of propranolol. *J Dtsch Dermatol Ges* 2017;**15**:1185–1190.
- Darrow DH, Greene AK, Mancini AJ, Nopper AJ. Diagnosis and management of infantile hemangioma. *Pediatrics* 2015;**136**:e1060–e1104.
- Ji Y, Chen S, Xu C, Li L, Xiang B. The use of propranolol in the treatment of infantile haemangiomas: an update on potential mechanisms of action. *Br J Dermatol* 2015;**172**:24–32.
- Li P, Guo Z, Gao Y, Pan W. Propranolol represses infantile hemangioma cell growth through the b2-adrenergic receptor in a HIF-1a-dependent manner. *Oncol Rep* 2015;**33**:3099–3107.
- Wnek A, Andrzejewska E, Kobos J, Taran K, Przewratil P. Molecular and immunohistochemical expression of apoptotic proteins Bax, Bcl-2 and Caspase 3 in infantile hemangioma tissues as an effect of propranolol treatment. *Immunol Lett* 2017;**185**:27–31.
- Tang LY, Hing JW, Tang JY, Nishikawa H, Shahidullah H, Browne F, Chikermane A, Parulekar M. Predicting complications with pretreatment testing in infantile haemangioma treated with oral propranolol. *Br J Ophthalmol* 2016;**100**:902–906.
- Petrovic J, Trifunovic B, Vukomanovic G, Topalovic M, Trajkovic G, Parezanovic V. Oral propranolol for infantile hemangiomas: a prospective study on the role of 48-h Holter monitoring in additional safety assessment. *J Dermatolog Treat* 2017;**28**:554–558.
- Kim KH, Choi TH, Choi Y, Park YW, Hong KY, Kim DY, Choe YS, Lee H, Cheon J-E, Park J-B, Park KD, Kang HJ, Shin HY, Jeong JH. Comparison of efficacy and safety between propranolol and steroid for infantile hemangioma: a randomized clinical trial. *JAMA Dermatol* 2017;**153**:529–536.
- Mizutani K, Umaoka A, Tsuda K, Kakeda M, Habe K, Yamanaka K, Suyama M, Mizutani H. Successful combination therapy of propranolol and prednisolone for a case with congenital Kasabach-Merritt syndrome. *J Dermatol* 2017;**44**:1389–1391.
- Shah SD, Baselga E, McCuaig C, Pope E, Coulie J, Boon LM, Garzon MC, Haggstrom AN, Adams D, Drolet BA, Newell BD, Powell J, García-Romero MT, Chute C, Roe E, Siegel DH, Grimes B, Frieden IJ. Rebound growth of infantile hemangiomas after propranolol therapy. *Pediatrics* 2016;**137**:e20151754.