

## Images in Clinical Hematology

# Hemophilic pseudotumor – a rare complication



Márcio Luís Duarte<sup>a,b,\*</sup>, Élcio Roberto Duarte<sup>a,c</sup>, Edgard Brasil Solorzano<sup>c</sup>

<sup>a</sup> Clínica Radiológica e Especialidades Médicas São Gabriel, Praia Grande, SP, Brazil

<sup>b</sup> WebImagem, São Paulo, SP, Brazil

<sup>c</sup> Brasil Imagem Medicina Diagnóstica, Santos, SP, Brazil

### ARTICLE INFO

#### Article history:

Received 8 October 2016

Accepted 20 October 2016

Available online 29 December 2016

A 29-year-old male patient presented with progressive deformity of his left elbow since childhood. He was constantly treated with factor VIII for severe hemophilia A. He stated that he had no other diseases and had been submitted to any surgeries. At physical examination, he presented with restricted elbow extension (Figure 1A) and had a similar deformity of the right elbow.

The patient is negative for anti-factor VIII inhibitor. A radiograph demonstrated clear deformity of the distal humerus with lytic lesions and edema of the surrounding soft tissues (Figure 1B). Ultrasonography identified a heterogeneous,

ill-defined, oval image with an adjacent bone irregularity without vascularization by Doppler ultrasonography (Figure 1C). Magnetic resonance imaging (MRI) demonstrated morphostructural deformity of elbow joint, with extensive deposition of low signal material in the synovium and extraosseous hemophilic pseudotumor (Figure 1D).

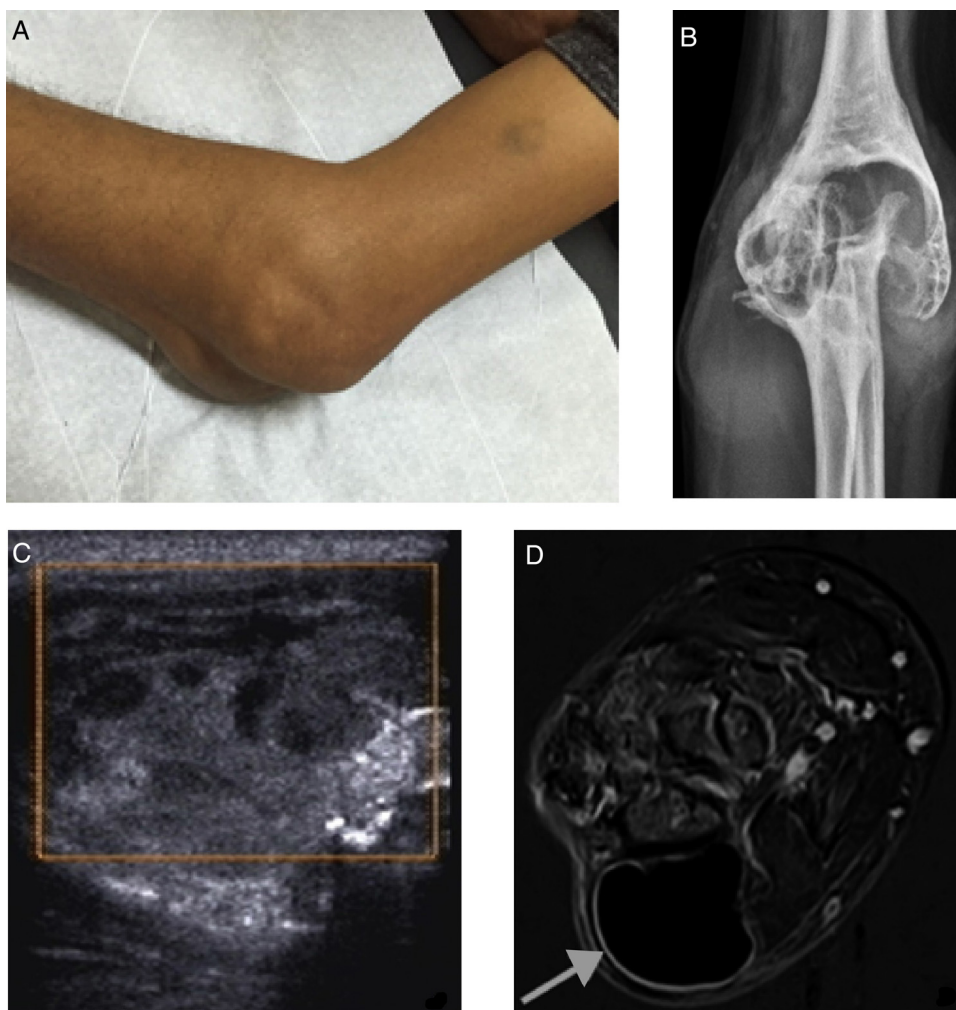
A hemophilic pseudotumor is the result of repeated episodes of bleeding at a bone fracture site or as a result of sub-periosteal hemorrhage or bleeding into soft tissue due to absence or lack of effective replacement treatment.<sup>1-3</sup>

\* Corresponding author at: Clínica Radiológica e Especialidades Médicas São Gabriel. Rua Mihailo Lukich Michel, 94 - Boqueirão, 11701-370 Praia Grande, SP, Brazil. Tel.: +5513981112799.

E-mail address: [marcioluisduarte@gmail.com](mailto:marcioluisduarte@gmail.com) (M.L. Duarte).

<http://dx.doi.org/10.1016/j.bjhh.2016.10.002>

1516-8484/© 2016 Associação Brasileira de Hematologia, Hemoterapia e Terapia Celular. Published by Elsevier Editora Ltda. This is an open access article under the CC BY-NC-ND license (<http://creativecommons.org/licenses/by-nc-nd/4.0/>).



**Figure 1 – (A) Physical examination of the elbow demonstrating limited joint extension and deformity. (B) Radiography with notable bone deformity, in particular the distal humerus. (C) Ultrasonography demonstrating heterogeneous, ill defined, oval deformity with adjacent bone irregularity without vascularization according to a Doppler study. (D) Contrast T1 FAT SAT MRI with subtraction shows morphostructural deformity of elbow joint, with extensive deposition of low signal material in the synovium (hemosiderin) and extra-osseous hemophilic pseudotumor measuring 4.9 × 3.5 × 3.6 cm (gray arrow).**

### Conflicts of interest

The authors declare no conflict of interest.

### REFERENCES

1. Mahmud AA, Bashir Y, Taura MG, Adamu LH. Haemophilic pseudotumor: a rare pathological entity involving 5<sup>th</sup> metacarpal and associated tissues. *Sch J App Med Sci.* 2015;3(4B):1707-11.
2. Pakala A, Thomas J, Comp P. Hemophilic pseudotumor: a case report and review of literature. *Int J Clin Med.* 2012;3:229-33.
3. Stafford JM, James TT, Allen AM, Dixon LR. Hemophilic pseudotumor: radiologic-pathologic correlation. *Radiographics.* 2003;23(4):852-6.