



## Case Report

*Trichosporon* fungemia in a pediatric patient with acute lymphoblastic leukemiaLuke Maxfield<sup>\*</sup>, Juliana J. Matthews<sup>\*\*</sup>, David Ryan Ambrosetti<sup>\*\*\*</sup>, Issa E. Ephtimios<sup>\*\*\*\*</sup>

5151 N. Ninth Avenue, Pensacola, FL 32504, United States

## ARTICLE INFO

## Article history:

Received 28 July 2015

Accepted 22 September 2015

## Keywords:

*Trichosporon*

Fungemia

Acute lymphoblastic leukemia

Antifungal resistance

## ABSTRACT

*Trichosporon* fungemia is a life-threatening opportunistic infection that is increasing in frequency. Invasive disease occurs almost exclusively in immunocompromised hosts, particularly in neutropenic adults with hematological malignancies and uncommonly in children. We report the case of a pediatric patient where disseminated trichosporonosis progressed while on micafungin, between treatments with voriconazole and amphotericin B, demonstrating the difficulty with and importance of prolonged and continuous treatment.

© 2015 The Authors. Published by Elsevier Ltd. This is an open access article under the CC BY-NC-ND license (<http://creativecommons.org/licenses/by-nc-nd/4.0/>).

## Introduction

*Trichosporon* fungemia is an emerging opportunistic infection that is increasing in frequency. The species *T. asahii* has been known to cause invasive disease. This occurs most commonly in those who are immunocompromised, usually neutropenic adults, and uncommonly in children. We present the case and complicated management of a pediatric patient with recently diagnosed acute lymphoblastic leukemia who developed fatal disseminated *T. asahii* after induction chemotherapy.

## Case report

A 3-year-old previously healthy female presented to the emergency room with a three-week history of chest pain, fatigue, dyspnea on exertion, bruising, and pallor. A complete blood count

showed leukocytosis (42,300/L) and thrombocytopenia (91,000/L). Pediatric hematology/oncology was consulted, and the patient was ultimately diagnosed with acute lymphoblastic leukemia (ALL). Induction chemotherapy was initiated with pegaspargase, vincristine, and daunorubicin.

A week later the patient developed a fever along with pancytopenia. Empiric coverage included vancomycin, cefepime, and tobramycin. Forty-eight hours later blood cultures grew *Trichosporon* spp. with sensitivity to voriconazole (VCZ) and amphotericin B. Intravenous (IV) VCZ therapy was initiated at 180 mg every 12 h. Despite subsequent negative cultures, she remained febrile intermittently. On hospital day 12 the patient showed evidence of acute kidney injury, hypertension, and toxic levels of both vancomycin (37.7 µg/m) and tobramycin (2.5 µg/mL). Tobramycin and cefepime were replaced with meropenem and vancomycin was replaced with linezolid to minimize kidney injury. Voriconazole was discontinued secondary to concern for renal toxicity, and micafungin was initiated.

The patient's condition continued to deteriorate, and on day 23 the patient was intubated secondary to respiratory failure; she remained on mechanical ventilation for the duration of her care. The patient was noted to have multiple maculopapular skin lesions (Fig. 1) involving her trunk and bilateral lower extremities that were suggestive of fungal emboli. Skin biopsies obtained on day 29 (Figs. 2 and 3) revealed *Trichosporon* spp. and blood cultures grew *T. asahii*.

At this time, infectious disease was consulted and antifungals were changed to combination VCZ (80 mg IV twice daily) and

<sup>\*</sup> Permanent address: Lake Erie College of Medicine, 198 Red Bird Court, Soddy Daisy, TN 37379, United States. Tel.: +1 719 201 3373.

<sup>\*\*</sup> Co-corresponding author at: Florida State University College of Medicine, 2837 Bay St., Gulf Breeze, FL 32563, United States. Tel.: +1 850 384 3477.

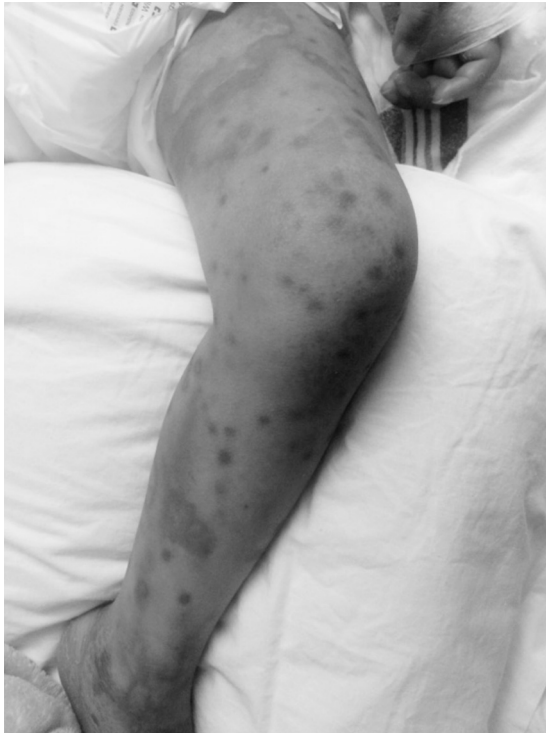<sup>\*\*\*</sup> Co-corresponding author at: Lake Erie College of Medicine, 1399 Ashes Ave., Soddy Daisy, TN 37379, United States. Tel.: +1 423 774 7122.

<sup>\*\*\*\*</sup> Co-corresponding author at: Division of Infectious Disease, Department of Internal Medicine, Florida State University College of Medicine, 9013 University Pkwy Suite H, Pensacola, FL 32514, United States. Tel.: +1 850 912 8433.

E-mail addresses: [luke.maxfield@med.lecom.edu](mailto:luke.maxfield@med.lecom.edu) (L. Maxfield),

[jm11m@med.fsu.edu](mailto:jm11m@med.fsu.edu) (J.J. Matthews), [david.ambrosetti@med.lecom.edu](mailto:david.ambrosetti@med.lecom.edu)

(D.R. Ambrosetti), [drephtimiosissa@yahoo.com](mailto:drephtimiosissa@yahoo.com) (I.E. Ephtimios).

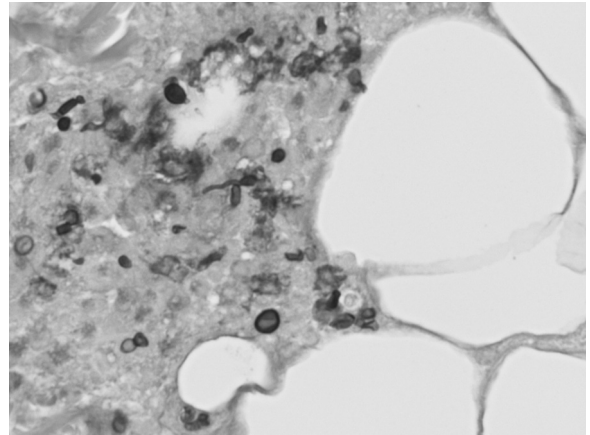


**Fig. 1.** Maculopapular lesions on the extremities of a pediatric patient with disseminated trichosporonosis.

amphotericin B liposome (16 mg IV daily) with monitoring of VCZ levels biweekly.

For the next two weeks, on combination treatment of VCZ and amphotericin B liposome, the skin lesions slowly improved. All cultures remained negative until day 49 when the patient developed intermittent spiking fevers with urine cultures again growing *Trichosporon* spp. On day 66 urine cultures were negative for *Trichosporon* spp with blood and urine cultures remaining negative for the duration of care. Skin biopsies were repeated to monitor progression, and an umbilical lesion showed evidence of fungal elements, though the clinical significance was uncertain.

On hospital day 105 the patient expired secondary to extensive end organ damage despite extraordinary measures. Although treatment did not impact mortality, the fungemia had resolved on VCZ as well as responded to combination VCZ and amphotericin B emphasizing the importance of continued treatment even after



**Fig. 3.** PAS stained at 600 times magnification revealing fungal elements of patient with disseminated *Trichosporon asahii* infection, including true hyphae, pseudohyphae, arthroconidia, and blastospores.

negative cultures. This case demonstrates the persistence of the organism *Trichosporon* spp. as well as the difficulty with treatment.

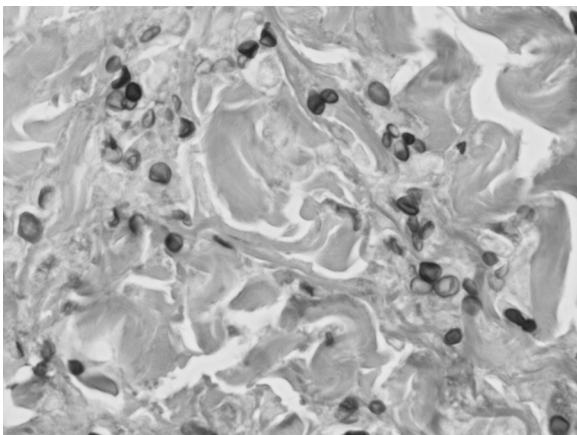
### Discussion

Over the past two decades the non-*Candida* yeasts, including *Trichosporon* spp., have been increasingly associated with life-threatening disease in immunocompromised individuals [1]. Profound granulocytopenia in patients with hematological malignancies has been reported as the most common risk factor for disseminated disease [2]. Additional predisposing factors include organ transplantation, chronic kidney disease, intravenous catheters, chemotherapy, corticosteroid therapy, extensive burns, prosthetic valve surgery, and peritoneal dialysis [1,2].

*Trichosporon* spp. are widely distributed in nature, predominantly in soil, and may be part of the normal biota of the skin, oral cavity, respiratory tract, gastrointestinal tract, and vagina. The genus currently consists of six species that are of clinical significance. *T. asahii*, as found in our patient, *T. asteroides*, and *T. mucoides* are known to cause invasive infections. *T. ovoides*, *T. inkin*, and *T. cutaneum* can cause white piedra while *T. cutaneum* can also cause an allergic pneumonia [3].

*Trichosporon* spp. is known to colonize many different parts of the body including the gastrointestinal system, respiratory system, skin, and vagina. Invasive disease may be preceded by gastrointestinal colonization and translocation throughout the gut in those with mucositis and enteritis from cytotoxic chemotherapy [3]. Repeated positive sputum cultures indicate colonization that could progress toward pulmonary trichosporonosis in the neutropenic patient, and can be confirmed by microscopic examination of lung biopsy specimens [4]. A shift to a prevalence of catheter-related fungemia cases, without evidence of organ involvement, has also been reported [5].

*Trichosporon* spp. can cause both superficial and invasive infection. The latter can be divided into disseminated and localized forms. Disseminated disease is more common and typically presents as an acute febrile illness that can rapidly to multi-organ failure [3]. Skin lesions are found in about one-third of patients with trichosporonosis. The cutaneous manifestations include erythematous papules on the trunk and extremities. Over time, the papules may develop bullae or central necrosis and resemble eschars [6]. Patients with pulmonary involvement may have dyspnea and a cough productive of bloody sputum. Chest radiographs typically show diffuse infiltrates with an alveolar



**Fig. 2.** PAS staining at 600 times magnification from skin lesion, which revealed budding yeasts and rare hyphae adjacent to fat.

pattern [4]. Urinary tract infections are a common occurrence that can occasionally cause renal damage and aggravation of renal dysfunction [3].

In *Trichosporon* fungemia blood cultures are frequently positive. Cultures of urine, sputum, cerebrospinal fluid, and tissue have also yielded the fungus [6]. Culture and histopathology of skin lesions have also been helpful in establishing the diagnosis. Skin biopsies show dermal invasion by hyphae and arthroconidia, and some have shown thromboembolic vasculitis due to the organism [6]. It should be emphasized that cultures of *Trichosporon* isolated from sputum or urine may represent colonization rather than infection.

Despite advances in the treatment of fungemia, first-line therapy for trichosporonosis has yet to be determined [5]. Tentative recommendations can be made based on in vitro susceptibility data, but the optimal agent and duration of treatment is not known [2]. Voriconazole, alone or in combination, is potentially the drug of choice for disseminated disease [7]. Newer triazoles, such as posaconazole and ravuconazole, have also shown potent in vitro activity against *Trichosporon* spp. [8]. Those who cannot tolerate voriconazole due to its side effects may use amphotericin B, flucytosine, fluconazole, and itraconazole as alternatives, although multidrug resistance to these has been reported [2]. Although amphotericin B has shown some positive effectiveness to *Trichosporon* spp. in vitro, it functions poorly with breakthrough infections, especially those seen in patients with profound neutropenia on high doses of amphotericin B [9]. Echinocandins have excellent activity against a broad spectrum of fungi including *Aspergillus* and *Candida* species and have been selected in the setting of renal impairment as they have minimal toxicity. They, however, are not effective in treating trichosporonosis nor should they be used prophylactically as it has been reported that their use may select for resistant fungal organisms [10].

The prognosis of trichosporonosis has been poor, with mortality rates in excess of 80% [3]. To date, the only reported cures have been patients who were either not neutropenic at the time of diagnosis or who recovered from their neutropenia quickly [1]. In patients with leukemia survival is thought to be primarily related to bone marrow recovery [4]. If a patient recovers from disseminated infection, maintaining chronic suppressive therapy should be considered since late relapses have occurred. Oral voriconazole is currently the easiest agent to use for this purpose [11]. Ongoing suppressive therapy is particularly important for those with endocarditis or central nervous system involvement. Patients with chronic immunosuppressive conditions should potentially continue therapy indefinitely [11].

The high mortality rates associated with invasive infections occur despite the availability of antifungals with less toxicity and improved potency [9]. Early treatment has been related to better outcomes, but this is dependent on diagnostic tests that are both rapid and highly sensitive [12]. As traditional histology- and culture-based methods have poor sensitivity and often only make a diagnosis late when the fungal burden is high, research has turned its focus to developing improved molecular and serological assays [12]. Several *Trichosporon*-specific tests have been developed in the last two decades, including PCR-based methods, flow cytometry, and proteomics [3]. Though these new assays are not yet standardized to be used routinely in clinical settings, they represent key strategies for future diagnostic validation [3].

In conclusion, *Trichosporon* species cause life-threatening infections, particularly in neutropenic patients. Emerging infections are often difficult to diagnose, are refractory to conventional antifungal agents, and are associated with high mortality rates [2,5]. Early detection of this unusual pathogen is essential to

provide specific timely antifungal therapy and improve the patient's chance of survival. Therefore, clinicians should have a high index of suspicion for *Trichosporon* fungemia in patients with aforementioned risk factors, particularly in those with hematologic malignancies who have catheters in place. Removal of central venous lines and control of underlying conditions should be considered to optimize clinical outcomes [3]. This case illustrates that once blood cultures grow *Trichosporon*, therapy with voriconazole or combination therapy with voriconazole and amphotericin B should be utilized for prolonged treatment. Despite a better side effect profile echinocandins are ineffective for both eradication and maintenance.

## Funding

The work of authors Maxfield, Matthews, Ambrosetti, and Ephantios received no funding support.

## Conflicts of interest

The authors declare that they have no conflict of interest.

## Ethical approval

IRB approval of waiver of consent was obtained for publication of this case report and accompanying images. IRB-Net ID 682249-1.

## Acknowledgements

The authors would like to graciously thank Dr. Patterson and Dr. Anderson for their help in completing this project. They also thank Sacred Heart Hospital of Pensacola, FL and Florida State University College of Medicine's Pensacola campus.

## References

- Anaissie E, Gokaslan A, Hachem R, Rubin R, Griffin G, Robinson R, et al. Azole therapy for trichosporonosis: clinical evaluation of eight patients, experimental therapy for murine infection, and review. *Clin Infect Dis* 1992;15(5):781–7.
- Girmenia C, Pagano L, Martino B, D'Antonio D, Fanci R, Specchia G, et al. Invasive infections caused by *Trichosporon* species and *Geotrichum capitatum* in patients with hematological malignancies: a retrospective multicenter study from Italy and review of the literature. *J Clin Microbiol* 2005;43:1818–28.
- Colombo AL, Padovan AC, Chaves GM. Current knowledge of *Trichosporon* spp. and trichosporonosis. *Clin Microbiol Rev* 2011;24:682–700.
- Tashiro T, Nagai H, Nagaoka H, Goto Y, Kamberi P, Nasu M. *Trichosporon beigelii* pneumonia in patients with hematologic malignancies. *Chest* 1995;108(1):190–5.
- Shang ST, Yang YS, Peng MY. Nosocomial *Trichosporon asahii* fungemia in a patient with secondary hemochromatosis: a rare case report. *J Microbiol Immunol Infect* 2010;43:77–80.
- Nahass GT, Rosenberg SP, Leonardi CL, Penneys NS. Disseminated infection with *Trichosporon beigelii*, report of a case and review of the cutaneous and histologic manifestations. *Arch Dermatol* 1993;129:1020.
- Falk R, Wolf DG, Shapiro M, Polachek I. Multidrug-resistant *Trichosporon asahii* isolates are susceptible to voriconazole. *J Clin Microbiol* 2003;41:911.
- Paphitou NI, Ostrosky-Zeichner L, Paetznick VL, Rodriguez JR, Chen E, Rex JH. In vitro antifungal susceptibilities of *Trichosporon* species. *Antimicrob Agents Chemother* 2002;46:1144–6.
- Walsh TJ, Groll A, Hiemenz J, Fleming R, Roilides E, Anaissie E. Infections due to emerging and uncommon medically important fungal pathogens. *Clin Microbiol Infect* 2004;10(Suppl. 1):48–66.
- Matsue K, Uryu H, Koseki M, Asada N, Takeuchi M. Breakthrough trichosporonosis in patients with hematological malignancies receiving micafungin. *Clin Infect Dis* 2006;42:753–7.
- Asada N1, Uryu H, Koseki M, Takeuchi M, Komatsu M, Matsue K. Successful treatment of breakthrough *Trichosporon asahii* fungemia with Voriconazole in a patient with acute myeloid leukemia. *Clin Infect Dis* 2006;43(4):e39–41.
- Morrissey C. Advancing the field: evidence for new management strategies in invasive fungal infections. *Curr Fungal Infect Rep* 2013;7:51–8.