

## [ Orthopaedic Surgery ]



# Turf Toe: Anatomy, Diagnosis, and Treatment

Jeremy J. McCormick, MD,\*† and Robert B. Anderson, MD‡

**Context:** Despite an increasing awareness of turf toe injury, confusion still exists regarding the anatomy, mechanism, diagnosis, and treatment of this hyperextension injury to the hallux metatarsophalangeal (MTP) joint.

**Evidence Acquisition:** This article reviews the anatomy, diagnosis, and treatment algorithm for turf toe injury by reviewing relevant studies and presenting information useful to clinicians, therapists, and athletic trainers. A literature search was performed by a review of PubMed and OVID articles published from 1976 to July 2010.

**Results:** Grade I injury is a sprain or attenuation of the plantar capsular ligamentous complex of the hallux MTP joint; athletes are typically able to return to play as tolerated. Grade II injury is a partial rupture of the plantar soft tissue structures of the hallux MTP joint, typically requiring about 2 weeks to recover. Grade III injury is a complete rupture of the plantar structures of the hallux MTP joint, requiring at least 10 to 16 weeks to recover. Some complete ruptures require surgical repair.

**Conclusion:** With accurate diagnosis, athletes can have an appropriate treatment plan, and their expectations can be tempered to the degree of injury. Careful management may allow successful return to play at a preinjury level of participation.

**Keywords:** turf toe; plantar plate; injury; hallux

Turf toe injury was originally described in 1976 by Bowers and Martin at the University of West Virginia, where they noted an average of 5.4 turf toe injuries per season among football players.<sup>3</sup> Coker et al<sup>6</sup> at the University of Arkansas and Clanton et al<sup>5</sup> at Rice University published similar data, finding 6.0 and 4.5 turf toe injuries per football season, respectively. The injury was further described in 1990 when Rodeo et al reported on professional football players in the National Football League.<sup>18</sup> The authors found that in a survey of 80 active players, 45% had suffered turf toe injuries in their professional careers, with 83% occurring on artificial turf.

Despite a recent increase in awareness, confusion still exists regarding turf toe injury. By definition, it is a primarily hyperextension force to the hallux metatarsophalangeal (MTP) joint that injures the plantar structures of the MTP joint.

## ANATOMY

Most of the stability of the hallux MTP joint comes from the capsule, ligaments, and short flexor complex (Figure 1). There is little inherent stability to the joint because the proximal phalanx has a fairly shallow cavity in which the metatarsal head articulates. Fan-shaped medial and lateral collateral ligaments

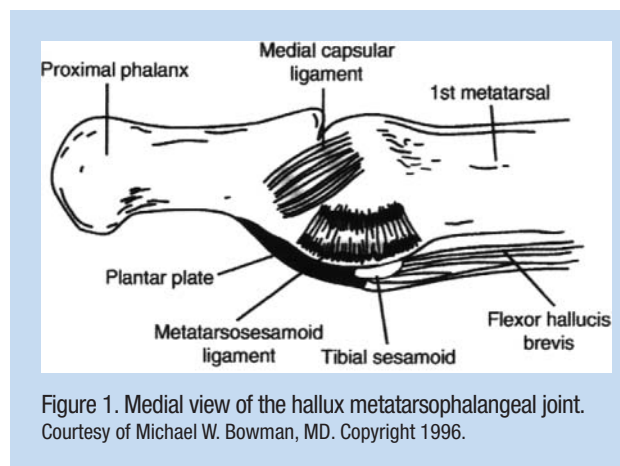


Figure 1. Medial view of the hallux metatarsophalangeal joint. Courtesy of Michael W. Bowman, MD. Copyright 1996.

provide valgus and varus stability, respectively. Each comprise a collateral component between the first metatarsal and proximal phalanx and a metatarsosesamoid slip. The plantar plate is the greatly thickened plantar capsule that courses from a weaker attachment on the metatarsal head to a more firm attachment on the proximal phalanx. In addition to the collateral ligaments and

From †Washington University, St. Louis, Missouri, and ‡Foot and Ankle Service, Department of Orthopaedic Surgery, Carolinas Medical Center, OrthoCarolina, Charlotte, North Carolina

\*Address correspondence to Jeremy J. McCormick, MD, Washington University, Department of Orthopaedic Surgery, 14532 South Outer Forty Drive, Chesterfield, MO 63017 (e-mail: mccormickj@wudosis.wustl.edu).

No potential conflict of interest declared.

DOI: 10.1177/1941738110386681

© 2010 The Author(s)

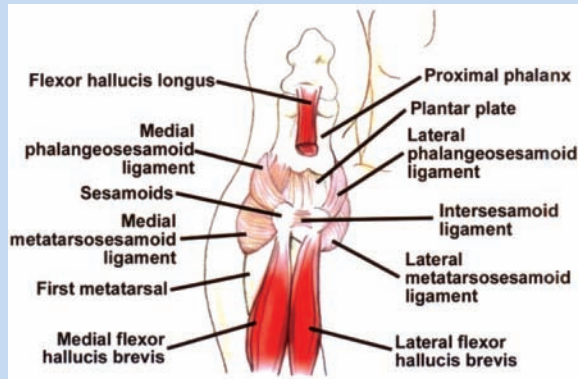


Figure 2. Plantar view of the hallux metatarsophalangeal joint.

Image reprinted with permission from eMedicine.com, 2010. Available at <http://emedicine.medscape.com/article/1236962-overview>.

plantar plate, the hallux MTP joint is dynamically stabilized by the short flexor complex (the flexor hallucis brevis [FHB] and the hallucal sesamoids embedded in the FHB tendons), the adductor hallucis, and the abductor hallucis tendons.

The FHB tendon inserts on the proximal phalanx in confluence with the plantar plate (Figure 2). The muscle originates proximally on the plantar aspect of the foot, primarily from the cuboid and lateral cuneiform. As the FHB moves distally toward its insertion, the tendon envelops the medial (tibial) and lateral (fibular) sesamoids. The medial

sesamoid is typically larger than the lateral sesamoid and sits more distal. The first metatarsal bears plantar load through these 2 sesamoids and their respective articulations. The sesamoids also function to increase the lever arm of the FHB and, indirectly, the flexor hallucis longus to mechanically augment flexion (push off) strength at the MTP joint.<sup>2</sup> The flexor hallucis longus tendon courses plantar to the metatarsal head, between the sesamoids in a separate sheath. At the level of the sesamoids, the abductor hallucis and adductor hallucis tendons conjoin with the medial and lateral heads of the FHB, respectively.

In normal gait, the capsular ligamentous complex of the hallux MTP joint must withstand 40% to 60% of body weight.<sup>19</sup> This can increase to 2 to 3 times body weight in normal athletic activity and can reach as much as 8 times body weight with a running jump.<sup>15</sup> The capsular ligamentous complex of the hallux MTP joint is a stout, strong soft tissue complex that is critical to the function of an athlete.

### MECHANISM OF INJURY

A turf toe injury typically occurs when an axial load is delivered to a foot in a fixed equinus position at the ankle with the great toe in extension at the MTP joint. The load drives the hallux MTP joint into hyperextension, which leads to attenuation or disruption of the capsular ligamentous complex supporting the joint (Figure 3). This most frequently happens in football when a foot is fixed to the ground, with the heel elevated, and a player lands on the back of the foot, causing

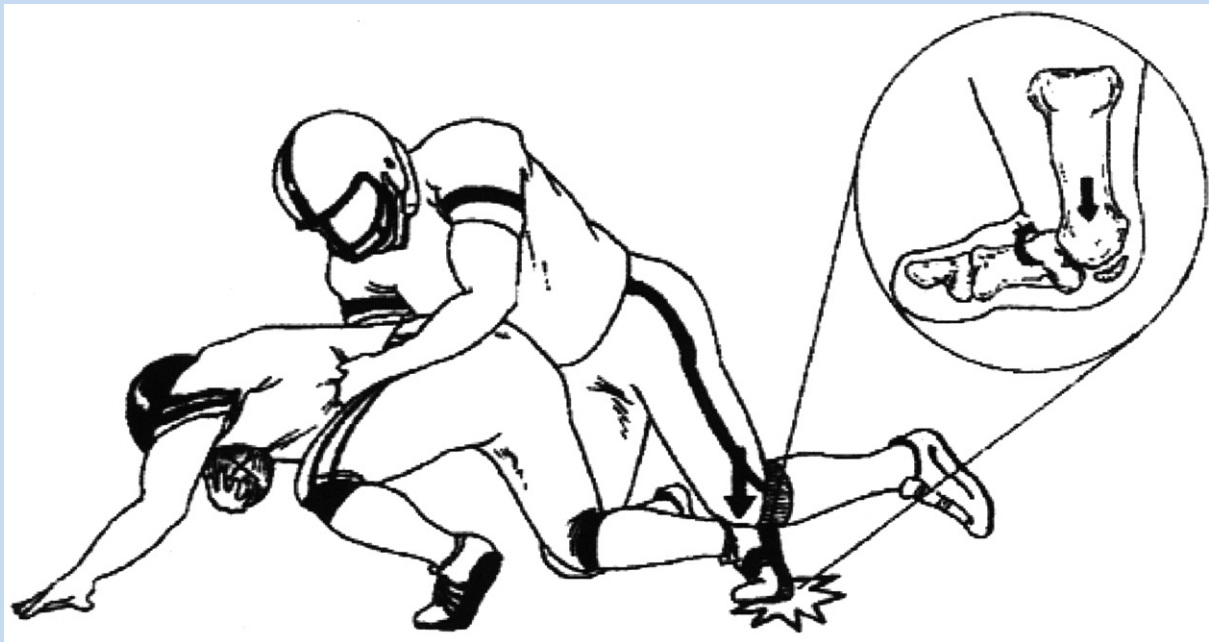


Figure 3. Typical mechanism of injury for turf toe—foot in fixed equinus with axially directed load.

Courtesy of Michael W. Bowman, MD. Copyright 1996.

Table 1. Summary of turf toe grading and treatment.<sup>a</sup>

Grade	Description/Findings	Treatment	Return to Play
I	Attenuation of plantar structures Localized swelling Minimal ecchymosis	Symptomatic	Return as tolerated
II	Partial tear of plantar structures Moderate swelling Restricted motion due to pain	Walking boot Crutches as needed	Up to 2 weeks May need taping on return to play
III	Complete disruption of plantar structures Significant swelling/ ecchymosis Hallux flexion weakness Frank instability of hallux MTP	Long-term immobilization in boot or cast <i>OR</i> Surgical reconstruction	10 to 16 weeks depending on sport and position Likely to need taping on return to play

<sup>a</sup>MTP, metatarsophalangeal. Adapted from Anderson RB, Shauen SB. Great-toe disorders. In: Porter DA, Schon LC, eds. *Baxter's The Foot and Ankle in Sport*. 2nd ed. Philadelphia, PA: Elsevier Health Sciences; 2007:411-433.

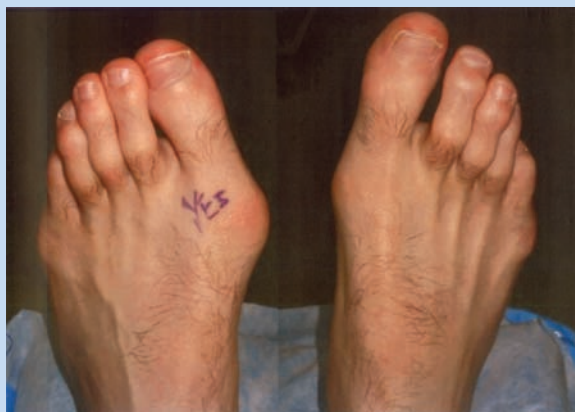

Figure 4. A traumatic hallux valgus deformity (left) compared to a normal hallux alignment (right). Used with permission from McCormick JJ, Anderson RB. Rehabilitation following turf toe injury and plantar plate repair. *Clin Sports Med*. 2010;29:313-323.

injury to the hallux MTP joint.<sup>14</sup> A spectrum of injuries can occur, ranging from a sprain of the plantar structures to frank dorsal dislocation of the joint with complete disruption of the plantar structures. Injury can also occur to the articular surface of the MTP joint as the proximal phalanx impacts or shears across the articular surface of the metatarsal head.<sup>16</sup>

Depending on the position of the hallux at the time of injury, variations from the classic hyperextension injury can occur. If the force vector on the great toe at time of impact has a

medial component to it, greater injury occurs to the medial and plantar-medial ligamentous structures, as well as the tibial sesamoid complex. As a result, there is a relative contracture of the lateral structures (lateral sesamoid complex and adductor hallucis), leading to a traumatic hallux valgus and bunion deformity (Figure 4).<sup>9,10,21</sup>

Turf toe injury was classically described in football players participating on artificial surfaces.<sup>7</sup> Recently, there has been an apparent increase in the incidence of turf toe injuries. One component may be greater awareness of the injury and earlier identification by athletic trainers and physicians. Other contributing components may be the evolution of shoe wear to lightweight, flexible shoes with little support and the increased use of artificial surfaces. A study of high school athletes comparing injuries on modern artificial turf to injuries on natural grass showed similarities in injury patterns.<sup>13</sup>

## EVALUATION

Turf toe injury can be subtle. The most important component to proper diagnosis is maintaining a high index of suspicion in a patient presenting with first MTP joint pain and swelling, particularly after an acute incident. The injury can range from a mild sprain of the plantar ligamentous complex to complete disruption of these soft tissue structures. Defining an appropriate treatment algorithm and establishing expectations for the athlete regarding return to play can occur only with appropriate evaluation (Table 1). An athlete with a low-grade

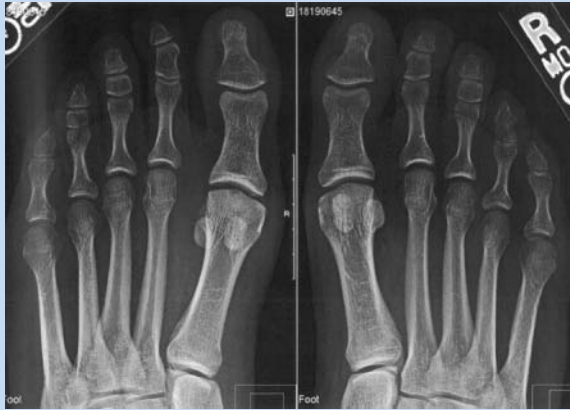

Figure 5. Anteroposterior radiograph of the feet demonstrating sesamoid retraction (left), compared with normal sesamoid position (right).

Used with permission from McCormick JJ, Anderson RB. Rehabilitation following turf toe injury and plantar plate repair. *Clin Sports Med.* 2010;29:313-323.

injury may not miss practice or game play, whereas an athlete with a high-grade injury may need surgical repair.

### History and Physical

Assessment begins with observation of the great toe for swelling, ecchymosis, or gross malalignment, as well as palpation of the collateral ligaments, dorsal capsule, and plantar sesamoid complex. Point tenderness can be critical to diagnosis, treatment, and prognosis. Localizing pain proximal to the sesamoids suggests a strain of the FHB musculotendinous junction and not an unstable turf toe injury, which typically occurs distal to the sesamoids.

The hallux MTP joint should be trialed through range of motion maneuvers to evaluate stability. Varus and valgus stress should be applied to evaluate the collateral ligaments. A dorsoplantar drawer test can evaluate the competence of the plantar plate. Active flexion and extension at the MTP and interphalangeal joints should be performed to assess the extensor and flexor tendons and plantar plate. A decrease in active flexion strength, as compared to the

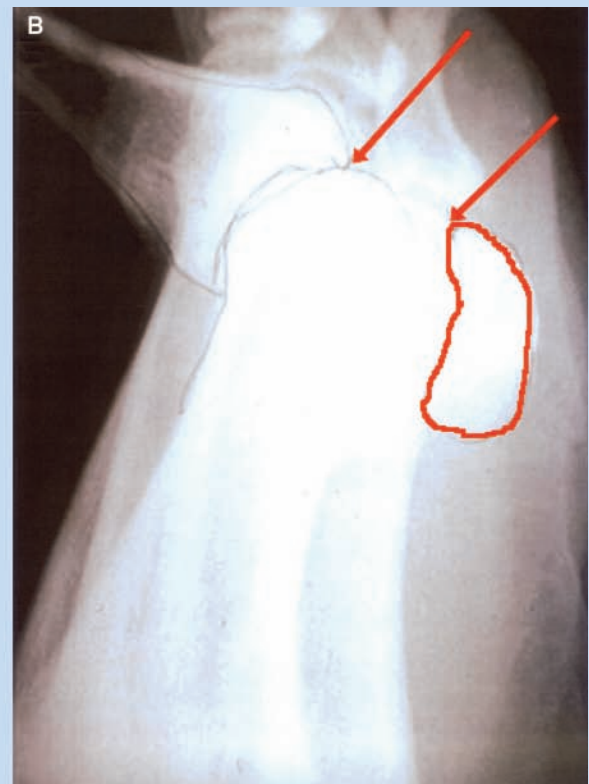
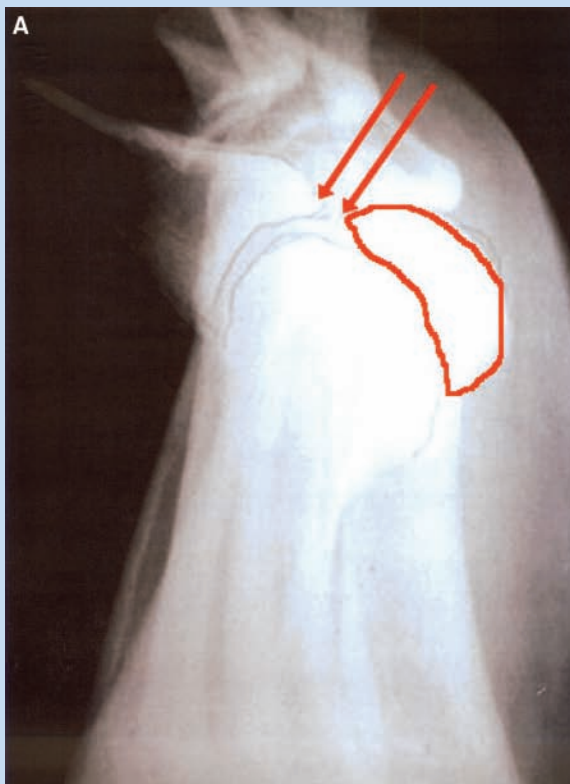

Figure 6. Dorsiflexion lateral view. Sesamoid is encircled in each figure. Red arrows demonstrate distance between sesamoid and proximal phalanx with the toe in a dorsiflexed position. A, uninjured plantar plate complex with appropriate sesamoid tracking; B, injured plantar plate complex with lack of sesamoid tracking—notice increased distance between arrows.

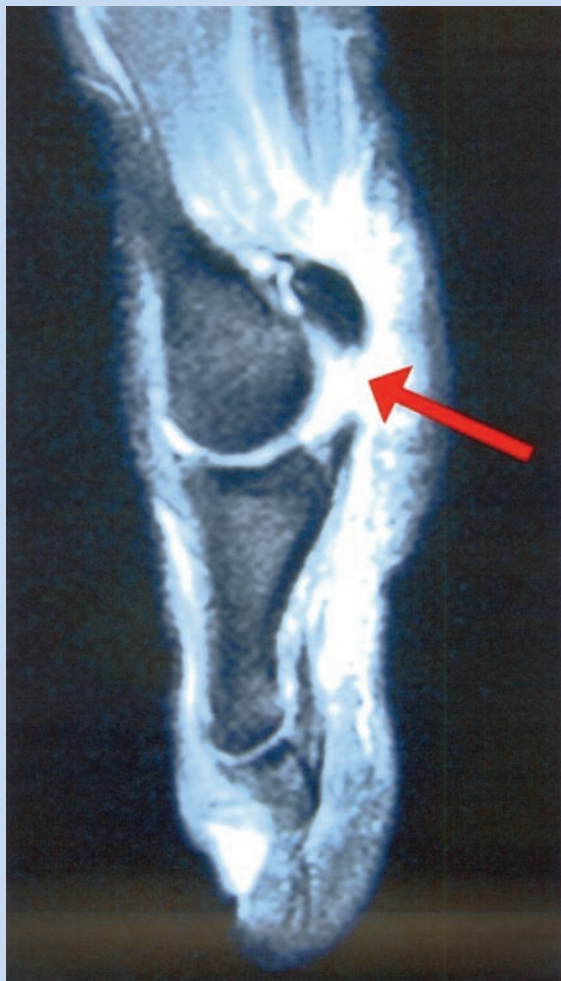

Figure 7. T2 sagittal SPIR (spectral presaturation by inversion recovery) sequence magnetic resonance imaging image of the hallux metatarsophalangeal joint. Red arrow demonstrates rupture of the capsular ligamentous complex just distal to the tibial sesamoid bone.

Used with permission from McCormick JJ, Anderson RB. The great toe: failed turf toe, chronic turf toe, and complicated sesamoids injuries. *Foot Ankle Clin.* 2009;14(2):135-150.

contralateral side, might suggest a disruption of the FHB or plantar plate.

### Imaging

Standard weightbearing anteroposterior, lateral, and sesamoid axial radiographs should be obtained. The bony structures in the radiographs are usually normal. A small fleck of bone from the proximal phalanx or distal sesamoid may indicate a capsular disruption or avulsion. Comparison radiographs of the contralateral foot can confirm proper sesamoid location beneath the first metatarsal head. Patients with a plantar plate rupture will have proximal migration of one or both sesamoids (Figure 5).<sup>17</sup>

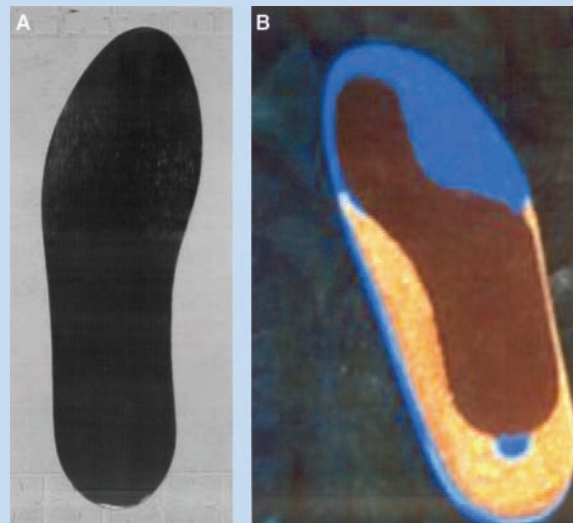


Figure 8. Orthotic options for turf toe injury: A, carbon-fiber turf toe plate\*; B, custom orthotic with Morton's extension. \*Used with permission from McCormick JJ, Anderson RB. Rehabilitation following turf toe injury and plantar plate repair. *Clin Sports Med.* 2010;29:313-323.

A forced dorsiflexion lateral view of the hallux MTP joint should be obtained if there is clinical suspicion of plantar plate injury. With complete disruption of the plantar plate, the sesamoids will not track distally with great toe extension, remaining beneath the metatarsal head (Figure 6). Fluoroscopy can demonstrate the inability of the sesamoids to track distally with extension at the MTP joint. With hallux MTP joint motion, sesamoid motion can be compared to the contralateral side. A lack of distal sesamoid excursion with toe extension suggests disruption of the plantar soft tissue structures.

Obtaining optimal radiographic detail of the MTP joint is important in assessing the extent of the injury to formulate a treatment plan and prognosis for the patient. Magnetic resonance imaging (MRI) is commonly used in the evaluation of turf toe injury, particularly in athletic patients<sup>8</sup> and when grade II or III injuries occur. T2-weighted images in multiple planes can be helpful to identify soft tissue disruption or articular injury, identifying even subtle injuries (Figure 7).<sup>20</sup>

## TREATMENT

### Nonoperative Treatment

The early stages of treatment are similar in all grades of injury. Rest, ice, compression, and elevation can be applied to help reduce initial pain and swelling. Anti-inflammatory medications can also be used to help relieve acute symptoms. Athletes may initially benefit from a walking boot or short leg cast with a toe spica extension in slight plantarflexion. This position of splinting can protect the hallux MTP joint from hyperextension while opposing the injured soft tissue structures at the plantar aspect

Table 2. Surgical indications for turf toe injury.<sup>a</sup>

Indications for Surgical Repair of Turf Toe Injury
Large capsular avulsion with unstable MTP joint
Diastasis of bipartite sesamoid
Diastasis of sesamoid fracture
Retraction of sesamoid
Traumatic hallux valgus deformity
Vertical instability (positive Lachman test result)
Loose body in MTP joint
Chondral injury in MTP joint
Failed conservative treatment

<sup>a</sup>MTP, metatarsophalangeal. From McCormick JJ, Anderson RB. The great toe: failed turf toe, chronic turf toe, and complicated sesamoids injuries. *Foot Ankle Clin.* 2009;14(2):135-150.

of the toe for healing. With this protection, the athlete may weightbear as tolerated. Taping the toe is not advised in the acute setting because it may compromise circulation to the toe.

Grade I injury is a stretching or attenuation of the plantar structures of the hallux MTP joint. This grade of injury usually allows return to athletic competition as tolerated, with little or no loss of playing time. After the acute phase of injury, the great toe will benefit from taping in a slightly plantarflexed position to limit motion and provide compression. The athlete should use a stiff-soled shoe with a turf toe plate insert or a custom orthotic with a Morton's extension to limit hallux motion (Figure 8). If the injury is more medially based and there is concern of a traumatic hallux valgus, a toe separator between the hallux and second toes can provide further support.

As early as 3 to 5 days after the injury, gentle range of motion can begin with passive plantarflexion to prevent sesamoid adhesions while protecting the injured and healing plantar soft tissues.<sup>12</sup> The patient should be carefully followed in these early stages of recovery because deformity can progress with athletic activity. Low-impact exercise, such as bicycling, elliptical training, and pool therapy, can be attempted with toe protection. Cortisone or anesthetic agents are not advised.

Grade II injury is partial rupture of the plantar capsular ligamentous complex. This grade of injury will typically result in loss of playing time of at least 2 weeks. Early gentle passive motion is allowed, if symptoms permit, along with low-impact exercises utilizing toe protection with a boot or taping. Once the toe can tolerate low-impact exercise, the athlete can progress to higher-impact activities (eg, jogging or running), followed by explosive or push-off activities (eg, cutting and jumping). The requirements

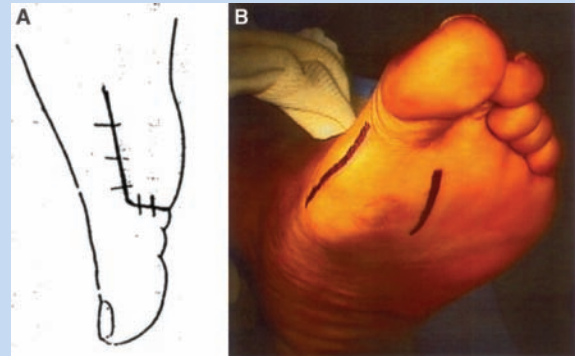


Figure 9. A, classic medial J incision\*; B, dual incision for medial and lateral access.†

\*Used with permission from McCormick JJ, Anderson RB.

Rehabilitation following turf toe injury and plantar plate repair. *Clin Sports Med.* 2010;29:313-323.

†Used with permission from McCormick JJ, Anderson RB. The great toe: failed turf toe, chronic turf toe, and complicated sesamoids injuries. *Foot Ankle Clin.* 2009;14(2):135-150.

of an athlete's sport may also play a role in the progression of activities or return to play. Shoe wear should be adjusted to include the use of a turf toe plate or Morton's extension.

Grade III injury is complete rupture of the plantar capsular ligamentous complex. This degree of injury may require 8 weeks of recovery and immobilization. The hallux MTP should have 50° to 60° of painless passive dorsiflexion before running or explosive activities are attempted.<sup>12</sup> It may take up to 6 months for complete resolution of symptoms.

### Surgical Treatment

The decision to proceed with operative repair can be difficult; it is one based on specific criteria (Table 2). The goal of surgery is to restore the normal, stable anatomy of the hallux MTP joint. In complete plantar plate ruptures, a dual-incision technique allows access to the medial and lateral aspects of the plantar capsular ligamentous complex (Figures 9 and 10).<sup>11</sup>

The capsular disruption typically occurs distal to the sesamoid bones. If this is the only injury, the plantar soft tissue structures can be primarily repaired end to end with nonabsorbable sutures. Repair of the medial and lateral soft tissue structures should avoid injury to the flexor hallucis longus tendon. If a traumatic hallux valgus occurs with primarily medial soft tissue injury, an adductor tenotomy is performed percutaneously to balance the hallux MTP joint. In this scenario, the medial eminence may also be resected to allow a capsulodesis, as with a standard bunion procedure.

If the sesamoid is fractured or fragmented, one pole of the sesamoid should be preserved, if possible. A smaller distal pole is amenable to excision. A drill hole in the larger proximal pole may allow soft tissue repair to the sesamoid bone. If complete

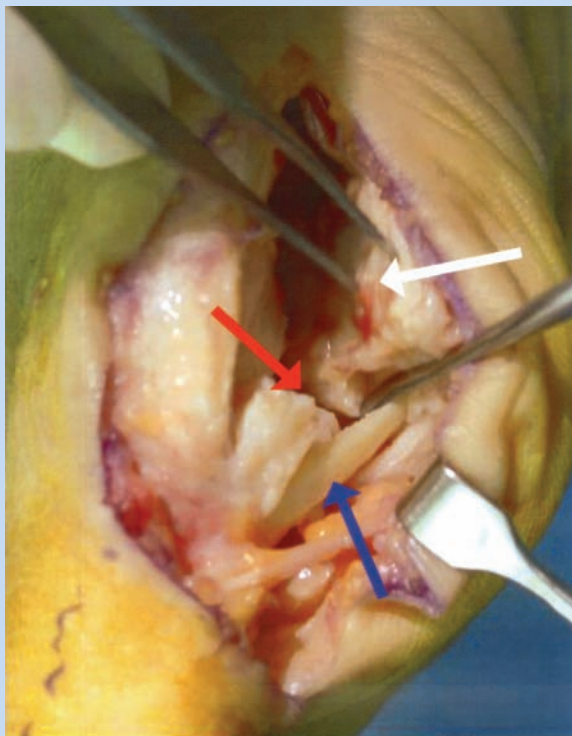


Figure 10. Medial view of hallux metatarsophalangeal joint prior to repair. Blue arrow identifies flexor hallucis longus tendon. White arrow identifies medial sesamoid. Red arrow identifies plantar plate rupture distal to sesamoid.

sesamoidectomy is necessary, then the abductor hallucis tendon should be transferred into the soft tissue defect of the excised sesamoid to provide collagen to the site of injury and allow the abductor to function as a plantar restraint to dorsiflexion while augmenting flexion at the MTP joint (Figure 11).

### Postoperative Management

Immediately after surgical repair, the foot is placed into a toe spica splint to keep the repaired toe in plantarflexion and nonweightbearing for 4 weeks. The athlete can begin gentle passive range of motion exercise at 5 to 7 days postoperatively to minimize stiffness at the sesamoid-metatarsal articulation. Excessive dorsiflexion and active range of motion should be avoided to protect the repair. At the 4-week mark, the athlete may begin protected weightbearing in a boot and begin active motion exercise. Pool therapy can begin with gentle weightbearing and gait exercise.

At 8 weeks postoperatively, a stiff-soled shoe with a turf toe plate is used to prevent hyperextension at the hallux MTP joint, and weightbearing is advanced as tolerated with protective taping and shoe wear. As symptoms allow,

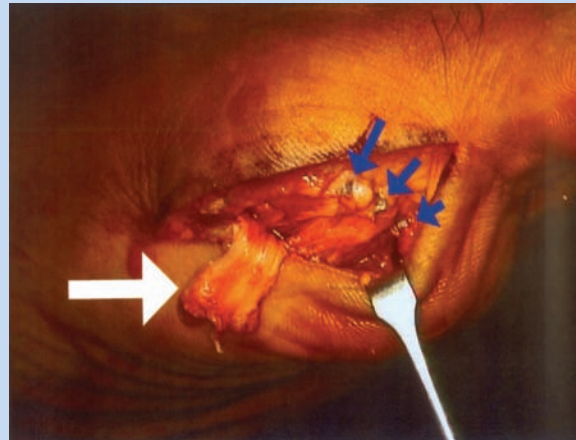


Figure 11. Medial view of a repaired capsular disruption. Blue arrows identify nonabsorbable sutures tied to repair the soft tissues. White arrow identifies the abductor hallucis tendon before transfer.

Used with permission from McCormick JJ, Anderson RB. Rehabilitation following turf toe injury and plantar plate repair. *Clin Sports Med.* 2010;29:313-323.

progression can occur from low-impact activities (eg, bicycling and pool therapy) to medium-impact activities (eg, elliptical training). Contact athletes often take 16 weeks to return to full activity but may require 12 months for full recovery.

### Outcomes

A few articles in the literature describe outcomes from management of turf toe injuries. Coker et al cited 9 athletes with hyperextension injuries to their first MTP joints resulting in long-term joint stiffness and pain with athletic activity.<sup>7</sup> Clanton reported on 20 patients with 5-year follow-ups: 50% described persisting symptoms of pain and stiffness at the hallux MTP joint.<sup>5</sup> Brophy et al measured hallux MTP range of motion after recovery from turf toe injury, reporting a statistically significant decrease in dorsiflexion, compared to uninjured toes.<sup>4</sup>

Anderson described 19 high-level competitive athletes with disabling turf toe injuries<sup>1</sup>: 9 required operative repair, and all but 2 returned to full athletic participation with restoration of plantar stability. No complications from surgery were reported.

### CONCLUSION

Despite an increasing awareness of turf toe injury, confusion still exists regarding the anatomy, mechanism, diagnosis, and treatment of this hyperextension injury to the hallux MTP joint. Careful management should allow successful return to play at the preinjury level of participation.

## REFERENCES

1. Anderson RB. Turf toe injuries of the hallux metatarsophalangeal joint. *Tech Foot Ankle Surg.* 2002;1(2):102-111.
2. Aper RL, Saltzman CL, Brown TD. The effect of hallux sesamoid excision on the flexor hallucis longus moment arm. *Clin Orthop Relat Res.* 1996;325:209-217.
3. Bowers KD Jr, Martin RB. Turf-toe: a shoe-surface related football injury. *Med Sci Sports.* 1976;8(2):81-83.
4. Brophy RH, Gamradt SC, Ellis SJ, et al. Effect of turf toe on foot contact pressures in professional American football players. *Foot Ankle Int.* 2009;30(5):405-409.
5. Clanton TO, Butler JE, Eggert A. Injuries to the metatarsophalangeal joints in athletes. *Foot Ankle.* 1986;7(3):162-176.
6. Coker TP, Arnold JA, Weber DL. Traumatic lesions of the metatarsophalangeal joint of the great toe in athletes. *J Ark Med Soc.* 1978;74(8):309-317.
7. Coker TP, Arnold JA, Weber DL. Traumatic lesions of the metatarsophalangeal joint of the great toe in athletes. *Am J Sports Med.* 1978;6(6):326-334.
8. Crain JM, Phanco JP, Stidham K. MR imaging of turf toe. *Magn Reson Imaging Clin N Am.* 2008;16(1):93-103.
9. Douglas DP, Davidson DM, Robinson JE, et al. Rupture of the medial collateral ligament of the first metatarsophalangeal joint in a professional soccer player. *J Foot Ankle Surg.* 1997;36(5):388-390.
10. Fabeck LG, Zekhnini C, Farrok D, et al. Traumatic hallux valgus following rupture of the medial collateral ligament of the first metatarsophalangeal joint: a case report. *J Foot Ankle Surg.* 2002;41(2):125-128.
11. McCormick JJ, Anderson RB. The great toe: failed turf toe, chronic turf toe, and complicated sesamoids injuries. *Foot Ankle Clin.* 2009;14(2):135-150.
12. McCormick JJ, Anderson RB. Rehabilitation following turf toe injury and plantar plate repair. *Clin Sports Med.* 2010;29:313-323.
13. Meyers MC, Barnhill BS. Incidence, causes, and severity of high school football injuries on FieldTurf versus natural grass: a 5-year prospective study. *Am J Sports Med.* 2004;32(7):1626-1638.
14. Mullen JE, O'Malley MJ. Sprains: residual instability of subtalar, Lisfranc joints, and turf toe. *Clin Sports Med.* 2004;23:97-121.
15. Nigg BM. Biomechanical aspects of running. In: Nigg BM, ed. *Biomechanics of Running Shoes.* Champaign, IL: Human Kinetics; 1986:1-25.
16. Nihal A, Trepman E, Nag D. First ray disorders in athletes. *Sports Med Arthrosc.* 2009;17(3):160-166.
17. Prieskorn D, Graves SC, Smith RA. Morphometric analysis of the plantar plate apparatus of the first metatarsophalangeal joint. *Foot Ankle.* 1993;14(4):204-207.
18. Rodeo SA, O'Brien S, Warren RF, et al. Turf-toe: an analysis of metatarsophalangeal joint sprains in professional football players. *Am J Sports Med.* 1990;18(3):280-285.
19. Stokes IA, Hutton WC, Stott JR, et al. Forces under the hallux valgus foot before and after surgery. *Clin Orthop Relat Res.* 1979;142:64-72.
20. Tewes DP, Fischer DA, Fritts HM, et al. MRI findings of acute turf toe: a case report and review of anatomy. *Clin Orthop Relat Res.* 1994;304:200-203.
21. Watson TS, Anderson RB, Davis WH. Periarticular injuries to the hallux metatarsophalangeal joint in athletes. *Foot Ankle Clin.* 2000;5(3):687-713.

For reprints and permissions queries, please visit SAGE's Web site at <http://www.sagepub.com/journalsPermissions.nav>.