

Perforated Early Gastric Cancer: Uncommon and Easily Missed a Case Report and Review of Literature

Raymond Hon Giat Lim¹, Clifton Ming Tay², Benjamin Wong³,
Choon Seng Chong¹, Koji Kono^{1,2}, Jimmy Bok Yan So^{1,2}, and Asim Shabbir¹

¹Department of Surgery, Singapore National University Hospital, ²Yong Loo Lin School of Medicine, National University of Singapore, ³Department of Pathology, Singapore National University Hospital, Singapore

Gastric carcinoma rarely presents as a perforation, but when it does, is perceived as advanced disease. The majority of such perforations are Stage III/IV disease. A T1 gastric carcinoma has never been reported to perforate spontaneously in English literature. We present a 56 year-old Chinese male who presented with a perforated gastric ulcer. Intra-operatively, there was no suspicion of malignancy. At operation, an open omental patch repair was performed. Post-operative endoscopy revealed a macroscopic Type 0~III tumour and from the ulcer edge biopsy was reported as adenocarcinoma. Subsequently, the patient underwent open subtotal gastrectomy and formal D2 lymphadenectomy. The final histopathology report confirms T1b NO disease. The occurrence of a perforated early gastric cancer re-emphasises the need for vigilance, including intra-operative frozen section and/or biopsy, as well as routine post-operative endoscopy for all patients.

Key Words: Stomach neoplasms; Early gastric cancer; Rupture spontaneous; Peritonitis; General surgery

Introduction

Gastric carcinoma rarely presents with perforation. The reported incidence of perforation of gastric cancer is less than 5%.¹⁻⁵ Amongst these patients, the majority have advanced disease, with 64% to 88% presenting with Stage III/IV disease.^{2,3} Conversely, a significant proportion of gastric perforations—10~16%, are secondary to gastric cancer.²

The incidence of perforated gastric carcinoma being Stage I/II disease is low, reported at 0~36%.^{1-3,5} Perforated gastric cancer is usually associated with advanced disease and hence carries poorer prognosis. Our literature search revealed a single isolated review of 46

cases on perforated early gastric cancer in Japanese literature.⁴ However, perforated T1 gastric carcinoma has never been reported in the English literature.

We treated a case of pT1bN0M0 early gastric cancer, macroscopically Type 0~III that initially presented with perforation, prompting the report of this case.

Case Report

A 56-year-old Chinese gentleman with history of hypertension and gastritis over the past two months presented at our emergency department with an acute onset of epigastric pain. An erect chest X-ray followed by computed tomography of the abdomen and pelvis (CTAP) revealed pneumoperitoneum secondary to a perforated gastric ulcer along the lesser curve (Fig. 1).

The patient underwent an uneventful emergency open omental patch repair. Intra-operatively, there were no features to suggest malignancy. Frozen sections were not available after office hours.

Correspondence to: Asim Shabbir
Department of Surgery, National University Hospital, Singapore NUHS Tower Block, Level 8, 1E Kent Ridge Road, Singapore 119228
Tel: +65-6772-4240, Fax: +65-6777-8427
E-mail: cfsasim@nus.edu.sg
Received September 18, 2012
Revised November 15, 2012
Accepted December 1, 2012

© This is an open-access article distributed under the terms of the Creative Commons Attribution Non-Commercial License (<http://creativecommons.org/licenses/by-nc/3.0>) which permits unrestricted noncommercial use, distribution, and reproduction in any medium, provided the original work is properly cited.

Intra-operatively, tissue biopsies were obtained from the edge of perforation. These were inconclusive with ulcer bed debris and granulation tissue with no malignant cells seen.

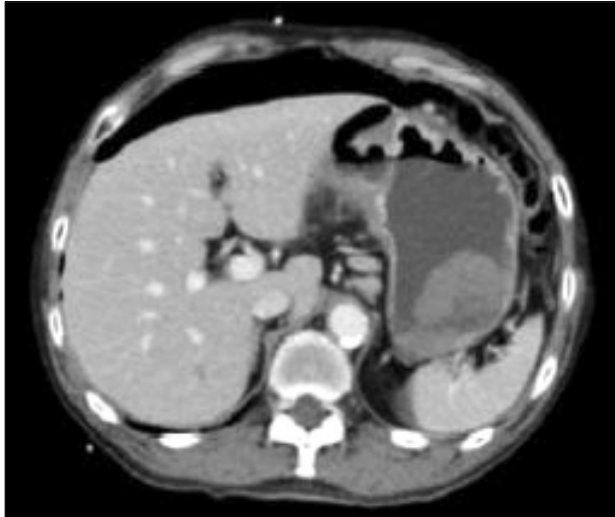


Fig. 1. Computed tomography of Abdomen and Pelvis, showing gross pneumoperitoneum and likely site of perforation.

The patient had an uneventful postoperative recovery. Six weeks post omental patch repair, we performed an oesophagogastroduodenoscopy (OGD) for routine evaluation. An incisura ulcer was seen with no surrounding gastric wall thickening (Fig. 2A). The ulcer edge was biopsied, which revealed moderately differentiated adenocarcinoma. This corresponded to macroscopic Type 0~III appearance of early gastric cancer (Fig. 2B).

Staging CTAP performed showed neither lymphadenopathy nor distant metastases. We hence proceeded to perform an open distal subtotal gastrectomy with formal D2 lymphadenectomy and Billroth II reconstruction (gastrojejunostomy). No peritoneal metastasis was noted during the surgery. Peritoneal washing cytology was not performed at second operation due to extensive adhesions.

The patient had an uneventful post-operative recovery, and was discharged well 5 days after surgery. Outpatient follow-up at 1 week and 3 months were unremarkable. At 6 months post-operation, the patient had recovered back to his pre-morbid status and was taking well orally. He remains asymptomatic with no sign suggestive of a recurrence.

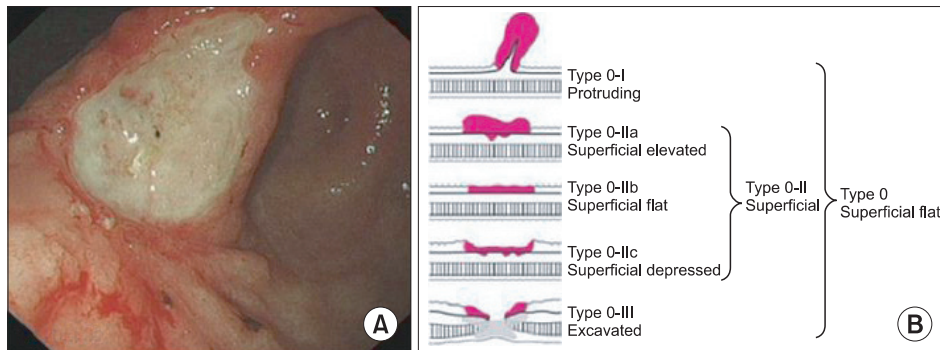


Fig. 2. (A) An oesophagogastroduodenoscopy 6 weeks postoperative showing tumour along the incisura. (B) Japanese sub-classification of type 0 gastric tumours.

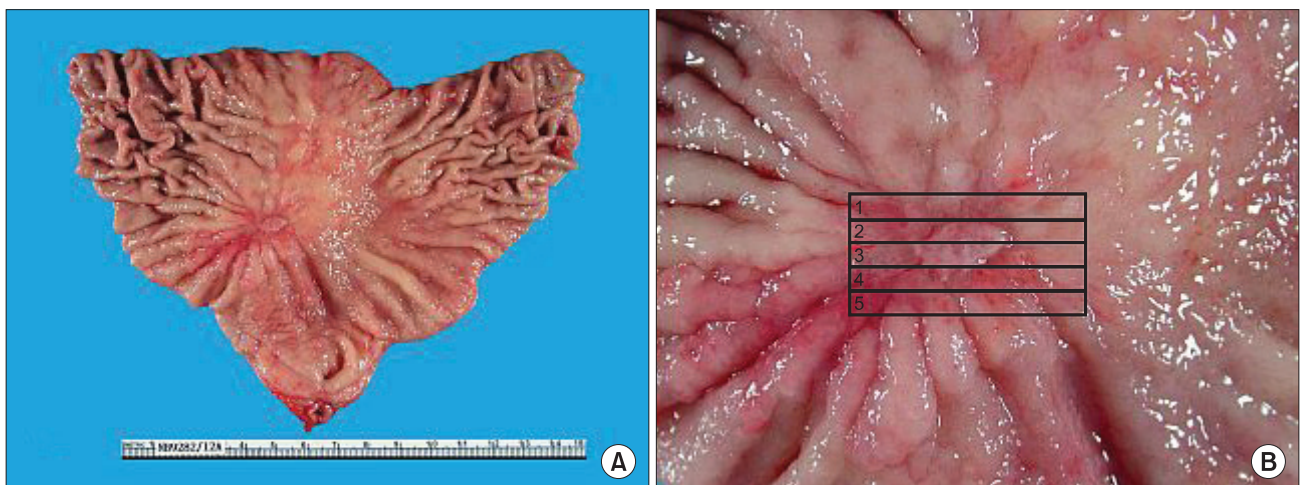


Fig. 3. (A) Gross surgical specimen of ulcer/tumour. (B) Close-up view of ulcer and histological mapping of sampled specimen.

Histological results

Histological examination of the resection specimen were taken from various sites (Fig. 3A). The entire ulcer was submitted in five sections (Fig. 3B), each 3 mm thick.

Microscopic examination of the resection specimen revealed a T1bN0M0 moderately differentiated adenocarcinoma of tubular/intestinal type (Fig. 4). The majority of the tumour was confined to the mucosa, with focal invasion of the submucosa (Fig. 5A) but no involvement of the muscularis propria (Fig. 5B). There was also attenuation and focal loss of the muscularis propria underlying the tumour site, with replacement by fibrosis that extended into the submucosa and subserosa, in keeping with a previous perforation. The serosal surface at this site showed adherent connective tissue

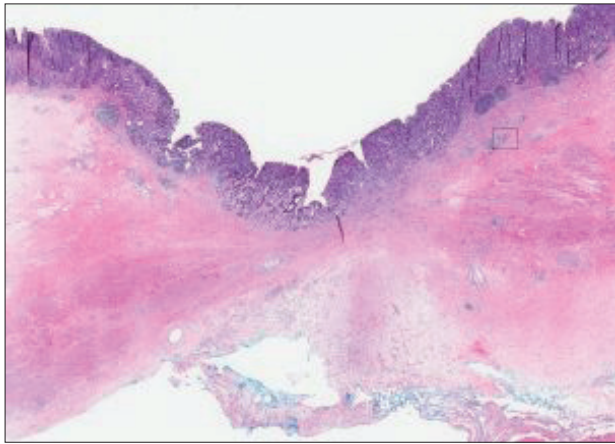


Fig. 4. Low-magnification picture of the resection specimen, with the submucosal tumour highlighted (H&E, $\times 20$).

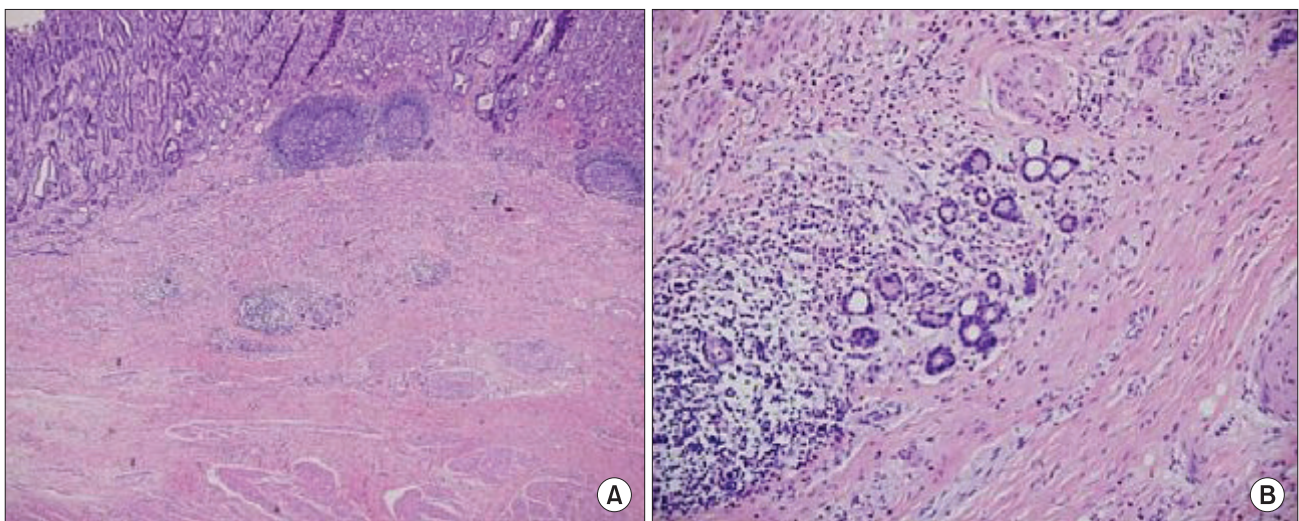


Fig. 5. (A) Microscopic histology showing focal submucosal invasion, with no tumour cells seen in muscularis propria (H&E, $\times 40$). (B) Magnified view showing tumour cells limited to submucosal layer (H&E, $\times 200$).

with a focal foreign-body reaction to suture material, consistent with the previously applied omental patch. The proximal and distal resection margins, as well as the serosal surface, were free of tumour. A total of 48 lymph nodes were sampled from different stations. All lymph nodes showed no evidence of malignancy. The presence of such a rare diagnosis mandated a review of the sampling methods. The histological methods were reviewed and the diagnosis confirmed at a multi-disciplinary meeting, before making the diagnosis of a perforated early gastric cancer (EGC), TNM stage pT1b N0, Type 0~III (also known as EGC Type III).

Discussion

The occurrence of a perforated EGC is rare, therefore making it difficult to understand the pathogenesis of such cases. The Japanese Gastric Cancer Association had previously published a classification of EGC. The Type 0~III EGC (EGC Type III) deserves special attention with reference to our case.⁶ An excavated gastric ulcer type has been known to harbour malignancy at its edges, and the depth of excavation makes the ulcer prone to perforation, as has happened in our patient. The pathologist reported a perforated pT1b EGC, and retrospective morphological correlation revealed a macroscopic Type 0~III EGC with an excavated ulcer. Ischemia and infection has also been reported to surround gastric malignancy, and has been hypothesised as a possible explanation for perforation of EGC.⁴

We wish to highlight the following with this case report.

Firstly, gastric cancer perforation may not always represent

advanced or incurable disease. As seen in this case and in other case series, the perforated gastric cancer can still be in stage I/II/III. When treated appropriately with a curative intent, survival and prognosis is similar to those operated in an elective setting.⁷⁻¹⁰ The only factor influencing long-term survival in either setting is the underlying stage of malignancy.^{1,2,10}

Secondly, in the emergent setting of a perforated gastric cancer, the pre-operative diagnosis is often unavailable. Inflammation and fibrosis can also mimic malignancy, thus making an accurate intra-operative diagnosis even more challenging. The surgeon should hence consider the wisdom of a stage-appropriate oncological clearance on table, in a contaminated field. This must be done without compromising the stability of the patient. The alternative option of a two-staged procedure exists, performing a patch repair, then subsequently, a formal resection in an elective setting, with the benefit of a proper staging. Nonetheless, such an approach may have its own disadvantages—post-operative adhesions from the initial surgery, fitness of the patient in tolerating another extensive operation and delay in the initiation of chemo-radiotherapy should there be any complications arising from the operation.¹⁰

There have been a few reports in the literature of surgical results of perforated gastric carcinoma. In a meta-analysis from the Japanese literature evaluating 155 patients with perforated gastric cancer, emergent gastrectomy was performed 83 percent of the time, with a mortality rate of 7 percent.¹ Gertsch et al.⁵ also reported a case series of 34 patients who had emergency surgery (88% resection rate), with an operative mortality rate of 16 percent. The overall 5-year survival of these patients reached 40 percent, and is related to the pathological stage of the disease.^{1,8,9}

Thirdly, the importance of proper sampling intra-operatively, as well as post-operative OGD must be emphasised. In our case report, malignancy was not suspected during the first surgery, and frozen section was not readily available after office hours in our centre. Wide excision of the ulcer is a possibility, but will result in a larger defect, often resulting in difficult closure and prolonging the surgery. A good representative biopsy of the ulcer edge will hence be ideal. Unfortunately, intra-operative biopsy in our patient only revealed granulation tissue, indicating a poor sample and could be an explanation for cancer being missed during the first surgery.

Malignancy was only discovered at a routine oesophagogastro-duodenoscopy performed six weeks post-omental patch repair, and the diagnosis of a gastric adenocarcinoma confirmed with biopsies from the ulcer edge. This re-emphasises the importance of performing a post-operative OGD in such patients.

Our patient underwent his second operation in an elective set-

ting, with a proper D2 lymphadenectomy. The diagnosis of a pT1bN0 gastric adenocarcinoma surprised many, but crucially, also represented a much better prognosis for our patient.

In summary, the occurrence of a perforated EGC re-emphasises the need for routine post-operative OGD, even in the absence of malignant features and negative histology. The immediate morbidity and mortality is related to the acute condition from septicaemia and perforation, whereas long-term mortality is likely to be related to the cancer stage itself.¹⁰

References

1. Adachi Y, Mori M, Maehara Y, Matsumata T, Okudaira Y, Sugimachi K. Surgical results of perforated gastric carcinoma: an analysis of 155 Japanese patients. *Am J Gastroenterol* 1997;92:516-518.
2. Roviello F, Rossi S, Marrelli D, De Manzoni G, Pedrazzani C, Morgagni P, et al. Perforated gastric carcinoma: a report of 10 cases and review of the literature. *World J Surg Oncol* 2006;4:19.
3. Mahar AL, Brar SS, Coburn NG, Law C, Helyer LK. Surgical management of gastric perforation in the setting of gastric cancer. *Gastric Cancer* 2012;15 Suppl 1:S146-152.
4. Kitakado Y, Tanigawa N, Muraoka R. A case report of perforated early gastric cancer. *Nihon Geka Hokan* 1997;66:86-90.
5. Gertsch P, Yip SK, Chow LW, Lauder IJ. Free perforation of gastric carcinoma. Results of surgical treatment. *Arch Surg* 1995;130:177-181.
6. Japanese Gastric Cancer Association. Japanese classification of gastric carcinoma: 3rd English edition. *Gastric Cancer* 2011;14:101-112.
7. So JB, Yam A, Cheah WK, Kum CK, Goh PM. Risk factors related to operative mortality and morbidity in patients undergoing emergency gastrectomy. *Br J Surg* 2000;87:1702-1707.
8. Miura T, Ishii T, Shimoyama T, Hirano T, Tomita M. Surgical treatment of perforated gastric cancer. *Dig Surg* 1985;2:200-204.
9. Cuschieri A, Weeden S, Fielding J, Banciewicz J, Craven J, Joypaul V, et al. Patient survival after D1 and D2 resections for gastric cancer: long-term results of the MRC randomized surgical trial. Surgical Co-operative Group. *Br J Cancer* 1999;79:1522-1530.
10. Tan KK, Quek TJ, Wong N, Li KK, Lim KH. Emergency surgery for perforated gastric malignancy: an institution's experience and review of the literature. *J Gastrointest Oncol* 2011;2:13-18.