



Elsevier has created a [Monkeypox Information Center](#) in response to the declared public health emergency of international concern, with free information in English on the monkeypox virus. The Monkeypox Information Center is hosted on Elsevier Connect, the company's public news and information website.

Elsevier hereby grants permission to make all its monkeypox related research that is available on the Monkeypox Information Center - including this research content - immediately available in publicly funded repositories, with rights for unrestricted research re-use and analyses in any form or by any means with acknowledgement of the original source. These permissions are granted for free by Elsevier for as long as the Monkeypox Information Center remains active.

Available online at [www.sciencedirect.com](http://www.sciencedirect.com)

ScienceDirect

journal homepage: [www.jfma-online.com](http://www.jfma-online.com)

## Case Report

# The first imported case of monkeypox in Taiwan

Shao-Tsung Huang<sup>a</sup>, Ying-Hsun Wu<sup>b</sup>, Hsi-Hsun Lin<sup>c,d,e</sup>,  
Jyh Yuan Yang<sup>f</sup>, Pei-Yu Hsieh<sup>f</sup>, Szu-Ju Chiang<sup>g</sup>,  
Shang-Pin Wang<sup>g</sup>, Ya-Han Chan<sup>a</sup>, Li-Fen Lin<sup>h</sup>, Yueh-Ju Chen<sup>i</sup>,  
Hung-Chin Tsai<sup>e,h,i,j</sup>, Yao-Shen Chen<sup>e,i,j</sup>,  
Susan Shin-Jung Lee<sup>e,i,j,\*</sup>

<sup>a</sup> Division of Infectious Diseases, Chest Hospital, Ministry of Health and Welfare, Tainan, Taiwan

<sup>b</sup> Division of Internal Medicine, Chest Hospital, Ministry of Health and Welfare, Tainan, Taiwan

<sup>c</sup> Department of Medical Education and Research, Kaohsiung Veterans General Hospital, Kaohsiung, Taiwan

<sup>d</sup> Institute of Clinical Medicine, National Yang-Ming Chiao Tung University, Taipei, Taiwan

<sup>e</sup> School of Medicine, College of Medicine, National Sun Yat-sen University, Kaohsiung, Taiwan

<sup>f</sup> Center for Diagnostics and Vaccine Development, Centers for Disease Control, Taipei, Taiwan

<sup>g</sup> Division of Nursing, Chest Hospital, Ministry of Health and Welfare, Tainan, Taiwan

<sup>h</sup> Division of Infectious Diseases, Department of Internal Medicine, Kaohsiung Veterans General Hospital, Kaohsiung, Taiwan

<sup>i</sup> Department of Infection Control, Kaohsiung Veterans General Hospital, Kaohsiung, Taiwan

<sup>j</sup> Faculty of Medicine, School of Medicine, National Yang-Ming Chiao Tung University, Taipei, Taiwan

Received 14 July 2022; received in revised form 21 August 2022; accepted 22 August 2022

**KEYWORDS**

Monkeypox;  
Taiwan;  
West African clade

**Abstract** The first imported case of monkeypox in Taiwan was diagnosed in an Asian man with HIV-1 infection and asymptomatic COVID-19, returning from Germany. Atypical presentations included asynchronous skin lesions, anogenital lesions and prominent inguinal lymphadenopathy. Whole genomic sequence alignment indicate that the Taiwan strain clustered together with human monkeypox virus West African clade B.1, currently circulating in Europe. Prompt diagnosis and infection control measures are crucial to mitigate the spread of monkeypox. Copyright © 2022, Formosan Medical Association. Published by Elsevier Taiwan LLC. This is an open access article under the CC BY-NC-ND license (<http://creativecommons.org/licenses/by-nc-nd/4.0/>).

\* Corresponding author. 386, Ta-chung 1st Rd., Kaohsiung 813, Taiwan.  
E-mail address: [ssjlee28@yahoo.com.tw](mailto:ssjlee28@yahoo.com.tw) (S.S.-J. Lee).

<https://doi.org/10.1016/j.jfma.2022.08.014>

0929-6646/Copyright © 2022, Formosan Medical Association. Published by Elsevier Taiwan LLC. This is an open access article under the CC BY-NC-ND license (<http://creativecommons.org/licenses/by-nc-nd/4.0/>).

Monkeypox is a viral zoonotic disease of global public health importance caused by monkeypox virus (MPXV), belonging to the Poxviridae family, *Orthopoxvirus* genus and first reported in Central and West Africa. It emerged recently to cause a global outbreak in 50 countries worldwide. Up to June 22, 2022, 3413 laboratory confirmed cases have been reported to the World Health Organization (W.H.O.), with 86% of the cases from the WHO European region, including the United Kingdom (793 cases), Germany (521), Spain (520), Portugal (317), France (277), the Netherlands (167) and others.<sup>1</sup> By Aug 19, 2022, the number of cases reported worldwide increased to 41,358 in 94 countries, including Taiwan (3), Singapore (15) and South Korea (1). Human-to-human transmission occurred among people in close physical contact with individuals who are symptomatic. Cases were mainly identified amongst men who have sex with men (MSM), without a travel history to endemic regions, who sought care in primary care and sexual health clinics. At the time our case was first diagnosed, only two cases has been identified in Asia, one in Singapore on June 20, and one from South Korea on June 22.<sup>1</sup> W.H.O. convened an Emergency Committee for monkeypox on June 23, 2022 and assessed that the current outbreak does not represent a public health emergency of international concern, but advised that intense efforts are required to control further spread. The Taiwan Centers for Disease Control (C.D.C.) placed out an alert to first-line doctors on May 22, 2022, and listed monkeypox as a category 2 notifiable communicable disease on June 23, 2022. We report the first imported case of monkeypox in Taiwan in an Asian man, with HIV infection and asymptomatic COVID-19, returning from Germany.

## The case

A 24-year-old Taiwanese man, an MSM with HIV infection, presented on June 22, 2022, to the telemedicine clinic in Kaohsiung Veterans General Hospital, Kaohsiung, Taiwan, with scattered vesicular and pustular skin lesions over his face, limbs, trunk, genital, perianal areas; tender, swollen, inguinal lymph nodes bilaterally; fever, sore throat, and myalgia for 2 days (Fig. 1A–K). He returned to Taiwan from Germany on June 16, 2022, where he had studied for 6 months. He was quarantined due to COVID-19 policies upon arrival. He received 3 doses of COVID-19 vaccination (AstraZeneca, AstraZeneca and BioNTech), with the last dose in Dec, 2021. He was diagnosed to have HIV infection in 2016, and maintained good viral suppression with anti-retroviral drugs, with a CD4 count of 517/mm<sup>3</sup>. His last sexual encounter was in early June, 2022. A travel history to a nonendemic country with monkeypox outbreak, and compatible clinical manifestations alerted the physician to monkeypox, who immediately notified the Taiwan C.D.C. The patient was referred to the emergency department, where a throat swab, vesicular fluid and serum sample were collected and sent to the reference laboratory of Taiwan C.D.C. for molecular detection of MPXV.

Viral DNA extraction with QIAamp MinElute virus spin (Qiagen, Hilden, Germany), and conventional polymerase chain reaction (PCR) was performed to detect Orthopox virus and MPXV based on previous publications.<sup>2,3</sup> Both

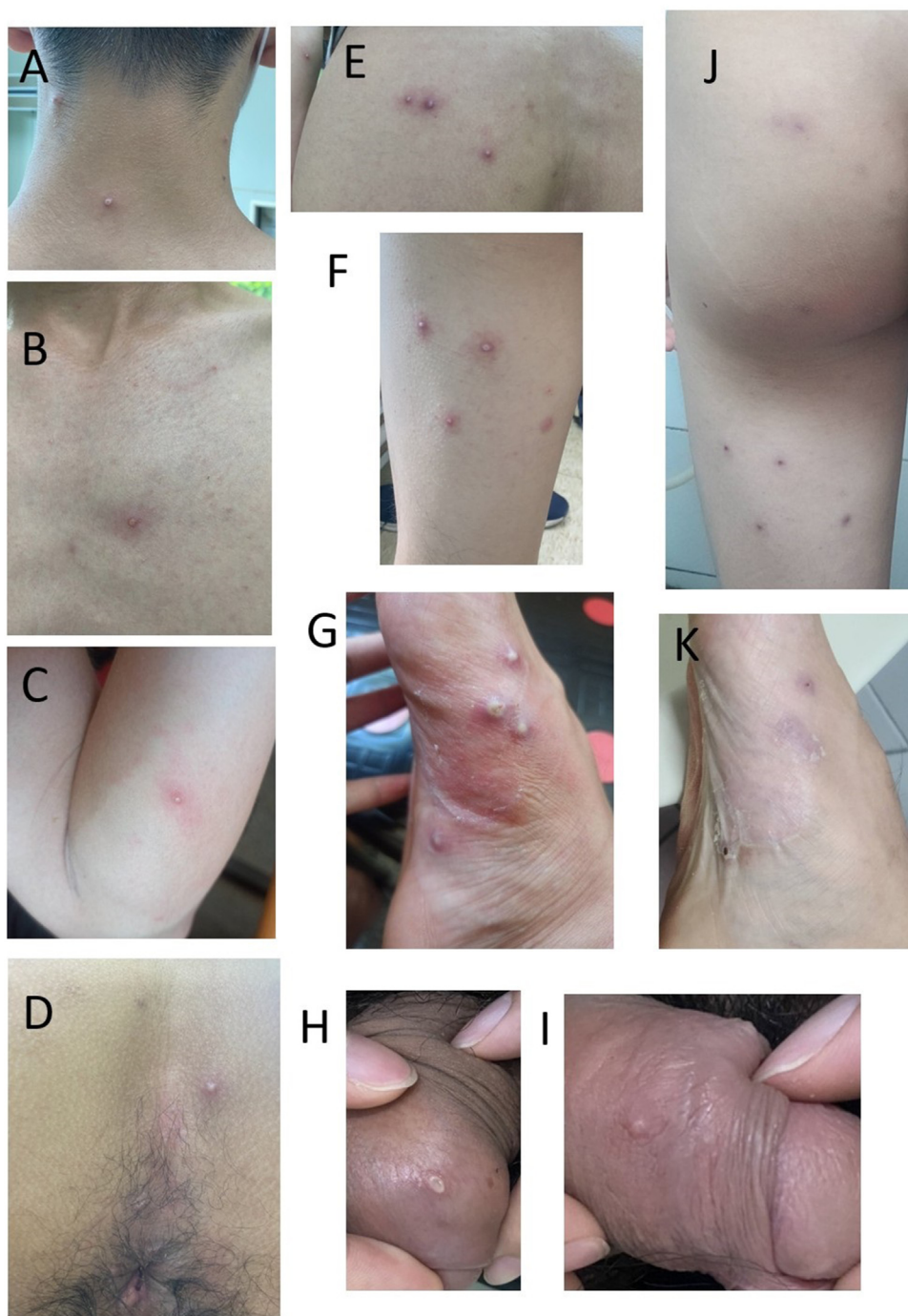
throat swab and vesicular fluid samples from the patient were positive by PCR using Orthopox virus and MPXV specific primers, and sequences of the PCR products were obtained. MPXV was further confirmed by Basic Local Alignment Search Tool (BLAST) of the obtained sequence with NCBI database. In addition, direct whole genomic sequencing on the vesicular fluid sample was performed by Oxford Nanopore MinION apparatus, obtaining 197,315 base pair sequence. The result indicates that the viral sequence shares higher similarity with the “West African” MPXV clade, including the European (Germany) and America lineages, rather than the “Central Africa” or Congo clade (Fig. 2). The accession numbers of Taiwan MPXV and other reference strains are listed in Fig. 2.<sup>4</sup>

The patient was admitted to a negative pressure room in a local teaching hospital on 23 June, 2022 for isolation. On admission, he had a temperature of 36 °C, and a pulse rate of 87/min. His blood pressure was 125/92 mmHg. Examination revealed scattered pustules and vesicles over his face, limbs, trunk, genital, and perianal areas (Fig. 1 A–K). Lymphadenopathy was palpated over his inguinal areas, bilaterally. His white blood cell count was 9530/μL with neutrophil 45.7%, hemoglobin 15.5 g/dL, platelet count  $276 \times 10^3/\mu\text{L}$ , and a C-reactive protein level was 2.75 mg/dL. His renal and liver functions were within normal limits. A chest radiograph was negative for pneumonia. A nasopharyngeal SARS-CoV-2 PCR was positive with a cycle threshold of 37, and turned negative 3 days later. After conservative management, the patient remained well and his skin lesions began crusting by day 6 of admission (day 9 after onset). The patient was discharged on July 14, 2022 (day 25 after onset) with complete healing of skin lesions.

## Discussion

Monkeypox has emerged as a global public health threat since May, 2022, causing the largest outbreak in non-endemic countries in decades.<sup>5</sup> The biggest known outbreak prior was in 2003, when 71 people in the United States were infected by pet prairie dogs that had picked up the virus from rodents imported from Ghana.<sup>6</sup> The strain of MPXV in the current outbreak likely diverged from West African clade, which carries a <1% case-fatality ratio, in contrast to the Central African or Congo Basin clade, with a case-fatality rate of >10%.<sup>7</sup> The MPXV from the first imported case in Taiwan is phylogenetically related to West African clade B.1 circulating in Europe.

One striking feature in the current monkeypox outbreak is the linkage of cases to sexual activity. However, this probably indicates transmission through close contact, rather than sexual transmission. Although viral DNA was detected in the semen of some cases,<sup>8</sup> it is unknown at this time if monkeypox can be spread via semen and vaginal fluid. Human-to-human transmission occurs through direct skin-to-skin contact with the infectious rash, scabs or body fluids, and respiratory droplets during prolonged, face-to-face or intimate physical contact, as may occur during sexual activities. Potential transmission may occur via fomites by contact with contaminated objects, such as towels and bedding, however, this requires confirmation with further studies.<sup>9,10</sup> Our patient’s last sexual contact was in



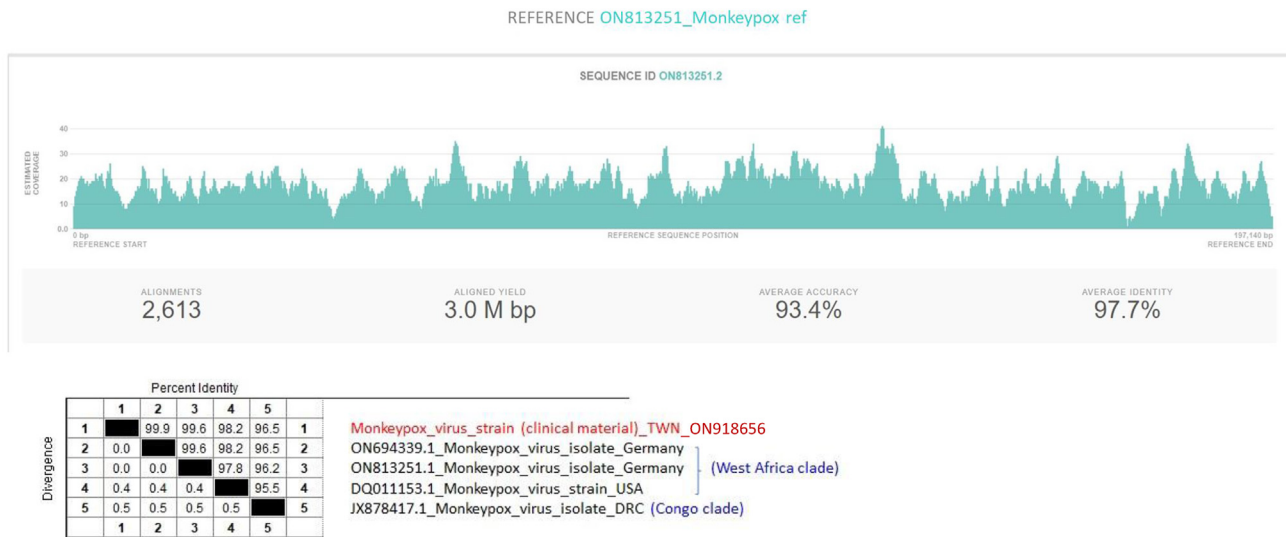
**Figure 1** Dermatologic features of monkeypox in a 24-year-old Taiwanese man, showing skin lesions in different stages (asynchronous): Pustular and vesicular lesions over his neck (A), chest (B), arms (C), anal region (D), buttock (E), thigh (F), foot (G), genitals (H, I), and resolving with scabs over his buttock and thigh (J) and foot (K) on day 9 after disease onset.

early June, which was within the incubation period of 5–21 days for monkeypox.

Classical presentation of monkeypox includes fever, swollen lymph nodes, followed by a centrifugal evolving rash. Atypical features described in this outbreak include presentation with only a few lesions; lesions in the genital, perineal and/or perianal areas; lesions appearing at

different (asynchronous) stages of development; and the appearance of lesions before the onset of fever and other constitutional symptoms.<sup>8,11</sup>

Immunocompromised individuals with monkeypox are at risk for more severe disease, with higher mortality. In the 2017 Nigerian outbreak, it was suggested that patients with concurrent HIV infection had more skin lesions and genital



**Figure 2** Direct whole genome sequencing on the vesicular fluid sample by Oxford Nanopore MinION apparatus obtained 197,315 base pairs sequence. The results indicate that viral sequence shares high similarity with the “West African” monkeypox virus clade, including the European (Germany) and American lineages, rather than the “Central African” or Congo clade. The Taiwan monkeypox strain (MPXV/human/Taiwan/110-231642/2022) was submitted to GISAID (accession no. ON918656.1).

ulcers compared to HIV-negative individuals.<sup>12</sup> In the current outbreak, people with HIV infections on antiretroviral treatment, maintaining good control, were not associated with worse outcomes.

An outbreak of monkeypox during a pandemic of COVID-19 was beneficial in mitigating the spread by early containment measures already in place for COVID-19. Our patient was under quarantine for COVID-19 upon arrival, limiting further spread prior to diagnosis. The pandemic response to COVID-19 has provided significant new knowledge which can be adapted and applied to minimize spread and reduce the global impact of the 2022 monkeypox outbreak.<sup>13</sup>

In conclusion, we report the first imported case of monkeypox in Taiwan in an Asian man with HIV-1 infection and asymptomatic COVID-19, returning from Germany. Atypical presentations include anogenital skin lesions and prominent inguinal lymphadenopathy. Although the current global outbreak of monkeypox has been linked to MSM and sexual activity, it is important to acknowledge that transmission of monkeypox is through close physical contact and not limited to any specific risk group. Increased awareness is crucial for prompt diagnosis and initiation of appropriate infection control measures to mitigate the further spread of monkeypox.

## Statement of ethics

The patient consented to use of his medical photographs for purposes of medical teaching and for publication in medical journals.

## Funding sources

This work was supported by the Veterans Affairs Council, R.O.C., Taipei, Taiwan, Republic of China (grant number: VAC111-005).

## Author contributions

S.T. Huang, J.H. WU, S.S. Lee, J.Y. Yang drafted the manuscript, S.J. Chiang, S.P. Wang, Y.H. Chan, L.F. Lin, Y.J. Chen collected the data, J.Y. Yang, P.Y. Hsieh performed the laboratory diagnosis, H.H. Lin, H.C. Tsai, Y.S. Chen, S.S. Lee revised the manuscript critically for important intellectual content. All authors read and approved the final manuscript.

## Declaration of competing interests

The authors have no conflicts of interest relevant to this article.

## References

1. W.H.O. Multi-country monkeypox outbreak: situation update (June 27, 2022). <https://www.who.int/emergencies/disease-outbreak-news/item/2022-DON396> Accessed June 28.
2. Li Y, Zhao H, Wilkins K, Hughes C, Damon IK. Real-time PCR assays for the specific detection of monkeypox virus West African and Congo Basin strain DNA. *J Virol Methods* 2010;169:223–7.
3. Neubauer H, Reischl U, Ropp S, Esposito JJ, Wolf H, Meyer H. Specific detection of monkeypox virus by polymerase chain reaction. *J Virol Methods* 1998;74:201–7.
4. Real-Time tracking of pathogen evolution. <https://nextstrain.org/> Accessed July 7.
5. Bunge EM, Hoet B, Chen L, Lienert F, Weidenthaler H, Baer LR, et al. The changing epidemiology of human monkeypox-A potential threat? A systematic review. *PLoS Neglected Trop Dis* 2022;16:e0010141.
6. Centers for Disease C, Prevention. Update: multistate outbreak of monkeypox-Illinois, Indiana, Kansas, Missouri, Ohio, and Wisconsin, 2003. *MMWR Morb Mortal Wkly Rep* 2003;52:642–6.
7. Isidro J, Borges V, Pinto M, Sobral D, Santos JD, Nunes A, et al. Phylogenomic characterization and signs of microevolution in

- the 2022 multi-country outbreak of monkeypox virus. *Nat Med* 2022;28(8):1569–72.
8. Antinori A, Mazzotta V, Vita S, Carletti F, Tacconi D, Lapini LE, et al. Epidemiological, clinical and virological characteristics of four cases of monkeypox support transmission through sexual contact, Italy, May 2022. *Euro Surveill* 2022:27.
  9. Rizk JG, Lippi G, Henry BM, Forthal DN, Rizk Y. Prevention and treatment of monkeypox. *Drugs* 2022;82(9):957–63.
  10. Essbauer S, Meyer H, Porsch-Ozcurumez M, Pfeffer M. Long-lasting stability of vaccinia virus (orthopoxvirus) in food and environmental samples. *Zoonoses Public Health* 2007;54: 118–24.
  11. W.H.O. Multi-country monkeypox outbreak: Situation update (June 17, 2022). <https://www.who.int/emergencies/disease-outbreak-news/item/2022-DON393> Accessed July 1.
  12. Ogoina D, Izbewule JH, Ogunleye A, Ederiane E, Anebonam U, Neni A, et al. The 2017 human monkeypox outbreak in Nigeria-Report of outbreak experience and response in the Niger Delta University Teaching Hospital, Bayelsa State, Nigeria. *PLoS One* 2019;14:e0214229.
  13. Ennab F, Nawaz FA, Narain K, Nchasi G, Essar MY. Rise of monkeypox: lessons from COVID-19 pandemic to mitigate global health crises. *Ann Med Surg (Lond)* 2022;79:104049.