



# Medial Patellofemoral Ligament Reconstruction in a Revision Setting: Anchor and Interference Screw Fixation

Marcio B. Ferrari, M.D., George Sanchez, B.S., Angela Chang, B.A., Sami Ferdousian, B.S., and Matthew T. Provencher, M.D.

**Abstract:** Recurrent patellar instability is a common pathology and typically affects younger and more active patients. To prevent complete lateral dislocation of the patella, several osseous and soft-tissue procedures have been previously described, including reconstruction of the medial patellofemoral ligament (MPFL), which has been identified as the primary medial stabilizer of the patella. Several techniques have been reported for reconstruction of the MPFL, sometimes in conjunction with other procedures, with the majority showing success in the treatment and resolution of patellar instability. However, MPFL reconstruction is not free of complications, with previous reports of recurrence of medial patellar instability and patellar fracture after surgery. The objective of this Technical Note is to describe our preferred technique, comprising anchor as well as interference screw fixation, for reconstruction of the MPFL in a primary or revision setting.

Patellar instability is a relatively common and particularly limiting pathology, occurring as a result of osseous or soft-tissue abnormalities including excess valgus of the knee, femoral anteversion or tibial torsion, patella alta, trochlear dysplasia, and insufficiency of the medial patellofemoral ligament (MPFL).<sup>1,2</sup> The MPFL is the primary medial stabilizer of the patella. Ultimately, the MPFL maintains patellar stability and helps avoid lateral subluxation and/or dislocation of the patella; therefore, reconstruction of this ligament is often needed in the setting of patellar instability, whether as an isolated procedure or in combination with other procedures.<sup>3-5</sup>

The MPFL originates from the superomedial aspect of the patella. Then, from the patella, the ligament consistently inserts on the femur, in the area between the medial femoral epicondyle, adductor tubercle, and gastrocnemius tubercle. The length varies between 45 and 74 mm, with an average of 56 mm; however, it remains unclear whether the length of the ligament is related to patellar instability.<sup>6</sup> The objective of this Technical Note is to describe our preferred technique, comprising anchor as well as interference screw fixation, for reconstruction of the MPFL in a primary or revision setting.

## Surgical Technique

### Preoperative Setup and Patient Positioning

The patient is placed supine on the operating table (Video 1). After the induction of general anesthesia, a bilateral knee examination is performed to evaluate for any concurrent pathology, as well as to assess for knee range of motion, patellar mobility and instability, and patellar crepitus during knee flexion. After an examination with the patient under anesthesia, a well-padded thigh tourniquet is placed on the upper thigh of the operative leg. The surgical leg is prepared and draped in a sterile fashion. Afterward, the leg is exsanguinated, and the tourniquet is inflated to 200 mm Hg.

From the Steadman Philippon Research Institute (M.B.F., G.S., A.C., M.T.P.), Vail, Colorado; University of California Santa Barbara (S.F.), Santa Barbara, California; and The Steadman Clinic (M.T.P.), Vail, Colorado, U.S.A.

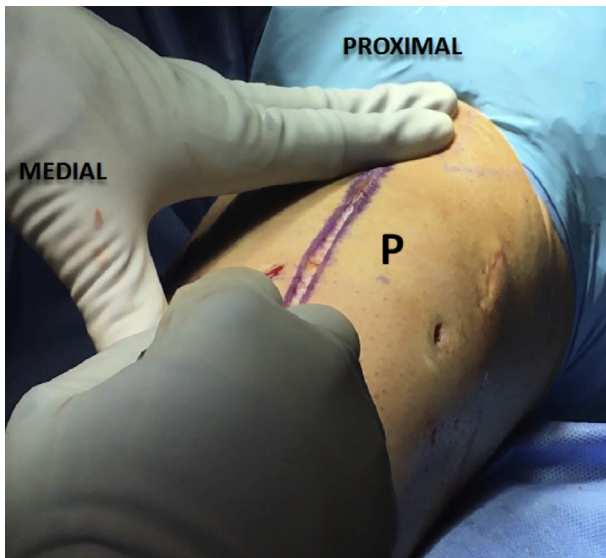
The authors report the following potential conflict of interest or source of funding: M.T.P. receives support from Arthrex, JRF Ortho. Consultant. Patent numbers (issued): 9226743, 20150164498, 20150150594, 20110040339. Arthrex, SLACK. Publishing royalties. The financial support is not related to this work.

Received January 14, 2017; accepted March 2, 2017.

Address correspondence to Matthew T. Provencher, M.D., Steadman Philippon Research Institute, 181 W Meadow Dr, Ste 1000, Vail, CO 81657, U.S.A. E-mail: [mprovencher@thesteadmanclinic.com](mailto:mprovencher@thesteadmanclinic.com)

© 2017 by the Arthroscopy Association of North America  
2212-6287/1773/\$36.00

<http://dx.doi.org/10.1016/j.eats.2017.03.005>



**Fig 1.** To perform a medial patellofemoral ligament reconstruction in a left knee, the medial border of the patella (P) is used as a reference. Usually, a 5-cm parapatellar incision is made to access and prepare the patella for graft fixation. In this case the incision was extended to the tibial tubercle as a result of a concomitant osteochondral allograft transplant onto the patella.

### Diagnostic Arthroscopy

A diagnostic arthroscopy is performed using the standard anterolateral and anteromedial portals. Any areas of synovitis are resected. After this, the patellar and trochlear cartilage is evaluated. If any concomitant pathology is present, it is addressed at this time.

### Exposure of Medial Patella

A 5-cm longitudinal parapatellar medial incision is performed, followed by blunt dissection of the subcutaneous tissue layer (Fig 1). In this case, the incision is larger than 5 cm as a result of a concomitant procedure. Therefore, there is greater visualization (Video 1) of the surrounding anatomy and overall technique than in the setting of an isolated MPFL reconstruction. Next, a 5-cm medial arthrotomy is made in line with the skin incision to expose the medial border of the patella (Fig 2). Once properly exposed, the femoral attachment of the MPFL is evaluated. In our case, the patient had a previous failed MPFL reconstruction with an extensive amount of scar tissue.

The identification of the adductor tubercle is key and will be used for the positioning of the femoral tunnel. It is important to note this bony landmark for an anatomically accurate reconstruction. By use of Metzenbaum scissors or hemostatic clamps, the layers between the MPFL are identified. The MPFL and surrounding anatomy are then cleared of all scar tissue to allow for optimal passage of the graft (Fig 3). The

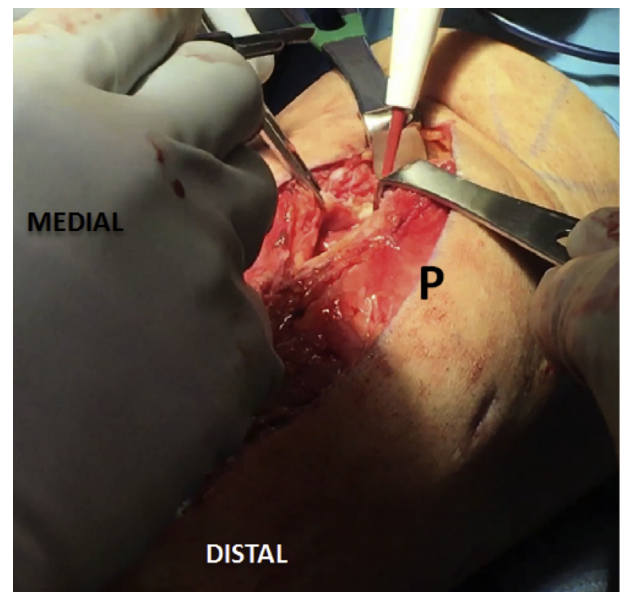
femoral tunnel is created between the superficial layer (medial retinaculum) and the deep medial layer (medial patellomeniscal and patellotibial ligaments). Afterward, the medial border of the patella is evaluated. By use of a combination of a rongeur and coagulator, all scar tissue is resected, thereby forming a bleeding bony surface (Fig 4). The positioning of the patella in relation to the patellar groove is also evaluated at this time.

### Tendon Harvest and Preparation

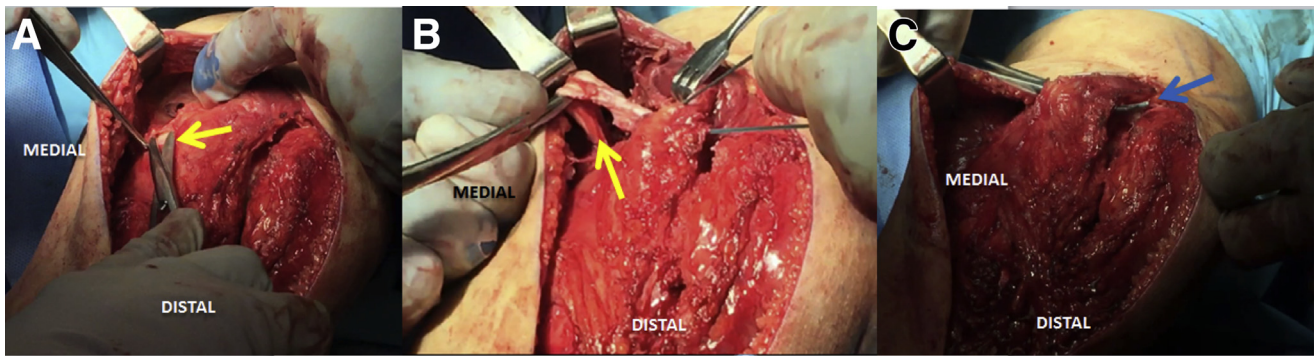
After preparation of the medial patella, attention is turned to the harvest of the semitendinosus autograft to be used in replacement of the native MPFL. A 2-cm incision is made directly above the pes anserinus, which is carefully dissected. After this, the semitendinosus tendon is identified. The semitendinosus is then released from the gracilis and sartorius with all adhesions removed. With use of a tendon stripper, the tendon is harvested and prepared on the back table prior to fixation. As part of the necessary preparation, the tendon is doubled over. Then, the width of the graft is measured. In this case the tendon measured 7 mm in width.

### Femoral Fixation

Once the semitendinosus graft has been prepared, the adductor tubercle is identified. By use of an acorn reamer (Arthrex, Naples, FL), a tunnel is made 3 mm distal to the adductor tubercle (Fig 5). If the adductor tubercle is not easily identifiable, the adductor magnus



**Fig 2.** Following the skin incision, blunt dissection of the subcutaneous tissue is performed to expose the medial retinaculum of the left knee. A 5-cm medial arthrotomy is performed to evaluate the medial border of the patella (P).



**Fig 3.** After the medial arthrotomy is performed in the left knee, the adductor tubercle is identified and, through palpation, the previous graft location is evaluated. (A, B) Metzenbaum scissors are used to release the graft (arrows), which is first removed from its femoral attachment. (C) The layers between the previous graft are released from any adhesions through use of Metzenbaum scissors and a Mixer clamp (arrow) with the goal of creating a soft-tissue tunnel that will accommodate the graft.

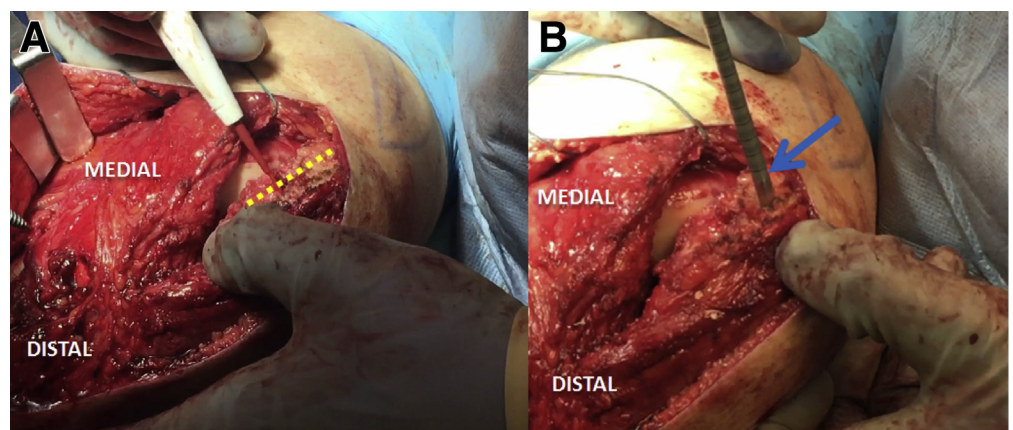
tendon is used to find the position of the adductor tubercle. In this case an 8-mm tunnel is made and the graft is fixed in the femur with an 8 × 23-mm bioscrew (Arthrex). After fixation onto the femoral tunnel, the limbs of the graft are left unconstrained for subsequent posterior fixation at the patella. By use of a Mixer clamp, the two limbs of the graft are passed inside the previously formed soft-tissue tunnel.

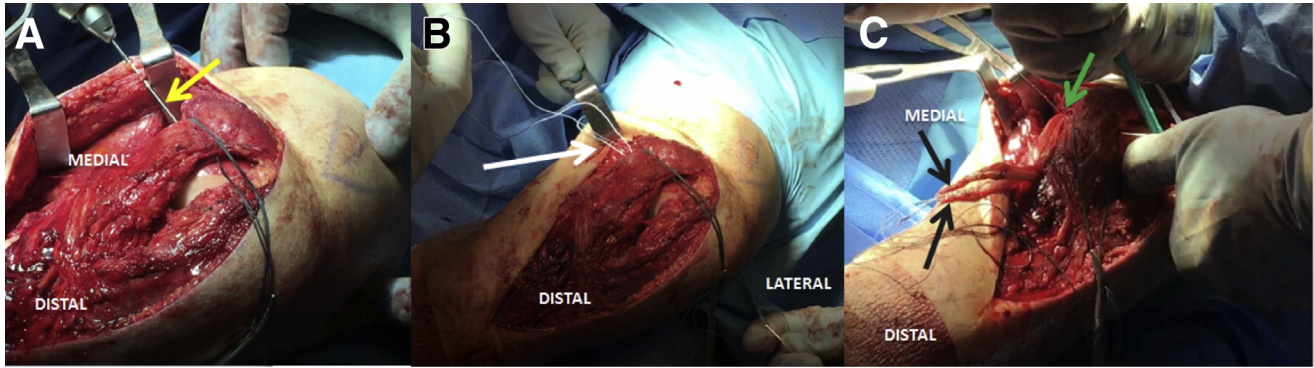
#### Patellar Fixation

Once the graft is secured on the femur, attention is turned to patellar fixation. The superior one-third and the central area of the patella are identified at the medial border of the patella. Noting the length of the patella, especially the superior one-third and central portions of the patella, is key to arrive at an anatomically accurate reconstruction. The width is also evaluated to ensure optimal positioning of the anchors, as well as to avoid damage to the patellar cartilage. By use of a 3.2-mm drill, followed by a tap, both limbs of the semitendinosus graft are secured to the patella with two 4.75-mm SwiveLock anchors (Arthrex) with FiberTape

as well as No. 2 suture (Ethicon, Somerville, NJ). We recommend tying the sutures at 30° of flexion and then tensioning at 45° to ensure that patellar mobility is preserved to the normal one-quarter while also avoiding over-tensioning of the medial side, which consequently may result in iatrogenic medial instability. Once the reconstruction is completed (Fig 6), the medial retinaculum is closed with a No. 2 Ethibond suture (Ethicon) and a No. 0 Vicryl suture (Ethicon). After the medial retinaculum is closed, the knee is taken through its full range of motion. Patellar tracking is then evaluated. Closure of the subcutaneous tissue layer and the skin layer is performed in standard fashion. Although we identify the optimal position of the MPFL for reconstruction through use of bony landmarks, C-arm imaging is an alternative method to intraoperatively verify the position of the MPFL for reconstruction. Again, this is our preferred technique for MPFL reconstruction in a primary or revision setting. Relevant advantages and disadvantages regarding the technique are listed in Table 1, and pearls and pitfalls are presented in Table 2.

**Fig 4.** (A) The medial border of the patella (dotted line) in the left knee is identified. By use of a combination of a rongeur and coagulator, all soft tissues are removed from the medial patella to create a bony bleeding surface. (B) Once the patella is prepared, two deep closed-socket tunnels are formed using a 3.2-mm drill (arrow).





**Fig 5.** To prepare the femoral attachment of the medial patellofemoral ligament in the left knee, the adductor tubercle is used as a reference. (A) A guide pin (arrow) is drilled 3 mm distal to the adductor tubercle and passed to the other side of the thigh. Fluoroscopic imaging can be used to ensure optimal positioning at this time. By use of an acorn reamer, the size of which varies depending on the width of the semitendinosus tendon graft harvested, a closed-socket tunnel is performed. (B) A passing suture (arrow) is passed inside the tunnel to allow for graft fixation. (C) The graft is secured onto the femur (green arrow), whereas the two limbs of the graft are left unconstrained for further fixation on the patella (black arrows).

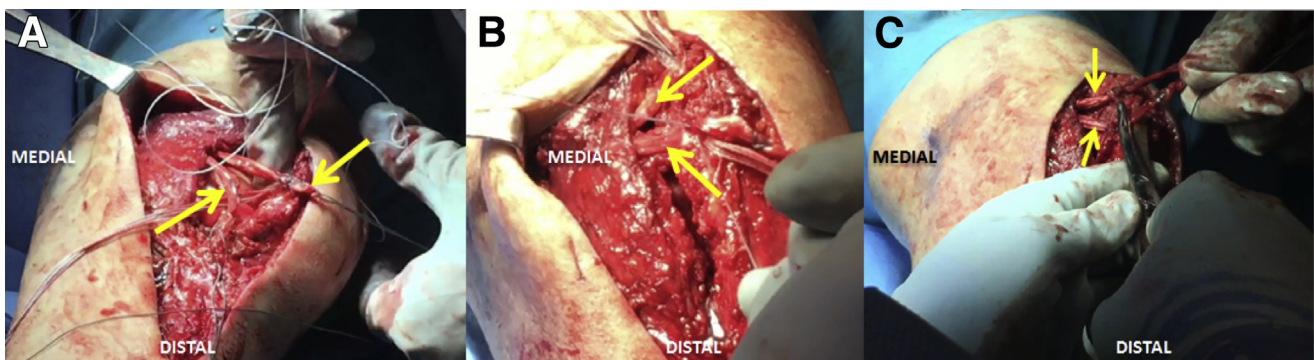
### Rehabilitation Protocol

With regard to postoperative rehabilitation, early passive range of motion (PROM) of the knee is suggested. During the first 2 weeks after surgery, PROM is restricted from 0° to 90° of flexion. However, after this period, full PROM is permitted. From the first to the eighth week, rehabilitation exercises include flexion and extension exercises (wall slides and seated), patella and patellar tendon mobilization exercises, extension mobilization, quadriceps series, and ankle pumps. During this same period, the patient is allowed to start biking and/or rowing using the nonoperative limb. Then, after 6 weeks, biking exercises may be performed with both limbs, with no resistance until week 8. Hamstring sets, toe-heel raises, and balance series start at week 6. Then, at week 10, balance squats and leg presses may be initiated. The timing of a complete return to sport is individualized on a patient-to-patient basis, with a full return usually between postoperative weeks 22 and 24.

### Discussion

MPFL reconstruction was first described by Ellera Gomes<sup>7</sup> in 1992 as an alternative method for treatment of lateral patellar instability. Using a synthetic graft made of polyester, Ellera Gomes treated recurrent instability of the patella in 30 patients through MPFL reconstruction. Of the 30 patients, 25 (83.3%) showed satisfaction with the procedure and improvement of initial complaints at 39 months' follow-up. Since this initial report, several other techniques have been described for the reconstruction of the MPFL with various grafts used, including the gracilis tendon,<sup>8,9</sup> quadriceps tendon,<sup>10</sup> patellar tendon,<sup>11</sup> and fascia lata.<sup>12</sup> After his initial report, Gomes<sup>13</sup> showed that MPFL reconstruction can be completed successfully with a half-width semitendinosus graft, thereby reducing morbidity associated with graft harvest and subsequent hamstring weakness.

Although a variety of techniques for MPFL reconstruction have been previously described, most have



**Fig 6.** (A) Once the semitendinosus graft is secured to the femur in the left knee, both ends of the graft (arrows) are passed inside the previously formed soft-tissue tunnel. (B) The optimal position of the patella, as the ends of the graft (arrows) are manipulated, is identified to avoid iatrogenic medial patellar dislocation or an insufficient correction resulting in chronic lateral patellar instability. (C) Each end of the semitendinosus graft is secured onto the patella by use of two 4.75-mm SwiveLock anchors with FiberTape and No. 2 suture. After this, excess graft (arrows) is removed.

**Table 1.** Advantages and Disadvantages

<p><b>Advantages</b></p> <p>The use of anchor fixation at the patella, instead of a large intra-bone tunnel, helps decrease the risk of a patellar fracture. This technique can be performed in conjunction with other procedures including tibial tubercle transfer.</p> <p>An arthroscopic procedure, prior to exposure of the patella, can be performed to confirm patellar and/or trochlear chondromalacia, if present.</p>
<p><b>Disadvantages</b></p> <p>Fluoroscopy may be needed to assess and confirm optimal positioning of the MPFL attachment on the femur.</p> <p>The technique is technically demanding with several steps.</p>

MPFL, medial patellofemoral ligament.

reported positive treatment outcomes with elimination of patellar instability symptoms.<sup>14,15</sup> Nevertheless, if patellar instability is present, a thorough preoperative evaluation is necessary to eliminate the possibility of any concomitant injuries. If bony malalignment, trochlear dysplasia, or patella alta is identified during the preoperative workup, an isolated MPFL reconstruction must not be performed.<sup>16</sup> In a systematic review and meta-analysis comprising 14 articles, Schneider et al.<sup>15</sup> reported a 1.2% pooled total risk of recurrent instability after isolated MPFL reconstruction with a reoperation risk of 3.1%. Overall, most patients were able to return to sport without incidence of recurrent instability after isolated MPFL reconstruction.<sup>15</sup>

However, MPFL reconstruction is also regularly performed in conjunction with another procedure. In these cases, positive treatment outcomes have also been described. Mulliez et al.<sup>17</sup> evaluated patients who

**Table 2.** Pearls and Pitfalls

<p><b>Pearls</b></p> <p>Trochlear dysplasia, TT-TG distance, patella index, and rotation of the femur, as well as the tibia, must be evaluated preoperatively to verify the possibility of &gt;1 procedure.</p> <p>The medial border of the patella must be assessed prior to anchor fixation to ensure correct positioning of the anchors.</p> <p>Placement of the graft should be performed at the superior and central one-third position of the patella.</p> <p>A thorough understanding of the femoral attachment of the MPFL is needed to perform anatomic placement of the graft.</p> <p>Careful dissection of the femoral attachment helps prevent damage to surrounding structures.</p> <p>The graft must be fixed at 30°-45° of flexion to prevent mal-tensioning.</p>
<p><b>Pitfalls</b></p> <p>The width of the patella may vary between patients; therefore, care must be taken to avoid damage to the cartilage of the patella, as well as to avoid a possible patellar fracture.</p> <p>Iatrogenic medial patellar instability or recurrent lateral instability can occur if the graft is fixed in an incorrect position or if the graft is improperly tensioned.</p> <p>Damage to the saphenous nerve during completion of this procedure may result in numbness or pain.</p>

MPFL, medial patellofemoral ligament; TT-TG, tibial tubercle–trochlear groove.

underwent MPFL reconstruction either in isolation or in combination with transposition of the tibial tubercle, and they reported positive patient-reported outcomes with no significant difference between the groups. In a systematic review on MPFL reconstruction with tibial tubercle transfer, Burnham et al.<sup>18</sup> reported a low to moderate risk of complications with positive treatment outcomes at an average follow-up of 38 months.

Nevertheless, MPFL reconstruction is not without risk and potential complications. Previous reports of complications included fractures of the patella, persistent lateral instability, patellofemoral osteoarthritis, and loss of native knee flexion.<sup>19-21</sup> In our described technique, the risk of a patellar fracture is decreased through the use of 2 anchors, which in turn avoids a large tunnel in the patella.

In conclusion, MPFL reconstruction is an effective procedure for the treatment of recurrent patellar instability. Regardless of the technique undertaken, whether in isolation or in conjunction with another procedure, positive treatment outcomes have been reported. Although we recommend our described technique, future long-term studies with large sample sizes will further affirm the efficacy and positive post-operative outcomes of MPFL reconstruction.

## References

- Buchanan G, Torres L, Czarkowski B, Giangarra CE. Current concepts in the treatment of gross patellofemoral instability. *Int J Sports Phys Ther* 2016;11:867-876.
- Rhee SJ, Pavlou G, Oakley J, Barlow D, Haddad F. Modern management of patellar instability. *Int Orthop* 2012;36:2447-2456.
- Chouteau J. Surgical reconstruction of the medial patellofemoral ligament. *Orthop Traumatol Surg Res* 2016;102:S189-S194.
- Desio SM, Burks RT, Bachus KN. Soft tissue restraints to lateral patellar translation in the human knee. *Am J Sports Med* 1998;26:59-65.
- Ellera Gomes JL, De César PC, Jungblut CF. Reconstrução do ligamento patelofemoral medial: Sua indicação na luxação da patela. *Rev Bras Ortop* 2003;38:56-66 [in Portuguese].
- Aframian A, Smith TO, Tennent TD, Cobb JP, Hing CB. Origin and insertion of the medial patellofemoral ligament: A systematic review of anatomy [published online September 8, 2016]. *Knee Surg Sports Traumatol Arthrosc*. doi:10.1007/s00167-016-4272-1.
- Ellera Gomes JL. Medial patellofemoral ligament reconstruction for recurrent dislocation of the patella: A preliminary report. *Arthroscopy* 1992;8:335-340.
- Schottle PB, Romero J, Schmeling A, Weiler A. Technical note: Anatomical reconstruction of the medial patellofemoral ligament using a free gracilis autograft. *Arch Orthop Trauma Surg* 2008;128:479-484.
- Chassaing V, Tremoulet J. Medial patellofemoral ligament reconstruction with gracilis autograft for patellar

- instability. *Rev Chir Orthop Reparatrice Appar Mot* 2005;91: 335-340 [in French].
10. Fink C, Veselko M, Herbot M, Hoser C. MPFL reconstruction using a quadriceps tendon graft: Part 2: Operative technique and short term clinical results. *Knee* 2014;21:1175-1179.
  11. Camanho GL, Bitar AC, Hernandez AJ, Olivi R. Medial patellofemoral ligament reconstruction: A novel technique using the patellar ligament. *Arthroscopy* 2007;23: 108.e1-108.e4.
  12. Drez D Jr, Edwards TB, Williams CS. Results of medial patellofemoral ligament reconstruction in the treatment of patellar dislocation. *Arthroscopy* 2001;17:298-306.
  13. Gomes JL. Medial patellofemoral ligament reconstruction with half width (hemi tendon) semitendinosus graft. *Orthopedics* 2008;31:322-326.
  14. Smith TO, Walker J, Russell N. Outcomes of medial patellofemoral ligament reconstruction for patellar instability: A systematic review. *Knee Surg Sports Traumatol Arthrosc* 2007;15:1301-1314.
  15. Schneider DK, Grawe B, Magnussen RA, et al. Outcomes after isolated medial patellofemoral ligament reconstruction for the treatment of recurrent lateral patellar dislocations: A systematic review and meta-analysis. *Am J Sports Med* 2016;44:2993-3005.
  16. Yeung M, Leblanc MC, Ayeni OR, et al. Indications for medial patellofemoral ligament reconstruction: A systematic review. *J Knee Surg* 2016;29:543-554.
  17. Mulliez A, Lambrecht D, Verbruggen D, Van Der Straeten C, Verdonk P, Victor J. Clinical outcome in MPFL reconstruction with and without tuberositas transposition [published online June 2, 2015]. *Knee Surg Sports Traumatol Arthrosc*. doi:10.1007/s00167-015-3654-0.
  18. Burnham JM, Howard JS, Hayes CB, Lattermann C. Medial patellofemoral ligament reconstruction with concomitant tibial tubercle transfer: A systematic review of outcomes and complications. *Arthroscopy* 2016;32:1185-1195.
  19. Dhinsa BS, Bhamra JS, James C, Dunnet W, Zahn H. Patella fracture after medial patellofemoral ligament reconstruction using suture anchors. *Knee* 2013;20:605-608.
  20. Parikh SN, Wall EJ. Patellar fracture after medial patellofemoral ligament surgery: A report of five cases. *J Bone Joint Surg Am* 2011;93:e97.(1-8).
  21. Parikh SN, Nathan ST, Wall EJ, Eismann EA. Complications of medial patellofemoral ligament reconstruction in young patients. *Am J Sports Med* 2013;41: 1030-1038.