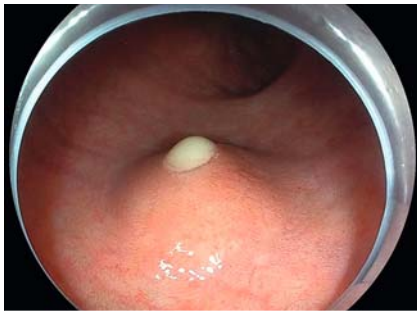
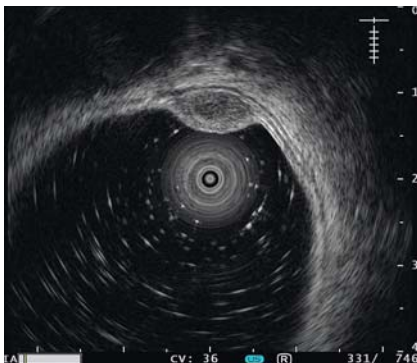
A case of rectal diverticulitis resembling a submucosal tumor under colorectal endoscopy: a hitherto undescribed lesion

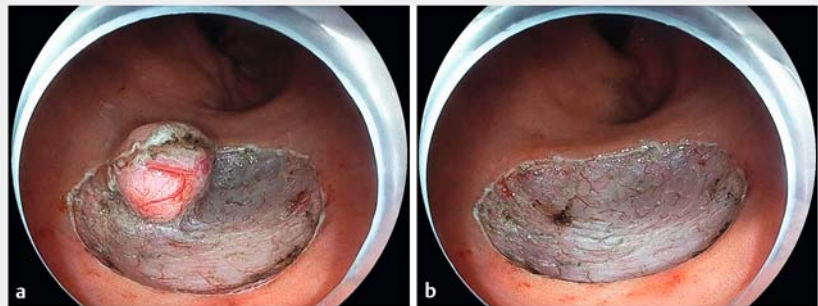


► **Fig. 1** Colorectal endoscopy findings. Colorectal endoscopy performed just before endoscopic submucosal dissection revealed a submucosal tumor (SMT)-like lesion approximately 10 mm in diameter with a smooth surface and a top pinhole-like opening in the rectum, with yellow-white liquid overflowing from the opening.




► **Fig. 2** Endoscopic ultrasonography revealed that the SMT located in the third layer was a single cystic lesion.

A 47-year-old man was referred to our hospital for a routine colorectal endoscopy health check-up. During the endoscopy, a submucosal tumor (SMT)-like lesion with a smooth mucosal surface, approximately 10 mm in diameter and with a top pinhole-like opening with overflowing yellow-white liquid, was found in the rectum (► **Fig. 1**). Endoscopic ultrasonography revealed that the SMT tumor located in the third layer was a single cystic lesion (► **Fig. 2**). The patient presented with no symptoms of abdominal pain,



► **Fig. 3** Endoscopic submucosal dissection of the lesion. **a** During dissection. **b** After dissection.



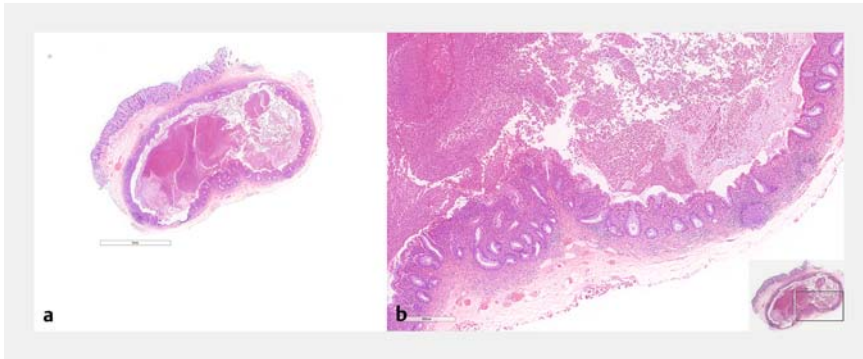
► **Fig. 4** The en bloc resected specimen. **a** Mucosal side. **b** Basal side.

fever, or mucus bloody stool. Laboratory profiles were all within normal limits. An enhanced abdominal computed tomography revealed a nodule lesion in the rectum with a slight enhancement. Enlargement of the regional lymph node was not observed. The lesion was clinically diagnosed as a rectal cystic tumor with a possibility of a benign tumor. Therefore, endoscopic submucosal dissection (► **Fig. 3**) was performed after patient consent was obtained. We successfully performed an en bloc resection of the lesion (► **Fig. 4**).

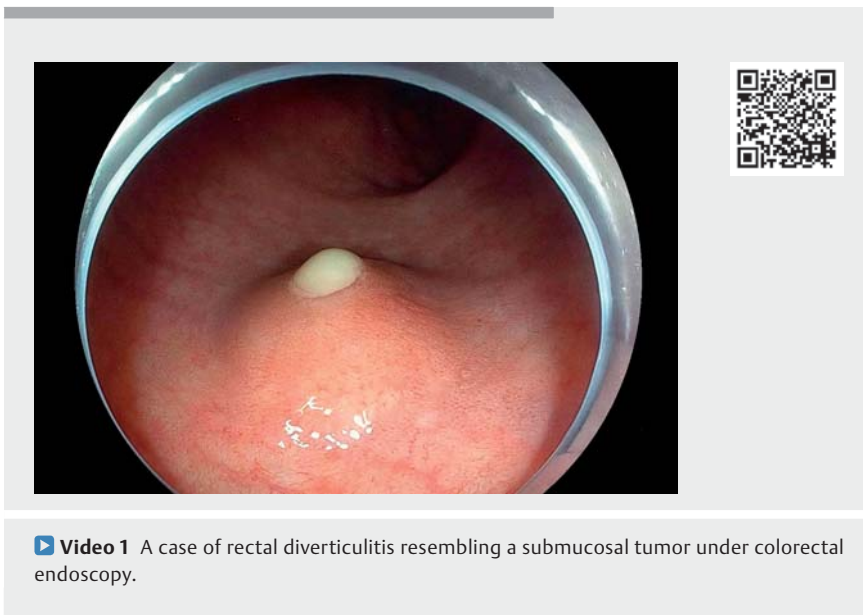
The cut surface of the resected specimen revealed a unilocular cyst filled with yellow-white viscous fluid. Histologically, the mucosal layer invaginated into the

submucosa of the rectum. The lumen of the lesion was entirely covered by the erosive inflammatory rectal mucosa, with abundant inflammatory exudates and necrosis. Based on these findings, a pathological diagnosis of rectal diverticulitis was made (► **Fig. 5**, ► **Video 1**).

Diverticulosis is characterized by the presence of mucosal and submucosal herniations or “pockets” [1]. Studies have reported polyp-like structures [2] and dimple-like or pillow signs [3] detected in the colon as inverted diverticula. Here, we report a rare case of rectal diverticulitis resembling a submucosal tumor with unusual endoscopic and pathological features. To our knowledge this is the first such case in the English literature.



► **Fig. 5** Histological analysis of the resected specimen with severe diverticulitis. **a** Whole mount view of the SMT-like lesion (hematoxylin and eosin staining, 10×). **b** The lumen of the lesion was entirely covered by the erosive inflammatory rectal mucosa, with abundant inflammatory exudates and necrosis (40×).



► **Video 1** A case of rectal diverticulitis resembling a submucosal tumor under colorectal endoscopy.

This case indicated a consideration of diverticulitis with a differential diagnosis of rectal mucosal changes with an SMT-like appearance.

Endoscopy_UCTN_Code_CCL_1AB_2AC_3AF

Competing interests

The authors declare that they have no conflict of interest.

The authors

Yan Ou^{1,2}, **Long Chen**¹, **Yan Ye**^{1,2}, **Ruiqiang Yang**¹, **Yankun Song**³, **Xianjing Yu**³, **Juan Liao**^{1,2}

- 1 Department of Gastroenterology, West China School of Public Health and West China Forth Hospital, Sichuan University, Chengdu, China
- 2 Non-communicable Diseases Research Center, West China-PUMC C. C. Chen Institute of Health, Sichuan University, Chengdu, China
- 3 Department of Pathology, West China School of Public Health and West China Forth Hospital, Sichuan University, Chengdu China

Corresponding author

Juan Liao, MD

Department of Gastroenterology, West China School of Public Health and West China Forth Hospital, Sichuan University, 37 Guoxue Alley, Wuhou District, Chengdu 610041, China
juanliao@scu.edu.cn

References

- [1] You H, Sweeny A, Cooper ML et al. The management of diverticulitis: a review of the guidelines. *Med J Aust* 2019; 211: 421–427
- [2] Paoluzi OA, Tosti C, Andrei F et al. Look out before polypectomy in patients with diverticular disease—a case of a large, inverted diverticulum of the colon resembling a pedunculated polyp. *Can J Gastroenterol* 2010; 24: 61–63
- [3] Gulaydin N, Iliaz R, Ersoz F. Inverted colonic diverticulum: An endoscopic examination and presentation. *J Dig Dis* 2021; 22: 152–158

Bibliography

Endoscopy 2023; 55: E280–E281
DOI 10.1055/a-1968-7153
ISSN 0013-726X
published online 2.12.2022
© 2022. The Author(s).

This is an open access article published by Thieme under the terms of the Creative Commons Attribution-NonDerivative-NonCommercial License, permitting copying and reproduction so long as the original work is given appropriate credit. Contents may not be used for commercial purposes, or adapted, remixed, transformed or built upon. (<https://creativecommons.org/licenses/by-nc-nd/4.0/>)

Georg Thieme Verlag KG, Rüdigerstraße 14, 70469 Stuttgart, Germany

