

# Exploring adult-onset actinic prurigo in Thailand

Siripan Sangmala, Chanisada Wongpraparut, Narumol Silpa-archa, Chayada Chaiyabutr

Department of Dermatology, Faculty of Medicine Siriraj Hospital, Mahidol University, Bangkok, Thailand

## Abstract

Actinic prurigo (AP) is an uncommon photodermatosis. In European and Native American populations, AP is more common in young women and demonstrates clinical improvement or remission in adulthood. The clinical signs of AP differ in Asians because the disorder typically occurs in adults (adult-onset AP) and is clinically persistent. The objective of this study was to investigate the characteristics and outcomes of patients with AP in Thailand. A total of 15 cases with AP were evaluated. All of them were adult-onset AP (mean onset age of 45.5 years). Males predominated (66.7%). The majority of them manifested with papules on the face and upper extremities. Mucositis was present in 2 patients. Phototesting revealed that the minimal erythematous dose (MED)

for UVA decreased in 3 subjects and the MED for both UVA and UVB decreased in other 3 patients. A photo-provocation test was performed on 9 patients with normal MED, and 5 of them showed positive UVA photo-provocation, while 4 showed positive UVA and UVB photoprovocation. A systemic immunosuppressant was prescribed in 60% of patients. Median time for clinical improvement was 8.6 months. Complete clinical remission was found in only 3 patients. Adult-onset AP has different clinical features and responds differently to treatment, compared to classical AP.

## Introduction

Actinic prurigo (AP) is an uncommon chronic idiopathic photodermatosis that presents with persistent pruritic papules, plaques or nodules on photodistributed areas. The pathogenesis of AP is poorly understood. However, much evidence supports the link between genetic predisposition and AP especially the HLA-DRB1\*0407.<sup>1</sup> In terms of the epidemiology of AP, the disease occurs very frequently in Native Americans (Amerindians) in Canada and the United States. It is also common in Mexico and the Central and South American regions.<sup>2</sup> In native American populations and European, AP is more frequently found in young women and shows clinical improvement or remission in adulthood. While the clinical characteristics of AP in Asians was reported to be markedly different in that the condition usually commences in adults (adult-onset AP) and is very refractory to treatment.<sup>3</sup> As there is not much information on adult-onset AP. The objective of this study was to investigate the clinical characteristics, photo testing, treatments and outcomes of Thai patients with AP.

## Materials and Methods

This retrospective study was performed at Faculty of Medicine Siriraj Hospital, Mahidol University, Bangkok, Thailand. Medical records of all patients with AP attending the Photodermatology clinic between 2006 and 2020 were reviewed. Photoprotective behavior and some missing information were collected by telephone interview. Broadband ultraviolet (UV) A and UVB phototesting was performed on a nonexposed area (the lower back) and was read at 24 hours. Our local population cutoffs for the minimal erythematous dose (MED) of UVB and UVA were 70-100 mJ/cm<sup>2</sup> and 30 J/cm<sup>2</sup>, respectively. If the patients had normal phototest results, a photoprovocation test was further performed. Consecutive exposure of 1.5 MED of UVB and 60-100 J/cm<sup>2</sup> of UVA was performed for 3 days. Itchy papules, plaques or nodules at the photoprovocation site were considered positive for AP.

## Results

A total of 15 AP patients were included and all patients had

Correspondence: Chayada Chaiyabutr, Department of Dermatology, Faculty of Medicine Siriraj Hospital, Mahidol University, 2 Wanglang Road, Bangkok Noi, Bangkok, Thailand.  
Tel.: +66.24194333.  
E-mail: ck\_cha@hotmail.com

Key words: actinic prurigo; photodermatoses, phototesting.

Contributions: SS, CC, conceptualization, methodology, writing of original draft; SS, formal analysis; CC, supervision; NSA, CW, writing, review, and editing. All the authors approved the final version to be published.

Conflict of interest: the authors declare no potential conflict of interest.

Funding: none.

Ethical approval: COA no. SI 139/2020.

Availability of data and material: data are available on request from the authors.

Acknowledgment: the authors are grateful to Ms. Orawan Supapueg for her help in the statistical analyses.

Received: 28 July 2023.

Accepted: 23 August 2023.

This work is licensed under a Creative Commons Attribution-NonCommercial 4.0 International License (CC BY-NC 4.0).

©Copyright: the Author(s), 2023

Licensee PAGEPress, Italy

Dermatology Reports 2024; 16:9810

doi:10.4081/dr.2023.9810

*Publisher's note: all claims expressed in this article are solely those of the authors and do not necessarily represent those of their affiliated organizations, or those of the publisher, the editors and the reviewers. Any product that may be evaluated in this article or claim that may be made by its manufacturer is not guaranteed or endorsed by the publisher.*

adult-onset AP. No young onset was found. The mean age of onset was 45.5 years. Male was predominated (66.7%). The median duration of disease at presentation (Interquartile range; IQR) was 12 (7,36) months. Mostly of them presented with papules (93.3%), following by plaques (46.7%), nodules (26.7%). The location of rash mostly located on forearm and dorsum of hands (93.3%), following by face and posterior neck (86.7%). Rash at V-shape of neck was presented in 73.3% of patients (Figure 1). All patients were itching. Mucositis was presented in only 2 patients (1 conjunctivitis and 1 cheilitis). Phototesting revealed decreased MED for UVA alone in 3 patients and decreased MED for both UVA and UVB in 3 patients. It is noteworthy that the degree of abnormal MED for UVA was moderate (>50% MED), while the degree of abnormal MED for UVB was slight abnormalities (>70% MED). Nine patients who had normal MED were further performed photoprovocation test and showed positive UVA photoprovocation in 5 patients: positive both UVA and UVB photoprovocation in 4 patients. Systemic immunosuppressant was prescribed in 60%, which were prednisolone (53.3%, usually given intermittently during the flare-up period) and methotrexate (20%). Two patients (13.3%) received narrowband UVB phototherapy. Photoprotective behavior was surveyed by telephone interview (n=8). Despite all patients with AP having been advised of the need for strict photoprotection, compliance was low. Only 50% reported regularly using sunscreen, 12.5% wore photoprotective clothing (long-sleeved shirts and long pants), and 12.5% wore a hat. No patient wore sunglasses. The median follow-up time was 37.0 months (IQR 26.3,58.3). Nearly all patients (14 patients) showed clinical improvement. A Kaplan-Meier survival analysis demonstrated the probability of clinical improvement in AP patients (Figure 2). Median time to clinical improvement was 8.6 months (IQR 1.2, 25.0). Complete clinical remission was found in only 3 patients.

AP differed between Asia, Europe/Australia and the Americas.<sup>2-9</sup> Asian patients with AP, including our study, had the highest mean age/age of AP onset (36.9-45.5 years), with a minority of cases occurring in women (5.3-40%).

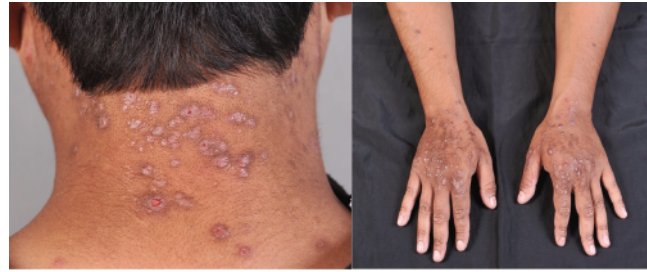

Figure 1. Clinical characteristics of adult-onset actinic prurigo.

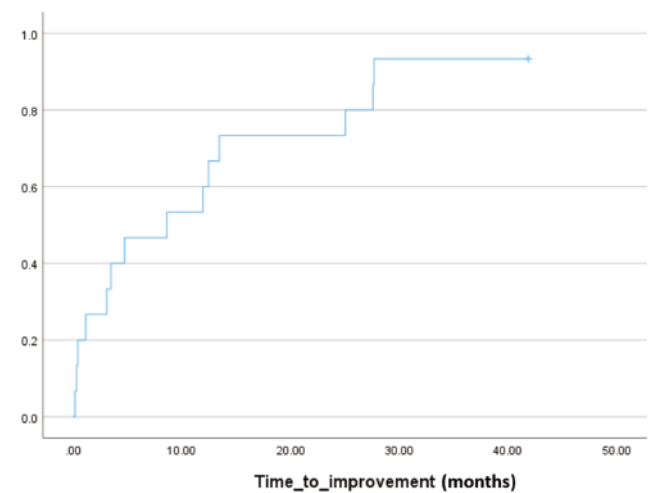


Figure 2. A Kaplan-Meier survival analysis demonstrating the probability of clinical improvement in patients with actinic prurigo (n=15).

## Discussion

This retrospective study revealed the distinctive characteristics of adult-onset AP in an Asian population. Compared to previous AP studies globally (Figure 3), the sex and age of patients with

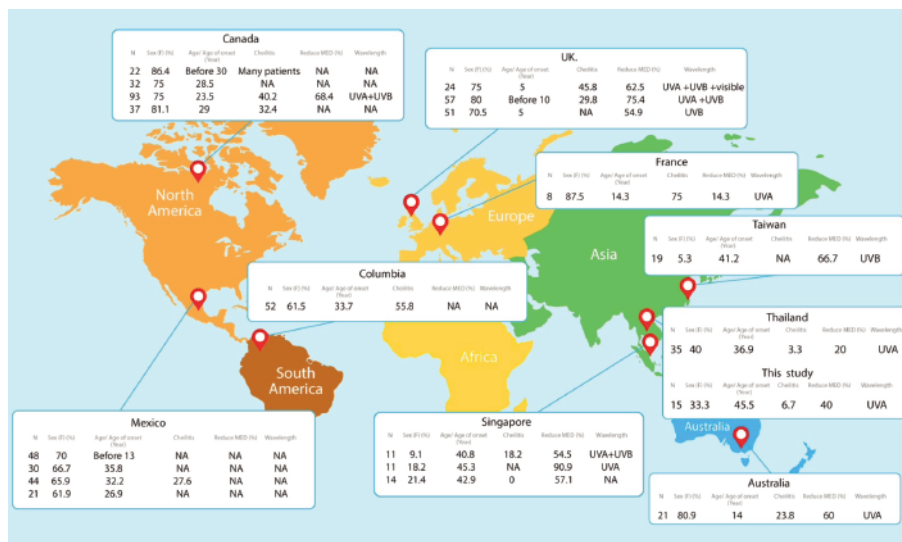


Figure 3. Characteristics and photo-test results/predominant wavelength of actinic prurigo in various countries. MED, minimal erythematous dose; NA, not available.

The Caucasian population (Europe and Australia) had the lowest age/age of onset of AP (5-14.3 years) and had the highest female sex rate (70.5-87.5%). In North, Central and South America, AP usually commenced in late adolescence or early adulthood, ranging from < 13 years to 35.8 years, and had a female predominance (61.5-86.4%). The disparities in age and sex proportions of AP among the regions reflect the different genetic backgrounds of AP in each ethnicity, which was supported by the discovery of varied HLA alleles in patients with AP from multiple countries.

Cheilitis is another clinical feature that differs among regions (Figure 3) and may sometimes be the sole manifestation of AP.<sup>10</sup> Common clinical features are swelling, scaling, crust, fissures and secondary ulceration at the lower lip. This feature was observed in 1 of our patients (6.7%), corresponding to the low rates reported by other investigations in Asia (3.3-18.2%). The low rate of cheilitis in Asian AP is in marked contrast to the studies from Europe/Australia (23.8-75%) and the Americas (27.6-55.8%). Therefore, cheilitis has been suggested as another distinguishing feature of Asian AP. From our study, the photoprovocation testing with UVA was most helpful in diagnosing patients with AP who had a normal MED. Our study showed that several patients with a normal MED underwent subsequent photoprovocation testing and showed positive results for UVA or the combined UVA/UVB wavelengths. This test gave an additional benefit and should be considered in patients suspected of having AP with a normal phototest result. We found that most of our patients demonstrated some improvement after treatment, but the improvement was often short-lived. Additionally, only 20% of patients showing complete remission. The reasons behind the treatment difficulty of adult-onset AP in Asia might be the perennial sunny climates, sub-optimal photoprotective behavior or the stubborn nature of the disease. However, the long-term follow-up data of our study were limited.

---

## Conclusions

In conclusion, adult-onset AP has several different features from classical AP. Our study highlights the disparities in demo-

graphics, clinical characteristics, and prognosis of the condition between regions. Whether adult-onset AP is an AP variant or a new photodermatosis requires clarification. Molecular genetic studies and further in-depth elucidation of the pathogenesis involved in the UV immune response are needed to provide the answer.

---

## References

1. Menagé Hd, Vaughan RW, Baker CS, et al. HLA-DR4 may determine expression of actinic prurigo in British patients. *J Invest Dermatol* 1996;106:362-7.
2. Lane PR, Hogan DJ, Martel MJ, et al. Actinic prurigo: clinical features and prognosis. *J Am Acad Dermatol* 1992;26:683-92.
3. Chen YA, Yang CC, Ting SW, et al. Adult-onset actinic prurigo: report of 19 patients from Taiwan. *J Eur Acad Dermatol Venereol*.2016;30:e140-e2.
4. Akaraphanth R, Sindhavananda J, Gritiyarangsana P. Adult-onset actinic prurigo in Thailand. *Photodermatol Photoimmunol Photomed* 2007;23:234-7.
5. Bernal JE, Duran de Rueda MM, Ordonez CP, et al. Actinic prurigo among the Chimila Indians in Colombia: HLA studies. *J Am Acad Dermatol* 1990;22:1049-51.
6. Cuevas-Gonzalez JC, Vega-Memije ME, Borges-Yáñez SA, Rodríguez-Lobato E. Risk factors associated with actinic prurigo: a case control study. *An Bras Dermatol* 2017;92:774-8.
7. Ker KJ, Chong WS, Theng CT. Clinical characteristics of adult-onset actinic prurigo in Asians: a case series. *Indian J Dermatol Venereol Leprol* 2013;79:783-8.
8. Macfarlane L, Hawkey S, Naasan H, Ibbotson S. Characteristics of actinic prurigo in Scotland: 24 cases seen between 2001 and 2015. *Br J Dermatol* 2016;174:1411-4.
9. Wiseman MC, Orr PH, Macdonald SM, et al. Actinic prurigo: clinical features and HLA associations in a Canadian Inuit population. *J Am Acad Dermatol* 2001;44:952-6.
10. Plaza JA, Toussaint S, Prieto VG, et al. Actinic prurigo cheilitis: a clinicopathologic review of 75 cases. *Am J Dermatopathol* 2016;38:418-22.