

Anterior Cruciate Reconstruction with Quadriceps Autograft using QuadLink Anterior Cruciate Ligament FiberTag TightRope Implant



Muhammad J. Abbas, B.S., Toufic R. Jildeh, M.D., Patrick Buckley, B.S., Nima Mehran, M.D., and Kelechi R. Okoroa, M.D.

Abstract: Quadriceps tendon autografts have been shown to be a reliable option for anterior cruciate ligament (ACL) reconstruction. The graft allows for optimal functional outcomes while reducing donor site morbidity. Although quadriceps graft fixation can be achieved using a variety of techniques, there is a lack of consensus on the optimal technique. Additionally, femoral fixation techniques have variance in durability and reproducibility. The purpose of this Technical Note and video is to provide our preferred method of quadriceps tendon autograft preparation and fixation using the Quad Link ACL FiberTag TightRope Implant in a single-bundle ACL reconstruction.

An anterior cruciate ligament (ACL) rupture is a common orthopedic sports injury with increasing incidence.¹ Graft selection has a significant implication on patient functional outcomes and donor site morbidity. Young patients with autograft reconstruction are thought to exhibit better performance with a reduced failure rate as compared to allografts.² Although bone patella tendon bone and hamstrings autografts have served as suitable options for ACL reconstructions, quadriceps autografts show considerable promise.

Quadriceps autografts portend several advantages with diminished donor site morbidity.^{3,4} Compared to hamstring autografts, quadriceps autografts have been shown to experience less pivot shift laxity and lower failure rate.⁵ In a biomechanical study, Shani and

colleagues⁶ demonstrated that quadriceps autografts have nearly twice the cross-sectional area as compared to bone patella tendon bone. Quadriceps autografts have also been demonstrated to provide enough length (70 mm) for the use of all-inside techniques.^{7,8} Contemporary techniques for quadriceps tendon harvest allow for additional length without risking patella fracture. There are many options for quadriceps graft fixation, with the optimal technique being subject to debate.

Quadriceps graft fixation options include aperture fixation, and suspensory fixation. The preferred technique for quadriceps graft fixation is yet to be elucidated.^{9,10} The purpose of this Technical Note and video is to provide our preferred method of quadriceps tendon autograft preparation and fixation using the Quad Link ACL FiberTag TightRope Implant in a single bundle ACL reconstruction. This technique offers several advantages over other methods (Table 1). Quadriceps tendon autograft can be harvested using a minimally invasive approach while providing a more reliable cross-sectional area and length for graft harvest as well as superior tensile strength as compared to patella tendon autografts ($3,660 \pm 830$ N vs $1,920 \pm 330$ N, respectively).^{8,11,12}

Surgical Technique

Patient Positioning

Before surgery, the patient receives an adductor canal block. The patient is positioned supine with the surgical limb secured in an arthroscopic leg holder and the

From the Department of Orthopaedic Surgery, Henry Ford Hospital, Detroit, Michigan (M.J.A., T.R.J., P.B.); Department of Orthopaedic Surgery, Mayo Clinic, Rochester, Minnesota (K.R.O.); and the Department of Orthopaedic Surgery, Kaiser Permanente, Los Angeles, California (N.M.), U.S.A

The authors report the following potential conflicts of interest or sources of funding: K.R.O. reports from Stryker, Arthrex, and Smith & Nephew. N.M. reports other from Arthrex and Smith & Nephew. Full ICMJE author disclosure forms are available for this article online, as supplementary material.

Received November 2, 2020; accepted January 29, 2021.

Address correspondence to Kelechi R. Okoroa, M.D., Department of Orthopaedic Surgery, Mayo Clinic, 600 Hennepin Avenue, Suite 310, Minneapolis, MN 55403, U.S.A E-mail: krokoroha@gmail.com

© 2021 THE AUTHORS. Published by Elsevier Inc. on behalf of the Arthroscopy Association of North America. This is an open access article under the CC BY-NC-ND license (<http://creativecommons.org/licenses/by-nc-nd/4.0/>).

2212-6287/201822

<https://doi.org/10.1016/j.eats.2021.01.026>

contralateral leg in a foam well-leg holder. After the induction of general anesthesia, an examination with the patient under anesthesia is performed to assess knee stability and range of motion. A nonsterile tourniquet is placed high on the leg and is set to 250 mm Hg.

Graft Harvest and Preparation

The distal vastus medialis oblique muscle line is outlined, and a line is drawn from the midline of the superior pole of the patella and extended slightly lateral and proximally 4 to 5 cm (Video 1). Army-navy retractors are used for visualization of the proximal-distal extent of the quadriceps tendon and vastus medialis oblique muscle. After the quadriceps tendon is exposed, a quad tendon graft harvester (Arthrex) is used to score the tendon just proximal to the superior pole of the patella and continued proximally (Fig 1A). A scalpel is then used to elevate the distal portion of the tendon from the patella and an Ethibond suture (Ethicon) is used as a traction suture through the tendon while excision is continued proximally (Fig 1B). Care must be exercised so as to not violate the suprapatellar pouch during excision. Should the suprapatellar pouch become violated, it must be repaired using Vicryl suture (Ethicon).

The traction suture is then used to pass the tendon through a 10 mm double blade quad tendon cutter (Arthrex) (Fig 1C).⁷ This autograft is harvested to a distance of 70 to 80 mm. The quad tendon cutter does not aid in freeing the graft proximally, and sharp dissection of the proximal portion of the graft must be completed before quad tendon cutter use. While the traction stitch is pulled through the quad tendon cutter, the cutter is pushed to the proximal extent of the graft. A ruler on the cutter is used to measure the total graft length. The trigger is then squeezed to resect the graft from the wound.

To prepare the quad tendon graft, a ruler is used to measure the total graft length, and a marker is used to denote 20 mm from the end of the graft, which is the location to begin the whipstitch. A FiberLoop suture (Arthrex) is then used on the tibial side of the graft in the standard whip stitch fashion to secure the graft. On the proximal portion of the graft, a TightRope (Arthrex) suture card is positioned with FiberTag sutures oriented towards the GraftClamp instrument's teeth (Arthrex) (Fig 2A). The card is then mounted on the holding slot of the GraftClamp, and one tooth of the GraftClamp is used to pierce the FiberTag suture 2mm from terminal portion of the graft (Fig 2 B and C). FiberTag Suture is then passed through the graft until the Fibertag suture converts to FiberLoop suture. After this initial pass through the graft, a standard Speedwhip technique is performed in the direction of the TightRope implant (Fig 2D). Two Speedwhip stitches are placed through the graft equidistant before passing the needle through the needle slot in the suture card (Fig 2 E and F). Following the needle being passed through the suture card, two Speedwhip

Table 1. Pearls and Pitfalls of Quadriceps Tendon Anterior Cruciate Ligament Reconstruction

Pearls	
Medial portion of the QT provides a more robust graft; however, lateral segment can be used if longer graft is desired	
QT offers predictable tendon diameter	
Minimally invasive technique	
No need to osteotomize patella compared to previous QT harvesting techniques	
Decreased incidence of patellar tendinitis and anterior knee pain compared to patellar tendon grafts	
Lower incidence of re-tearing compared to hamstring graft	
Decreased incidence of anterior knee sensory deficit when compared to patellar tendon grafts	
Pitfalls	
Must preserve the deepest layer of QT to maintain integrity of the suprapatellar bursa	
Tendency for patients to overestimate knee position via proprioception near terminal extension compared to anterior tibialis or hamstring graft	
Tendon length is predictable based on height. Shorter patients may have less-than-desirable tendon length.	

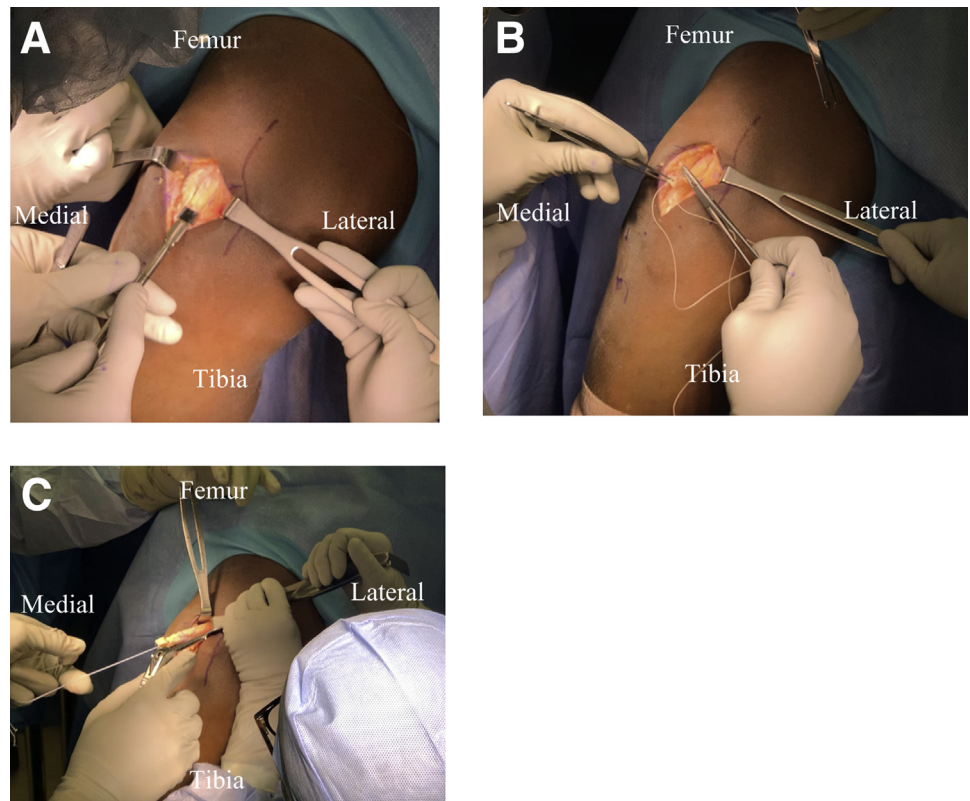
QT, quadriceps tendon.

stitches are placed equidistant through the graft working away from the suture card (Fig 2 G and H). The needle may then be passed through the tissue just beyond the end of the fibertag. One limb of the suture is cut, and the free suture limbs are wrapped around the graft and secured with a knot. The needle on the remaining suture limb is then passed through the tendon, and tension is applied to bury the knot in the graft. The remaining suture limb is then cut flush with the graft. The suture card is subsequently removed from the graft clamp, and the TightRope suture/implant is removed from suture card (Fig 2I). The graft is then placed through a sizing block to determine the appropriate tunnel size (Fig 2J). The graft is trimmed suitably to allow for tubularization and tensioned on the graft table during arthroscopic tunnel preparation.

Arthroscopy

Diagnostic arthroscopy is performed using standard anteromedial and anterolateral portals. The ruptured ACL is debrided with a shaver, and the femoral and tibial footprints are cleared with a wand and shaver. The reconstruction is carried out with suspensory fixation on the femur and interference screw fixation with backup on the tibia. The femur is prepared using the RetroConstruction Drill Guide System (Arthrex) and Flip-Cutter (Arthrex) (Fig 3A).¹⁰ First the femoral pin is placed using the RetroConstruction drill guide. Next, the femoral tunnel is reamed to appropriate length for the intraosseous section of the graft (Fig 3B). The back wall of the femur is then viewed to confirm an intact back wall (Fig 3C). A free suture is passed through the femoral tunnel using a fiberstick (Arthrex) and retrieved through the anteromedial portal using a suture retriever; it is secured with a hemostat. Positioning of the tibial

Fig 1. Patient is placed supine with right knee in flexion. (A) After quadriceps tendon is properly exposed, quad tendon graft harvester (Arthrex) is used to score the tendon. The double-blade harvester is started just proximal to the superior pole of the patella, and an initial score is continued proximally. A no. 15 blade is then used to elevate the distal portion of the quadriceps tendon. (B) A no. 1 Ethibond suture is passed through the graft to create a traction stitch. (C) The free end of the quadriceps tendon is then passed through Quad tendon cutter (Arthrex) until at least 8 cm of tendon is free proximally. The trigger is then pulled, and the tendon is fully excised.



tunnel is determined by positioning the tibial guide tip at the tibial insertion of the ACL. A guide pin is then inserted, and the appropriately sized reamer is used to create the tunnel (Fig 3D). The free suture previously passed from the femoral tunnel is unclamped, and the loop end is passed through the tibial tunnel with a suture grasper. A femoral loop suspensory fixation device is then passed from the tibial tunnel to the femoral tunnel with the free suture used as a shuttle (Fig 3E). The femoral button is then visualized to pass through the outside of the femoral tunnel, which is also confirmed fluoroscopically (Fig 3F). The femoral component of the graft is then brought into the femoral tunnel by alternate tensioning of the tightrope sutures while holding constant tension on the suture from the tibial side.

Graft tensioning

The positioning of the graft is verified arthroscopically. The knee is passed through the full range of motion for 20 repetitions before the femoral TightRope sutures are used to reapply tension on the graft. A BioComposite Interference Screw (Smith & Nephew) the same size as the tunnel diameter is applied to secure the graft in 20-30 of flexion and backup fixation is used with a 4.75 mm BioComposite SwiveLock (Arthrex). The knee is checked to confirm full range of motion, and an anterior drawer/Lachman test is used to confirm stability. The wounds are copiously irrigated.

Postoperative Care

In the first 2 weeks after surgery the patient is weightbearing as tolerated with crutches and brace. The hinged knee brace is kept locked in full extension during walking or sleeping. The brace is unlocked 0-90 while the patient is sitting or exercising. Postoperative pain was managed with a nonopioid multimodal pain protocol consisting of ketorolac, gabapentin, diazepam, and acetaminophen.¹³

Discussion

This Technical Note is a detailed surgical technique of quadriceps tendon autograft preparation and fixation using the Quad Link ACL FiberTag TightRope implant in a single bundle ACL reconstruction. Advantages of this technique include decreased donor site morbidity because of the small 4 to 5 cm incision used for graft harvest, reliable acquisition of a graft with appropriate length and cross-sectional area, and increased graft strength when compared to alternative graft types.

Historically, quadriceps tendon grafts were less commonly used because of concerns about donor site morbidity, with patella fractures occurring more frequently and failures of femoral fixation. Advances in surgical technique and graft harvest have allowed for a minimally invasive approach while using an all tissue

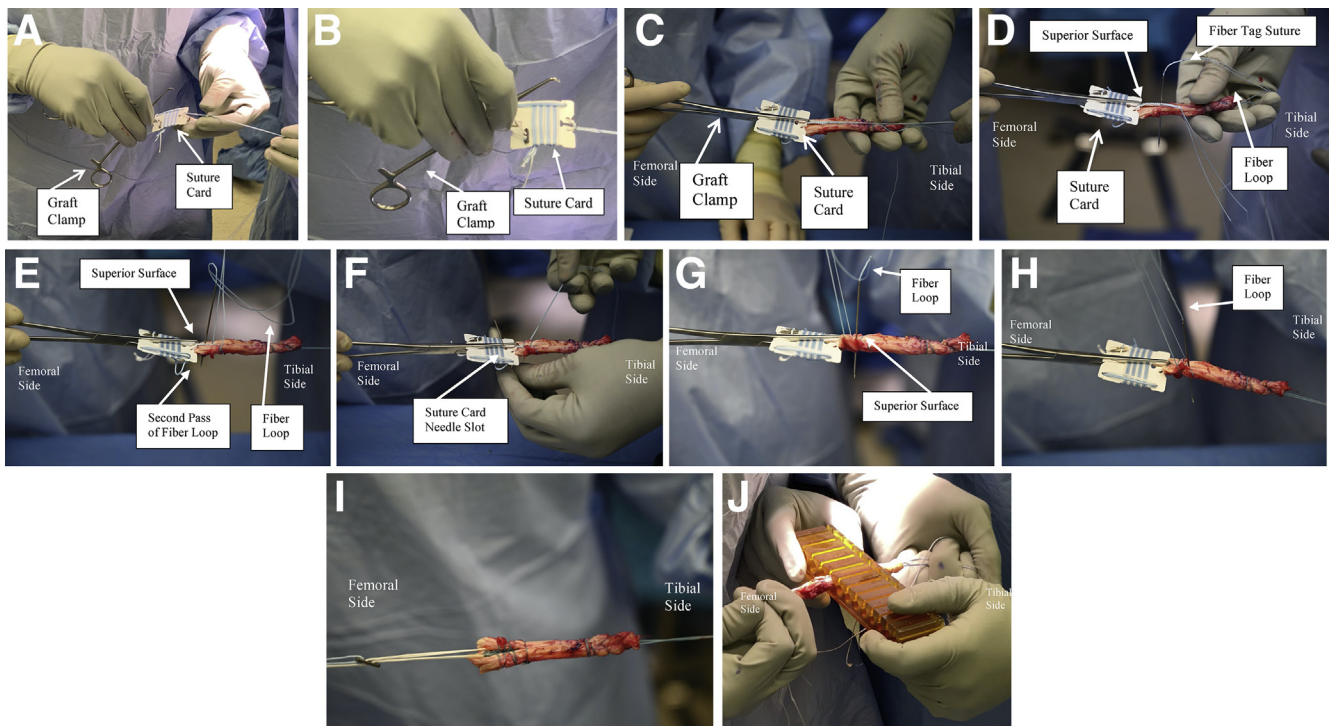


Fig 2. Excised graft is now brought to back table for preparation. (A) TightRope suture card was positioned with FiberTag sutures oriented toward the GraftClamp instrument's teeth. Card is then mounted in the card-holding slot of the GraftClamp. (B) FiberTag suture is then pierced using the teeth of the GraftClamp. (C) Quadriceps graft is then pierced by teeth of GraftClamp approximately 2 mm from terminal portion of the graft. (D) FiberTag Suture is then passed through the graft until the FiberTag suture converts to FiberLoop suture. After this initial pass through the graft, a standard Speedwhip technique is performed in the direction of the TightRope implant. (E) A second Speedwhip stitch is placed through the graft before the needle is passed through the needle slot in the suture card. (F) The needle is then passed through the needle slot of the suture card. (G) The first whip stitch is then performed through the graft working away from the suture card. (H) A second whip stitch is then placed working away from the suture card. (I) The suture card is then removed from the GraftClamp and the TightRope suture is removed from suture card. (J) The graft is then placed through a sizing block to determine the appropriate tunnel size.

graft rather than obtaining a bone block from the patella. Cadaveric studies have also allowed for improved anatomic characterization of the quadriceps tendon. These studies have demonstrated that the quadriceps tendons provide greatest length and depth lateral to the midline, allowing for consistent tendon acquisition.⁸ The present method of harvesting tendon using a quad tendon graft harvester requires a 4 to 5 cm incision that extends proximally from the proximal pole of the patella. Additional exposure is provided by careful retractor placement. These modifications have allowed for improved tendon harvest with smaller incisions and lower donor site morbidity.

The quadriceps tendon graft has also provided improvements in graft strength. Shani et al.⁶ performed a biomechanical comparison of quadriceps tendon grafts versus patellar tendon grafts in ACL reconstructions and found significantly higher load to failure in quadriceps tendons ($2,185.9 \pm 758.8$ N vs. $1,580.6 \pm 479.4$ N, $P = .045$) (PMID 26382635). Their analysis also found

that quadriceps tendons had significantly greater cross-sectional areas compared to patellar tendons (91.2 ± 10 mm vs 48.4 ± 8 mm, $P = .005$). Staeubli et al.¹¹ further evaluated the tensile properties of quadriceps tendon autografts and patellar tendon autografts and found that quadriceps tendons exhibited higher load to failure ($2,185.9 \pm 758.8$ N vs $1,580.6 \pm 479.4$ N, $P = .045$) and increased cross-sectional area (91.2 ± 10 mm² vs 48.4 ± 8 mm², $P < .01$) compared to patellar tendons.¹⁴ These findings demonstrate that quadriceps tendon grafts are reliable options for ACL reconstruction (ACL).

This technique is not without limitations. Guney-Deniz et al.¹⁵ demonstrated that a patient who received ACLR with an autograft quadriceps tendon is less likely to correctly identify joint position at 15° of flexion compared to hamstrings or tibialis anterior autografts ($P < .0001$). When a quadriceps tendon harvest is performed, there is a risk of violating the suprapatellar pouch; however, it should be noted that a disruption of the suprapatellar

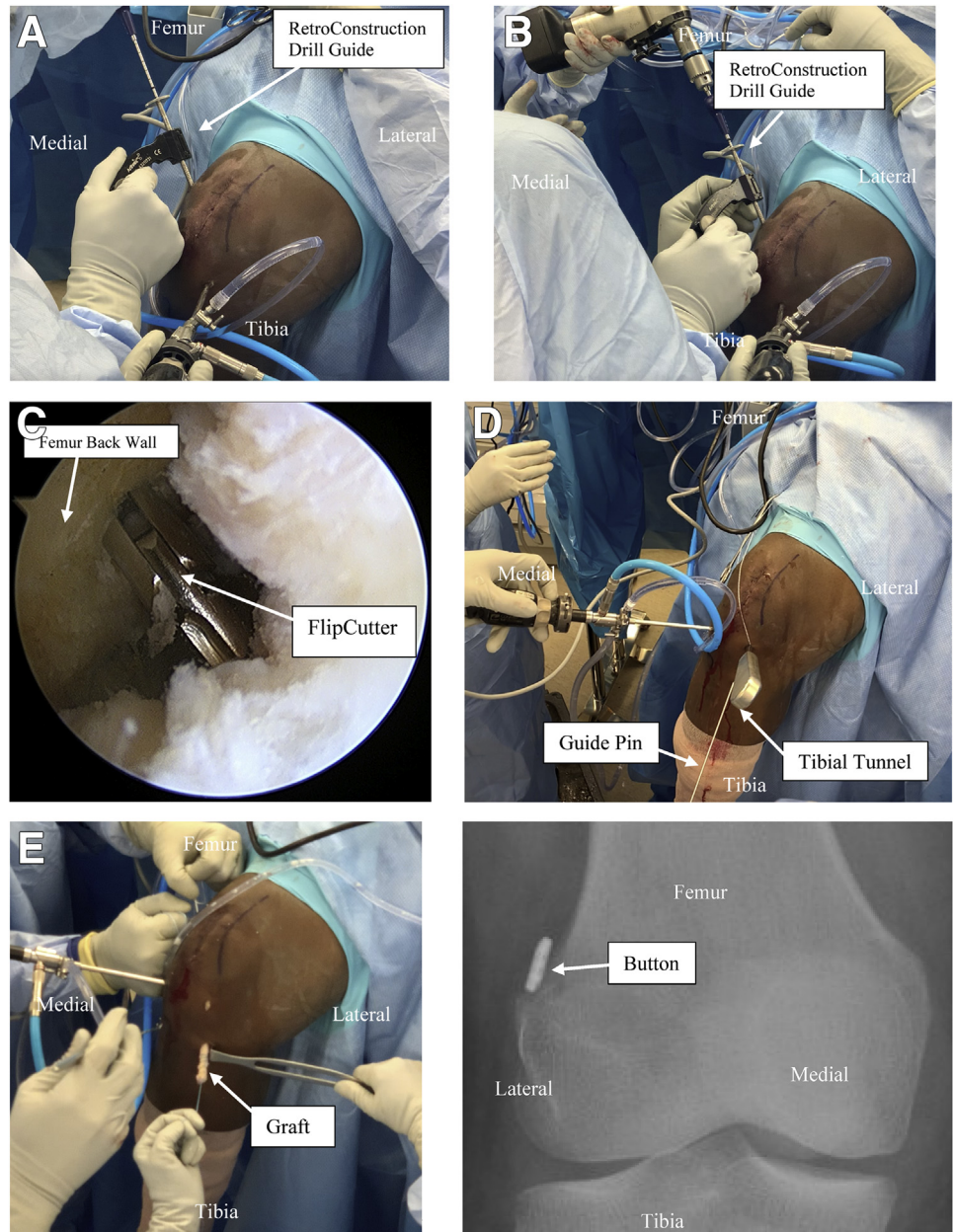


Fig 3. (A) The femur is prepared using the RetroConstruction Drill Guide System and FlipCutter. (B) The femoral tunnel is reamed to appropriate length for the intra-osseous section of the graft. (C) The back wall of the femur is then viewed to confirm an intact back wall. (D) A guide pin is then inserted, and the appropriately sized reamer is used to create the tibial tunnel. (E) A femoral loop suspensory fixation device is then passed from the tibial tunnel to the femoral tunnel using a free suture as a shuttle. (F) The femoral button is then visualized to pass through the outside of the femoral tunnel and confirmed fluoroscopically.

pouch can be reapproximated using Vicryl suture.¹⁶ Furthermore, the use of suspensory fixation does not allow for bone-to-bone healing present in bone tendon bone ACLR. It should be noted, however, that although bone-to-bone healing is not possible, suspensory fixation has shown excellent fixation strength.^{17,18} Finally, no ACLR technique is guaranteed to prevent re-tear; it is recommended to closely monitor patients after surgery, working with therapists and trainers to determine when an athlete can safely return to sport.

Although the literature has shown satisfactory post-operative clinical outcomes in regard to the use of quadriceps autografts for ACL reconstructions, further

studies are needed to evaluate outcomes and validate the suspected benefits of using the QuadLink ACL FiberTag for graft fixation. The QuadLink graft fixation technique remains an underused and promising option for ACL reconstructions.

References

1. Bokshan SL, Mehta S, DeFroda SF, Owens BD. What Are the primary cost drivers of anterior cruciate ligament reconstruction in the United States? A cost-minimization analysis of 14,713 patients. *Arthroscopy* 2019;35:1576-1581.
2. Wasserstein D, Sheth U, Cabrera A, Spindler KP. A systematic review of failed anterior cruciate ligament

- reconstruction with autograft compared with allograft in young patients. *Sports Health* 2015;7:207-216.
3. Mulford JS, Hutchinson SE, Hang JR. Outcomes for primary anterior cruciate reconstruction with the quadriceps autograft: A systematic review. *Knee Surg Sports Traumatol Arthrosc* 2013;21:1882-1888.
 4. Akoto R, Hoehner J. Anterior cruciate ligament (ACL) reconstruction with quadriceps tendon autograft and press-fit fixation using an anteromedial portal technique. *BMC Musculoskelet Disord* 2012;13:161.
 5. Nyland J, Collis P, Huffstutler A, et al. Quadriceps tendon autograft ACL reconstruction has less pivot shift laxity and lower failure rates than hamstring tendon autografts. *Knee Surg Sports Traumatol Arthrosc* 2020;28:509-518.
 6. Shani RH, Umpierrez E, Nasert M, Hiza EA, Xerogeanes J. Biomechanical comparison of quadriceps and patellar tendon grafts in anterior cruciate ligament reconstruction. *Arthroscopy* 2016;32:71-75.
 7. Slone HS, Ashford WB, Xerogeanes JW. Minimally invasive quadriceps tendon harvest and graft preparation for all-inside anterior cruciate ligament reconstruction. *Arthrosc Tech* 2016;5:e1049-e1056.
 8. Lippe J, Armstrong A, Fulkerson JP. Anatomic guidelines for harvesting a quadriceps free tendon autograft for anterior cruciate ligament reconstruction. *Arthroscopy* 2012;28:980-984.
 9. Browning WM 3rd, Kluczynski MA, Curatolo C, Marzo JM. Suspensory versus aperture fixation of a quadrupled hamstring tendon autograft in anterior cruciate ligament reconstruction: A meta-analysis. *Am J Sports Med* 2017;45:2418-2427.
 10. Lubowitz JH, Ahmad CS, Anderson K. All-inside anterior cruciate ligament graft-link technique: Second-generation, no-incision anterior cruciate ligament reconstruction. *Arthroscopy* 2011;27:717-727.
 11. Staeubli HU, Bollmann C, Kreutz R, Becker W, Rauschnig W. Quantification of intact quadriceps tendon, quadriceps tendon insertion, and suprapatellar fat pad: MR arthrography, anatomy, and cryosections in the sagittal plane. *AJR Am J Roentgenol* 1999;173:691-698.
 12. Adams DJ, Mazzocca AD, Fulkerson JP. Residual strength of the quadriceps versus patellar tendon after harvesting a central free tendon graft. *Arthroscopy* 2006;22:76-79.
 13. Moutzouros V, Jildeh TR, Khalil LS, et al. A multimodal protocol to diminish pain following common orthopedic sports procedures: Can we eliminate postoperative opioids? *Arthroscopy* 2020;36:2249-2257.
 14. Woo SL, Hollis JM, Adams DJ, Lyon RM, Takai S. Tensile properties of the human femur-anterior cruciate ligament-tibia complex. The effects of specimen age and orientation. *Am J Sports Med* 1991;19:217-225.
 15. Guney-Deniz H, Harput G, Kaya D, Nyland J, Doral MN. Quadriceps tendon autograft ACL reconstructed subjects overshoot target knee extension angle during active proprioception testing. *Knee Surg Sports Traumatol Arthrosc* 2020;28:645-652.
 16. Perez JR, Emerson CP, Barrera CM, et al. Patient-reported knee outcome scores with soft tissue quadriceps tendon autograft are similar to bone-patellar tendon-bone autograft at minimum 2-year follow-up: A retrospective single-center cohort study in primary anterior cruciate ligament reconstruction surgery. *Orthop J Sports Med* 2019;7:2325967119890063.
 17. Born TR, Biercevicz AM, Koruprolu SC, Paller D, Spenciner D, Fadale PD. Biomechanical and computed tomography analysis of adjustable femoral cortical fixation devices for anterior cruciate ligament reconstruction in a cadaveric human knee model. *Arthroscopy* 2016;32:253-261.
 18. Mickelson DT, Lefebvre T, Gall K, Riboh JC. Adjustable-loop femoral cortical suspensory fixation for patellar tendon anterior cruciate ligament reconstruction: A time zero biomechanical comparison with interference screw fixation. *Am J Sports Med* 2018;46:1857-1862.