

Surgical Reconstruction after Resection of a Large Myxofibrosarcoma of the Upper Extremity*

Reconstrução cirúrgica após excisão de extenso mixofibrossarcoma do membro superior

Kátia Tôres Batista¹ Valney Claudino Sampaio Martins¹ Ulises Prieto y Schwartzman¹
Telma Leonel Ferreira¹

¹ Rede Sarah de Hospitais de Reabilitação, Brasília, DF, Brazil

Rev Bras Ortop 2019;54:353–356.

Address for correspondence Kátia Tôres Batista, Rede Sarah de Hospitais de Reabilitação, Brasília, DF, Brazil
(e-mail: katiatb@terra.com.br).

Abstract

Myxofibrosarcoma is a rare soft tissue sarcoma. The authors present a case report regarding the excision and reconstruction of an extensive low-grade myxofibrosarcoma in the forearm, in the wrist, and in the hand of a young woman. A large-scale monobloc excision was performed according to resonance magnetic imaging (MRI) and transoperative histopathologic study findings. A dermal matrix and total skin graft associated with a postoperative physiotherapy program were used. The aspects related to the differential diagnosis of myxofibrosarcoma in a young patient, its infiltrative character, the extensive excision, the reconstruction in two surgical times (using a dermal matrix and a full-thickness skin graft), and the postoperative physical therapy program were considered important.

Keywords

- ▶ sarcoma
- ▶ soft tissue neoplasms
- ▶ rehabilitation

Resumo

O mixofibrossarcoma é um raro sarcoma de partes moles. Os autores apresentam o relato de um caso, em mulher jovem, de exeres e reconstrução de extenso mixofibrossarcoma de baixo grau localizado no antebraço, no punho e na mão. Fez-se a exeres ampla em monobloco conforme achados de ressonância magnética e estudo histopatológico transoperatório. Usaram-se a matriz dérmica e o enxerto de pele total associado a programa fisioterápico pós-operatório. Os aspectos relacionados ao diagnóstico diferencial do mixofibrossarcoma em paciente jovem, seu caráter infiltrativo, a ampla excisão, a reconstrução em dois tempos cirúrgicos (com o uso de matriz dérmica e enxerto de pele total) e o programa fisioterápico pós-operatório são relevantes.

Palavras-chave

- ▶ sarcoma
- ▶ neoplasias de tecidos moles
- ▶ reabilitação

Introduction

Myxofibrosarcoma is a rare tumor originating from connective tissue, previously known as myxoid variant of malignant fibrous histiocytoma. It occurs mainly in the elderly (60–80 years old), rarely before the second decade of life, and it affects extremities (75%), the trunk (12%), and the mediastinum (8%).^{1,2}

Half of the cases originate in the dermis and in subcutaneous tissue, while the remaining arise in fascias and muscles. Histologically, it is characterized by a multinodular growth with a myxoid stroma of neoplastic fibroblast cells with mucin vacuoles. Low-grade lesions are hypocellular, consisting of few noncohesive, spindle-shaped or stellar cells with poorly defined cytoplasm and hyperchromatic nuclei and infrequent mitoses; high-grade lesions consist of spindle cell fascicles and pleomorphic cells with numerous mitoses,

* Work developed at the Rede Sarah de Hospitais de Reabilitação, Brasília, DF, Brazil.



atypia, and areas of necrosis. Tumor cells are vimentin-positive in immunohistochemical studies.³

Magnetic resonance imaging (MRI) findings are nonspecific and heterogenic; a myxoid stroma may be evidenced. Differential diagnosis should consider other soft tissue tumors. Treatment includes wide monobloc excision. Local recurrence is observed in between 50 and 60% of the cases, regardless of the histologic grade.³⁻⁶ The aim of the present study was to describe the surgical reconstruction in a case of extensive myxofibrosarcoma in the upper limb.

Case Report

A 23-year-old female patient reported that for 2 years she had pain, edema and swelling in her left hand, wrist and forearm. An MRI exam showed a possible hemangioma. The patient was treated with painkillers and steroid injections in another medical facility. On admission, she presented with pain, and the physical examination showed a swelling on the left hand, on the wrist, and on the forearm, with indistinct lesion borders.

A new MRI revealed an extensive, elongated, infiltrative lesion with indistinct margins affecting the subcutaneous tissue, with a circumferential appearance on the back, lateral, and medial faces of the left distal forearm and hand (►Fig. 1). A biopsy and an immunohistochemical study were performed and demonstrated a myxofibrosarcoma (►Fig. 2). The findings of a computed tomography (CT) scan of the chest were normal. The tumor, measuring 20 × 11 × 1.5 cm in the suprafascial plane (fascia, subcutaneous cellular tissue, and skin), was excised from the dorsum of the hand, from the wrist, and from the forearm under general anesthesia and brachial plexus block. Reconstruction was performed with a 10 × 10 cm dermal matrix (Integra) over the extensor tendons, activated charcoal bandages, and immobilization with a below-elbow splint (►Fig. 3). Patient-controlled continuous analgesia in the brachial plexus was established with ropivacaine 0.2% at 5 mL/hour, in 5 mL bolus and 30-minute block interval, and cefazolin, 200 mg in a single

dose. The bandages were changed weekly under anesthesia. On the 21st day, margin expansion was performed on the back of the 3rd and 4th digits, and a 20 × 10 cm total skin graft was removed from the lower abdomen, with a dressing attached to the graft, and primary closure of the donor area (►Fig. 4). The dressing was changed in 1 week, and the complete integration of the skin graft was observed. The patient was referred to physical therapy, composed of oily substance, compressive mesh, flexion glove, sun protection, tendinous mobilization and stretching, and dynamic bracing with elastics and swirl (►Fig. 5).

The histopathological examination revealed a diffuse, tumor-like thickening of the skin, subcutaneous cellular tissue and fascia at the distal and middle third of the surgical specimen, and gelatinous nodules infiltrating the entire thickness and touching the limits of the lesion. The microscopic analysis showed a low-grade myxofibrosarcoma (according to the Fédération Nationale des Centres de Lutte Contre le Cancer [FNCLCC, in the French acronym]) without vascular invasion, while the karyotype analysis revealed a normal clone and an abnormal one with alterations in chromosomes 1,3 and 10 and translocations in chromosomes 8 and 1943~45,XX,der(1;3)t(1;3)p31;p21,3)dic(8,19)q24,p13,3)der(10),t(1;10),p31;q25), rob(13;21)(q10;q10)15/46XX(5). There was no recurrence during the 1-year follow-up.

Discussion

Depending on the degree of cellularity, nuclear pleomorphism, and mitotic activity, myxofibrosarcomas are classified into three histological grades: low, intermediate, and high grade.^{1,2} In the present case, the nonspecific physical and imaging features initially led to the misdiagnosis of a benign lesion, delaying treatment for > 2 years. The MRI scans showed characteristic images, such as the high signal in T2-weighted images seen in myxoid tumors, and a low signal in those with fibrosis. Although the nuclear magnetic resonance (NMR) findings did not confirm the diagnosis, they helped the surgical planning.

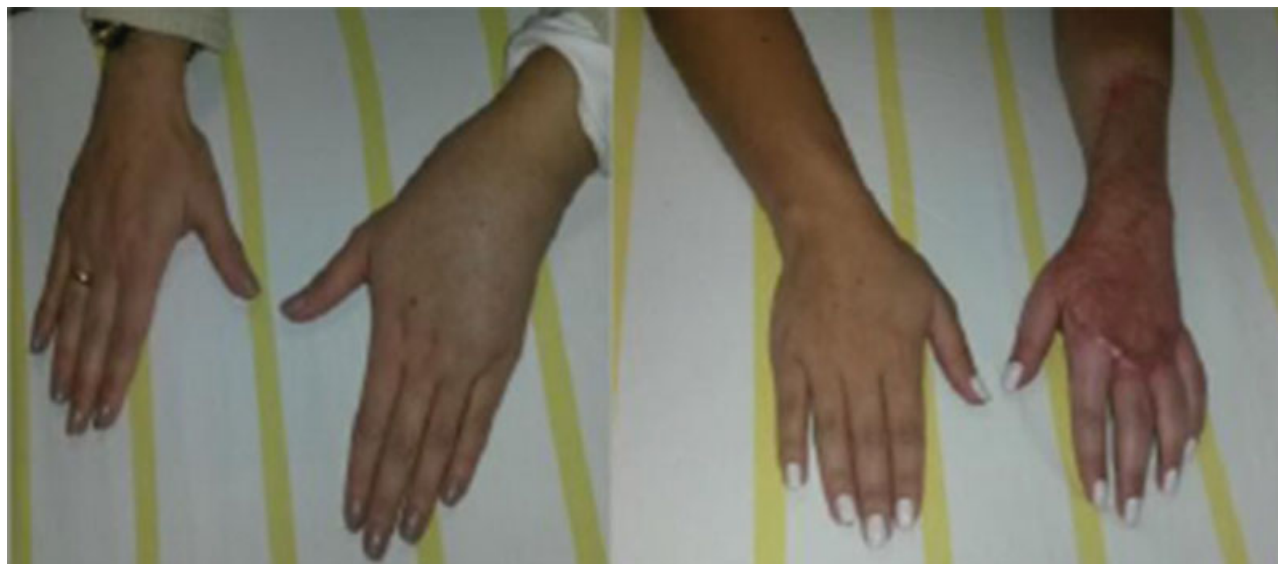

Fig. 1 A, admission; B, 1st month after the surgery.

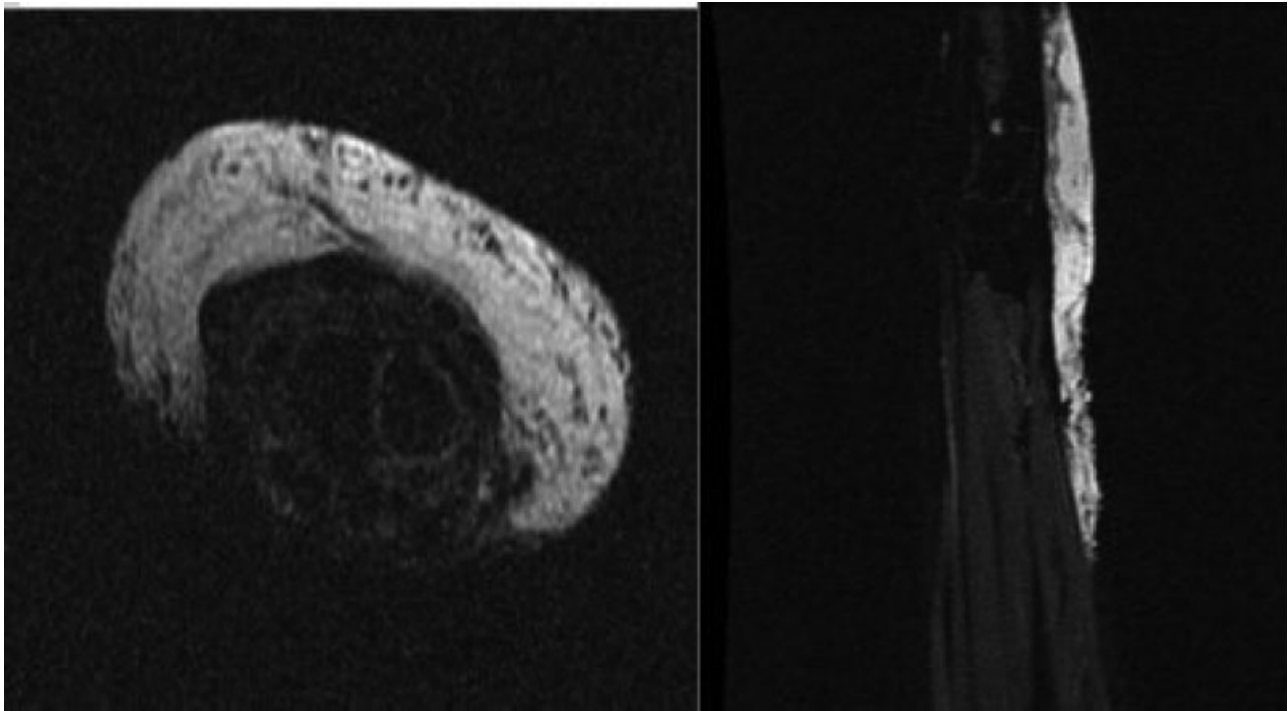


Fig. 2 Nuclear magnetic resonance (NMR) imaging (Ax GRE T2) showing a lesion deeply infiltrating the skin and the subcutaneous tissue along the extensor retinaculum, with a longitudinal extension of $19 \times 8.5 \times 1.7$ cm (from the medial-distal third plane of the radius to the proximal digital phalanges), hypointense signal (T1) with intermixed areas of high signal indicating fat tissue and high signal (T2/STIR) with a slight contrast enhancement, leading to a suspicion of hemangioma.

Antigen	Result	Intensity	Distribution
CD34/Qend/10/Novocastra	Positive	Strong	Diffuse
GFAP/6F2/Dako	Negative		
S100/Policlonal/Dako	Negative		
Mucin-4(MUC4)/8G7/Santa Cruz	Inconclusive		

Fig. 3 Immunohistochemical study results.

Reconstruction after tumor excision was performed in two stages. In the first stage, the dermal replacement material was kept for 3 weeks, whereas the second stage used a total skin graft. Reconstruction after the excision of extensive tumors use skin grafts, local flaps, and distant flaps; most recently, dermal matrix or negative pressure dressing systems are applied.⁷ In the 1980s, Yannas et al^{8,9} introduced the dermal substitute used up to this day in a variety of wounds. Moiemmen et al¹⁰ performed studies evaluating the stages of healing in the dermal matrix, as well as its imbibition, cell migration, neovascularization, remodeling, and maturation. The dermal matrix was important to protect exposed tendons lacking their peritendium and to stimulate the formation of a graft-favoring granulation tissue when the histological result was obtained, and skin grafting was performed.

The late reconstruction allowed for the definitive histological outcome of the tumor and surgical margins, allowing the widening of the dubious margins on the back of the 3rd and 4th digits, which eventually were negative. One concern

regarding myxofibrosarcomas is local recurrence due to the diffuse growth, to the infiltrative nature, and to the difficult definition of the surgical margin during surgery. The prognosis depends on the histological grade and size of the initial tumor. Low-grade tumors have an indolent biological behavior, with a local recurrence of between 50 and 60%, but no metastases. High-grade lesions have a risk of metastases to the lungs, bones, and lymph nodes of between 30 and 50%. The depth of the lesion does not influence the local recurrence rate, although deep neoplasms have a higher percentage of metastases and associated mortality, with a 5-year survival of between 60 and 70%.² Although the follow-up without relapse was of 1 year, there are reports of recurrence rate in 25% of the cases in the first 5 years after excision.^{2,11}

The presentation of the present case was important as an alert for the differential diagnosis of low-grade myxofibrosarcoma with other conditions in the upper limb of young patients, and the possibility of extensive excision with anatomical and functional reconstruction after histopathological

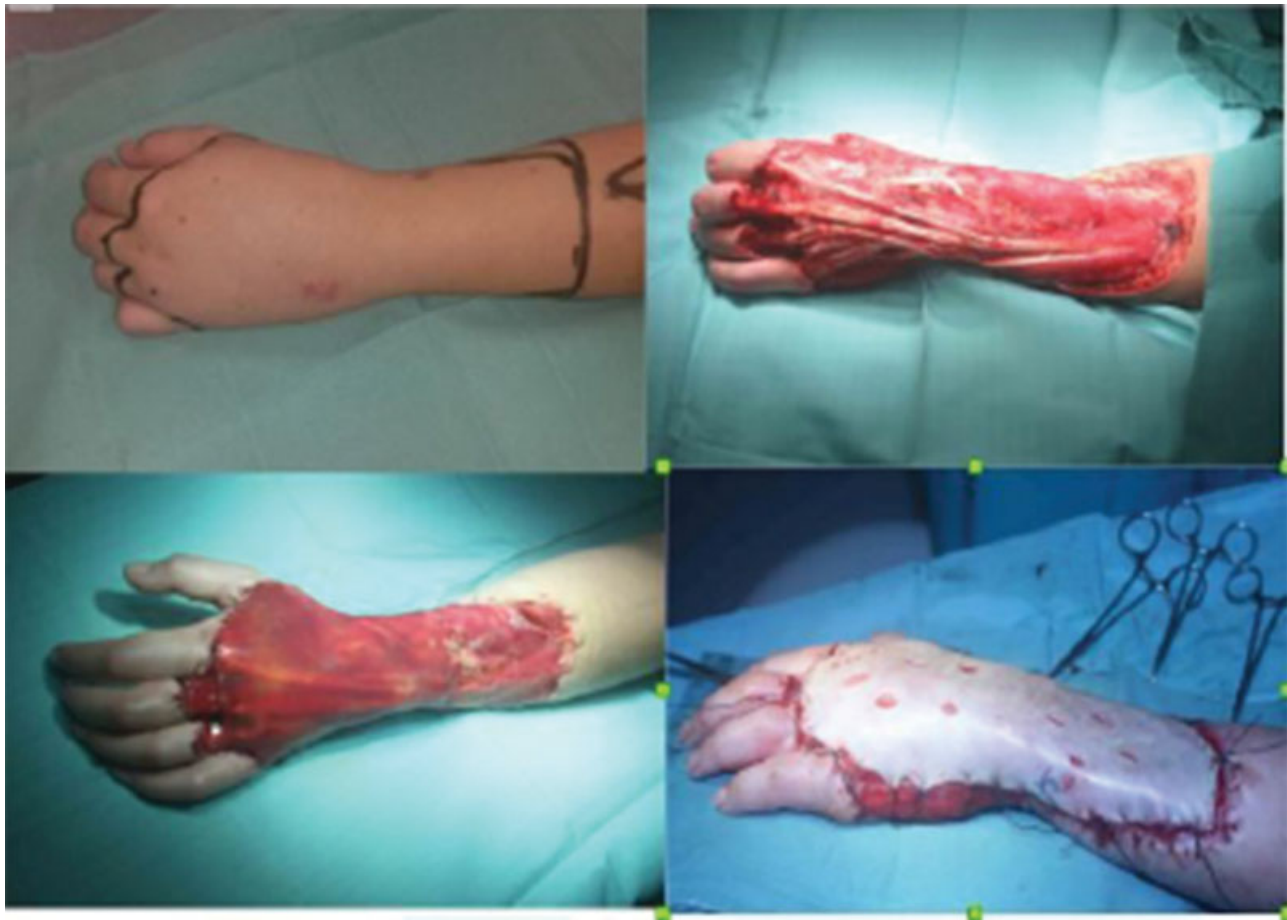


Fig. 4 Transoperative period of tumor resection. A, intraoperative marking; B, wide resection; C, reconstruction with dermal matrix; D, second surgical time with total skin graft.

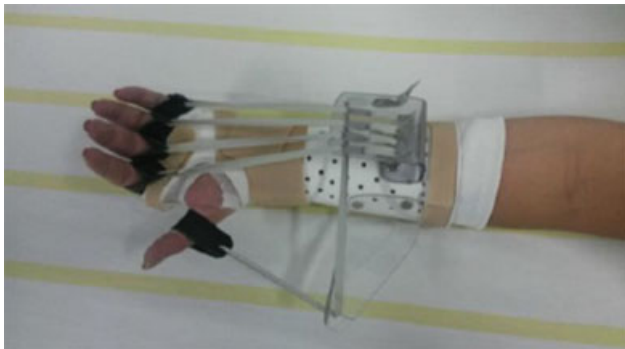


Fig. 5 Dynamic bracing for physical therapy exercises.

examination with dermal matrix and skin grafting despite the extent and the infiltrative nature of the tumor.

Conflicts of Interests

The authors have no conflicts of interests to declare.

References

- Jagannathan JP, Tirumani SH, Ramaiya NH. Imaging in soft tissue sarcomas: current updates. *Surg Oncol Clin N Am* 2016;25(04): 645–675
- Dobke M, Mackert GA. Upper extremity sarcoma: impact of current practice guidelines and controversies on reconstructive approaches. *SICOT J* 2017;3:15
- Jagtap SV, Jain A, Jagtap SS, Kshirsagar AY. High-grade myxofibrosarcoma-presented as a large mass of right upper arm. *Indian J Pathol Microbiol* 2015;58(01):105–107
- Arnaoutoglou C, Lykissas MG, Gelalis ID, Batistatou A, Goussia A, Doukas M, et al. Low grade fibromyxoid sarcoma: a case report and review of the literature. *J Orthop Surg Res* 2010;5:49
- Fletcher CDM, Bridge JA, Hogendoorn PCW, Mertens F. WHO classification of tumors of soft tissue and bone. 4th ed. Lyon: IARC Press; 2013
- Clarke LE, Zhang PJ, Crawford GH, Elenitsas R. Myxofibrosarcoma in the skin. *J Cutan Pathol* 2008;35(10):935–940
- Bickels J, Kollender Y, Wittig JC, Cohen N, Meller I, Malawer MM. Vacuum-assisted wound closure after resection of musculoskeletal tumors. *Clin Orthop Relat Res* 2005;441(441):346–350
- Yannas IV, Burke JF, Orgill DP, Skrabut EM. Wound tissue can utilize a polymeric template to synthesize a functional extension of skin. *Science* 1982;215(4529): 174–176
- Yannas IV, Lee E, Orgill DP, Skrabut EM, Murphy GF. Synthesis and characterization of a model extracellular matrix that induces partial regeneration of adult mammalian skin. *Proc Natl Acad Sci U S A* 1989;86(03):933–937
- Moiemen NS, Staiano JJ, Ojeh NO, Thway Y, Frame JD. Reconstructive surgery with a dermal regeneration template: clinical and histologic study. *Plast Reconstr Surg* 2001;108(01):93–103
- Trovik CS, Skjeldal S, Bauer H, Rydholm A, Jebsen N. Reliability of Margin Assessment after Surgery for Extremity Soft Tissue Sarcoma: The SSG Experience. *Sarcoma* 2012;2012:290698