

# CT features of low grade serous carcinoma of the ovary

Harpreet K. Pannu\*

Department of Radiology, Memorial Sloan Kettering Cancer Center, United States

Received 30 October 2014; accepted 19 January 2015

Available online 3 February 2015

## Abstract

**Objective:** To evaluate the CT features of pathologically proven low grade serous carcinoma (LGSC) of the ovary.

**Methods:** Patients with a pathologic diagnosis of LGSC and CT prior to oophorectomy were retrospectively identified. The CT scans in 14 patients were available and were analyzed for an adnexal mass, peritoneal mass and ascites. The adnexal mass was characterized as complex primarily cystic, mixed cystic solid, or primarily solid. Calcification in the adnexal and peritoneal masses and nodes was noted.

**Results:** Pathology revealed 6 patients had LGSC and 8 patients had a combined diagnosis of LGSC and serous borderline tumor (SBT) of the ovary. Of the 6 patients with only LGSC, 4 had primarily solid or mixed solid cystic adnexal masses and 5 had peritoneal masses. Calcification was present in the adnexal and peritoneal masses in 4 patients, and in nodes in 2 patients. Of the 8 patients with co-existing LGSC and SBT, 7 had complex primarily cystic adnexal masses and 6 had peritoneal masses. Calcification was present in the adnexal and peritoneal masses in 5 patients and in nodes in 2 patients.

**Conclusion:** LGSC can appear as a solid, mixed solid cystic, or complex primarily cystic ovarian mass, and the appearance may be due to a co-existing SBT. Calcification of the adnexal and peritoneal masses appears to be common. LGSC is a diagnostic consideration in patients with a calcified adnexal mass and concurrent peritoneal masses or calcified nodes on CT.

© 2015 The Authors. Published by Elsevier Ltd. This is an open access article under the CC BY-NC-ND license (<http://creativecommons.org/licenses/by-nc-nd/4.0/>).

**Keywords:** Low grade serous carcinoma; Ovary; Computed tomography

## 1. Introduction

Serous carcinomas are the most common epithelial malignancy of the ovary. These were previously graded by pathologists using a three-tier system as low, intermediate or high grade tumors [1]. In recent years there has been a shift to a two-tier grading system classifying tumors as either low grade or high grade [2,3]. Low grade and high grade serous carcinomas of the ovary have differing histologic appearances, types of genetic mutations, clinical presentations, responsiveness to chemotherapy and prognosis [1,2]. Low grade serous carcinomas are less common than high grade serous carcinomas. To our knowledge, the imaging appearance of low grade serous carcinoma (LGSC) of the ovary has not been previously described in the radiologic

literature. The CT appearance of this tumor is described in this report.

## 2. Methods

### 2.1. Patient population

An institutional review board waiver was approved for this retrospective study. A combined search of the radiology and pathology database was performed to identify patients with a pathologic diagnosis of low grade serous carcinoma involving the ovary as well as cross-sectional imaging studies in PACS over an 8-year period. 48 patients were identified, of whom 25 had preoperative CT prior to oophorectomy.

After review of the pathology reports, 7 patients were excluded either due to lack of LGSC in the ovary ( $n=5$ ) or only microscopic foci of LGSC in the ovary ( $n=2$ ) at pathology. 4 of these patients had serous borderline tumors of the ovaries with low grade serous carcinoma peritoneal implants (three

\* Correspondence to: Department of Radiology, Memorial Sloan-Kettering Cancer Center, 1275 York Avenue, New York, NY 10065, United States.  
Tel.: +1 646 888 5421.

E-mail address: [pannuh@mskcc.org](mailto:pannuh@mskcc.org)

synchronously and 1 metachronously 6 years later). 1 patient did not have a definitive diagnosis of low grade serous carcinoma the patient had a borderline tumor in the ovary with implants that were possibly low grade serous carcinoma. 1 patient had a borderline tumor of the ovary with a microscopic focus of low grade serous carcinoma. 1 patient had microscopic foci of low grade serous carcinoma on the surface of one ovary but no preoperative imaging of the low grade serous carcinoma in the contralateral ovary. Of the remaining 18 patients, 4 patients only had digitized film of the CT scans in PACS and were therefore excluded from analysis.

The remaining 14 patients formed the study group. The patients had a mean age of 53 years (range 23–76 years). The CT was performed prior to chemotherapy in 12 of the 14 patients. In 10 patients a single preoperative CT was available, and was performed a median of 20 days (range 5–51 days) prior to oophorectomy. 9 of these 10 patients had no neoadjuvant chemotherapy.

In 4 patients, multiple CT scans were available prior to oophorectomy. The initial scan was prior to chemotherapy in 3 of the 4 patients and was performed a median of 174 days (range 89–295 days) prior to oophorectomy. 3 of the 4 patients each had 3 CT scans and 1 patient had 2 CT scans prior to oophorectomy. The final CT scan prior to oophorectomy was performed a median of 30 days (range 9–49 days) before surgery. For the 4 patients with multiple CT scans, the initial CT was used for describing the tumor findings in [Tables 1 and 2](#) while the findings on followup CT are noted in [Table 3](#).

## 2.2. CT technique

CT of the abdomen and pelvis was done in 13 patients, and 1 patient (patient number 10) only had a pelvic CT. CT was done with oral and intravenous contrast in 10 patients, with only oral contrast in 3 patients (patient numbers 4, 5, 11) and with only intravenous contrast in 1 patient (patient number 3). In 2 patients, multiphase studies were available to assess for change in density. 1 patient (patient number 9) had pre and post intravenous contrast phase images. 1 patient (patient number 14) had post intravenous contrast images in the renal corticomedullary and excretory phases.

## 2.3. Analysis of CT images

An abdominal radiologist, with greater than 15 years of postfellowship experience in CT, evaluated each CT for the following characteristics – presence of an adnexal mass, peritoneal implants, calcified nodes and ascites.

The adnexal masses were characterized as primarily (>75%) cystic, mixed cystic solid, or primarily (>75%) solid. In addition to the following CT criteria, the solid or cystic nature of the mass was corroborated by ultrasound in 3 patients, by MRI in 3 patients, by both ultrasound and MRI in 1 patient, and by subsequent multiphase CT in 1 patient. The presence of a cystic or solid component in the adnexal mass was corroborated by the gross pathologic description in 10 patients.

On CT, a component of the lesion was classified as cystic if it met one of the following criteria – attenuation <40 HU, or if there were visible internal septations or mural nodularity, or if there was absence of enhancement on a multiphase study. The attenuation of the cystic component was recorded by placing a region of interest encompassing at least two thirds of the component on an axial slice (region of interest ROI size median 764 mm<sup>2</sup> range 52–6293 mm<sup>2</sup>). A component of the lesion was classified as solid if it met one of the following criteria – central calcifications, density greater than pelvic muscle, or evidence of enhancement on a multiphase study.

As the bilateral adnexal masses and multiple peritoneal masses were confluent in some cases and the omental plaque had variable measurements depending on the axial slice, the largest measurement of the adnexal and peritoneal masses was obtained on an axial slice and the masses were classified as <1 cm, 1–5 cm or >5 cm in size. Calcification was noted as present or absent in the adnexal and peritoneal masses. The presence of calcified abdominal, pelvic and anterior diaphragmatic nodes was also noted. Ascites was recorded as present or absent and qualitatively categorized as minimal, small, moderate or large in volume. In patients who had multiple CT studies prior to surgical resection, change in the morphology of the primary and metastatic masses was qualitatively assessed.

## 3. Results

### 3.1. Pathology results

6 patients had low grade serous carcinoma without associated serous borderline tumor while 8 patients had a combined diagnosis of low grade serous carcinoma and serous borderline tumor. For the 6 patients with only low grade serous carcinoma at pathology, the tumor involved both ovaries in all cases, and was possibly peritoneal in origin in 2 patients.

For the 8 patients with a combined diagnosis of low grade serous carcinoma (LGSC) and serous borderline tumor (SBT) of the ovary, both tumors were present bilaterally in 3 patients. 2 patients had a co-existing LGSC and SBT in one ovary and a LGSC in the contralateral ovary. 1 patient had a co-existing LGSC and SBT in one ovary and a SBT in the contralateral ovary. 1 patient had a co-existing LGSC and SBT in one-ovary and tumor emboli in the hilar vessels of the contralateral ovary. 1 patient with a remote history of unilateral oophorectomy for a benign cyst had a co-existing LGSC and SBT in the remaining contralateral ovary.

### 3.2. CT findings

[Table 1](#) gives the CT findings in 6 patients with low grade serous carcinoma without co-existing serous borderline tumor. The tumors were primarily solid or mixed solid cystic in 4 of the 6 patients ([Fig. 1](#)). 1 patient had a primarily cystic mass with mural nodularity. 1 patient had a complex adnexal mass that was indeterminate for solid or cystic lesion on CT. Calcification was

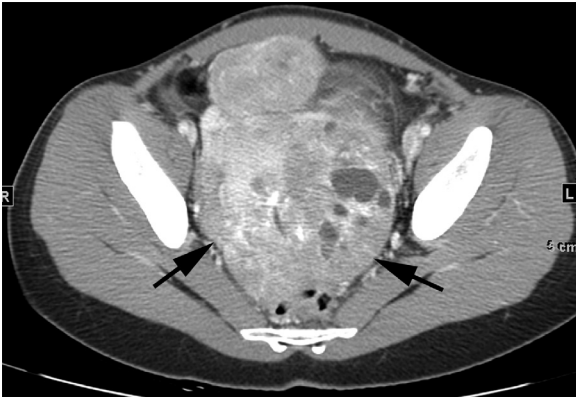

Fig. 1. Low grade serous carcinoma without borderline tumor. Patient 7 is a woman in her 20s. CT with intravenous contrast shows a primarily solid pelvic mass (arrows) with scattered calcifications and small cystic regions.

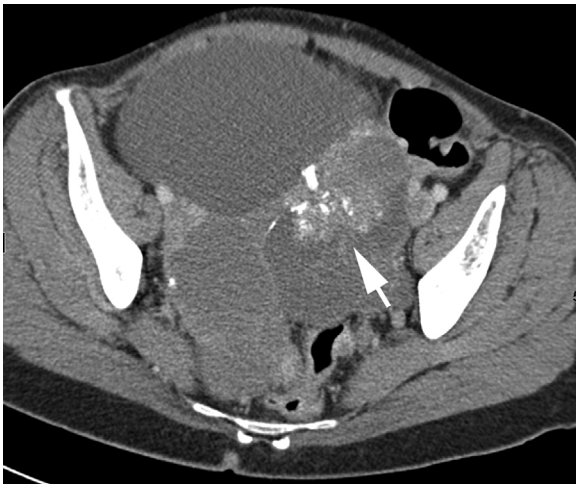


Fig. 2. Low grade serous carcinoma with co-existing serous borderline tumor. Patient 8 is a woman in her 60s. CT with intravenous contrast shows a primarily cystic pelvic mass with partially calcified soft tissue component (arrow).

present in about half of the adnexal masses (7 of 12 ovaries). Peritoneal masses were present in 5 of the 6 patients. Calcified peritoneal masses were seen in patients with calcified adnexal masses. 2 patients also had calcified nodes. Ascites was minimal or small in volume in 5 patients.

Table 2 gives the CT findings in 8 patients with low grade serous carcinoma present in conjunction with serous borderline tumor. The tumors were complex primarily cystic lesions in 7 of the 8 patients, 4 of whom had co-existing soft tissue nodules, and 3 of whom had septations (Fig. 2). 1 patient had a solid adnexal mass (Fig. 3). Calcification was present in half of the adnexal masses (7 of 14 ovaries). Peritoneal masses were present in 6 of the 8 patients. Calcified peritoneal masses were seen in patients with calcified and noncalcified adnexal masses. 2 patients also had calcified nodes. In the 3 patients with differing pathology between the right and left ovaries, i.e. co-existing LGSC and SBT in one ovary and a LGSC or SBT in the contralateral ovary, there was no visible difference in morphology on CT. Ascites

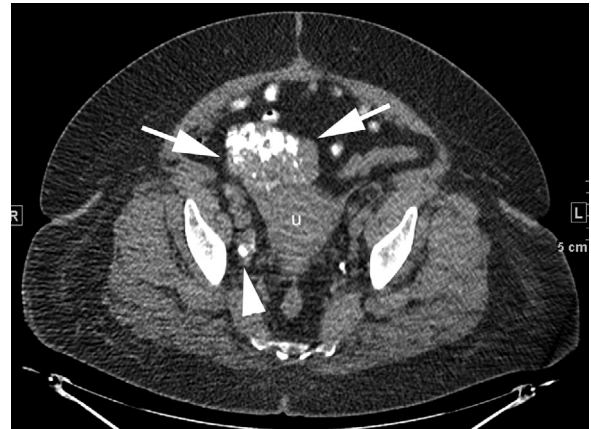


Fig. 3. Low grade serous carcinoma with co-existing serous borderline tumor. Patient 5 is a woman in her 60s. CT with oral contrast shows a calcified right adnexal mass (arrows) abutting uterus (u). Calcified right iliac node (arrowhead) is also present. Oral contrast is in small bowel loops in the anterior pelvis.

was absent in 5 patients and was minimal or small in volume in 3 patients.

Table 3 gives the CT findings in 4 patients who had multiple CT scans prior to oophorectomy. All patients received neoadjuvant chemotherapy. Increased calcification of the adnexal, peritoneal and nodal masses was noted on the followup study (Fig. 4). There was no development of significant ascites.

#### 4. Discussion

Serous carcinoma comprises 85% of epithelial ovarian malignancies [1]. The majority are high grade serous carcinomas (HGSC) while an estimated 3–10% are low grade serous carcinomas (LGSC) [1,2,4]. Significant clinical, pathologic, and pathogenesis differences have been described between LGSC and HGSC. Patients with LGSC tend to be younger than patients with HGSC and to have a better survival. In one study, mean age and mean survival were 55 years and 99 months for LGSC and 63 years and 57 months for HGSC [5]. At pathology, LGSC and HGSC differ in the degree of nuclear atypia and mitotic rate with less atypia and fewer mitoses in LGSC [4]. On a genetic level, KRAS or BRAF genetic mutations are seen in LGSC while TP53 mutations are more common in HGSC [6]. LGSC is theorized to arise more slowly from precursor lesions while HGSC develops more rapidly possibly arising from tubal intraepithelial carcinoma [6]. The pathogenesis of LGSC is believed to occur step-wise from cystadenoma to atypical proliferative serous tumor (APST) to noninvasive micropapillary serous borderline tumor (SBT) to low grade serous carcinoma (LGSC) [6].

This development of LGSC from serous borderline tumors likely accounts for the association between the two entities in the literature as well as in our study [3]. Approximately 60% of LGSC are reported to be associated with a SBT and patients with advanced stage SBT often recur as LGSC [1]. The distinction between LGSC and SBT is made based on the presence of destructive stromal invasion in LGSC on histology [1]. Given the microscopic nature of this distinction, distinguishing the LGSC and SBT components in ovaries with both lesions on a gross scale

Table 1  
Low grade serous carcinoma *without* borderline tumor.

Pt	Adnexal mass		Peritoneal implants Calcification/mass size		Calcified nodes	Ascites
	Right	Left	Pelvic	Abdominal		
1	Solid 1–5 cm mass with calcification	Solid 1–5 cm mass with calcification	Calcified > 5 cm	Calcified > 5 cm	Diaph 1 cm <sup>^</sup> Abd 1–2 cm <sup>^</sup> Ing > 2 cm	Minimal
2	Solid 1–5 cm mass without calcification	Mass > 75% solid with calcification Mass > 5 cm	Calcified 1–5 cm	Calcified > 5 cm	Diaph < 1 cm <sup>^</sup> Iliac > 2 cm Ing < 1 cm <sup>^</sup>	Small
3	Mass > 75% cystic 10 HU with mural nodularity without calcification Mass > 5 cm	Mass > 75% cystic 19 HU without calcification Mass 1–5 cm	Noncalcified < 1 cm	Noncalcified 1–5 cm	None*	Minimal
7	Solid > 5 cm mass with calcification	Mixed solid cystic > 5 cm mass with calcification	Calcified > 5 cm	Noncalcified 1–5 cm	None	Minimal
9	Mixed solid cystic > 5 cm mass with calcification	Mixed solid cystic > 5 cm mass with calcification	Calcified 1–5 cm	Calcified > 5 cm	None*	Minimal
10	Noncalcified ovary 1–5 cm	Mixed density cystic vs. solid > 5 cm mass with punctate calcification	None <sup>^</sup>	No abdominal CT available	None <sup>^</sup>	None

All patients had bilateral ovarian involvement with low grade serous carcinoma.

I. Additional imaging findings:

- In patient 9 – attenuation on precontrast/post IV contrast images – right ovary cystic part 16 HU/23 HU, right ovary solid part 45 HU/77 HU, left ovary cystic part 15 HU/23 HU, left ovary solid part 49 HU/76 HU.
- In patient 10 – left adnexal mass had a 38 HU locule and a 60 HU locule on CT & was a mixed signal intensity cystic mass without internal enhancement on MRI.

II. CT and pathologic correlation:

- CT and pathology were concordant for the presence or absence of peritoneal or nodal metastases except in cases denoted by ôr \*. Indicates cases where pathology was not available.
- \* Indicates cases where pathology showed metastatic disease. (A) in patient 9, 1 of 16 abdominal nodes resected had tumor. (B) In patient 3, 1 of 1 pelvic node resected had tumor.

III. *Abbreviations*: Pt: patient number; Diaph: anterior diaphragmatic nodes; Abd: abdominal nodes; Ing: inguinal nodes.

on CT will likely be challenging. Radiologic histologic correlation was not possible in this retrospective study. On MRI, SBT have a range of appearances which include unilocular or multilocular cysts with papillary projections, septated cystic lesions, or mixed solid cystic masses with enhancing soft tissue components [7–9]. High signal intensity is reported in the cyst fluid on T1 weighted images in some cases suggesting hemorrhage or proteinaceous material. This likely accounts for the cyst fluid

being higher than water density on CT in several cases in our study. The mixed solid cystic mass appearance of borderline tumors is similar to that of ovarian malignancy.

Psammoma bodies are calcified extracellular bodies that can occur in serous ovarian and peritoneal neoplasms as well as in thyroid masses [10]. They are common in LGSC. In a series of 53 patients, 29 (56%) patients had psammoma bodies at pathology without meeting the definition of psammomacarcinoma [2,11].

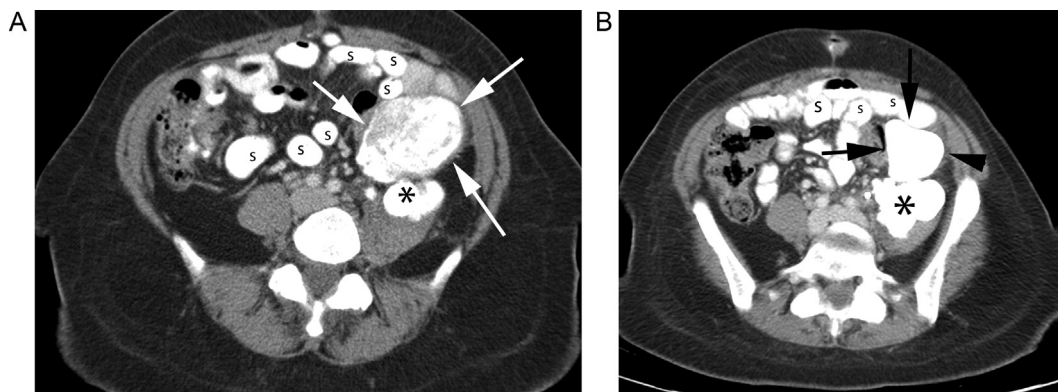


Fig. 4. Low grade serous carcinoma on serial CT. Patient 2 is a woman in her 60s. (a) Initial CT with oral and intravenous contrast shows a calcified solid mesenteric mass (arrows). Oral contrast is in small bowel loops (s). A calcified left psoas mass (\*) is partially imaged. (b) CT 4 months later shows increased calcification of the mesenteric mass (arrows). Oral contrast is in small bowel loops (s). The calcified left psoas mass (\*) is again imaged.



Table 2  
Low grade serous carcinoma with borderline tumor.

Pt	Adnexal mass CT finding/pathology		Peritoneal implants Calcification/mass size		Calcified nodes	Ascites		
	Right	Left	Pelvic	Abdominal				
4	Mass > 75% cystic 36 HU with nodular calcification Mass > 5 cm	LGSC&SBT	Mass > 75% cystic 32 HU with nodular calcification Mass > 5 cm	LGSC	Calcified 1–5 cm	Calcified > 5 cm	Abd < 1 cm <sup>^</sup>	None
5	Mass > 75% solid with calcification Mass > 5 cm	LGSC&SBT	Noncalcified ovary 1–5 cm	LGS*	None*	Noncalcified < 1 cm except for punctate calcification	Abd < 1 cm <sup>^</sup> Iliac 1–2 cm <sup>^</sup>	None
6	Remote oophorectomy	Benign	Mass > 75% cystic 33 HU with soft tissue nodularity & punctate calcification Mass > 5 cm	LGSC&SBT	Calcified < 1 cm	Calcified 1–5 cm	None	None
8	Mass > 75% cystic 38 HU with soft tissue nodularity & calcification Mass > 5 cm	LGSC&SBT	Mass > 75% cystic 23 HU with soft tissue nodularity & calcification Mass > 5 cm	LGSC&SBT	Calcified 1–5 cm	None*	None	None
11	Mass > 75% cystic 0 HU with septations & calcification Mass 1–5 cm	LGSC&SBT	Mass > 75% cystic 24 HU with septations & calcification Mass > 5 cm	LGSC	Calcified 1–5 cm	Calcified < 1 cm	None	Small
12	Mass > 75% cystic 34 HU with soft tissue nodularity & without calcification Mass > 5 cm	LGSC&SBT	Mixed solid cystic (30 HU) mass without calcification Mass 1–5 cm	LGSC&SBT	None	None	None	None
13	Mass > 75% cystic 48 HU with septations without calcification Mass > 5 cm	LGSC&SBT	Mass > 75% cystic 44 HU with septations without calcification Mass > 5 cm	SBT	None	None	None*	Minimal
14	Mass > 75% cystic 47 HU with septations without enhancement without calcification Mass > 5 cm	LGSC&SBT	Mass > 75% cystic 49 HU with septations without enhancement without calcification Mass > 5 cm	LGSC&SBT	Calcified < 1 cm	None*	None*	Small

Patients had ovarian low grade serous carcinoma (LGSC), serous borderline tumor (SBT), or both.

I. Additional imaging findings:

- a. In patient 14 – attenuation on renal corticomedullary phase/early excretory phase/more delayed excretory phase images – right ovary 37 HU/47 HU/49 HU, left ovary 43 HU/49 HU/48 HU.

II. CT and pathologic correlation:

- a. CT and pathology were concordant for the presence or absence of peritoneal or nodal metastases except in cases noted by  $\delta$  r \*.  $\hat{I}$ ndicates cases where pathology was not available.  
b. \* Indicates cases where pathology showed metastatic disease. (A) In patient 5, there were tumor emboli in the hilar vessels of the left ovary, the ovary was otherwise unremarkable at pathology. Tumor implants were also noted on the uterus. (B) In patient 8, an omental fragment had microscopic tumor without grossly visible mass. (C) In patient 13, 1 out of 2 abdominal nodes resected had tumor while the pelvic nodes were benign. (D) In patient 14, the omentum had tumor, 1 out of 3 right iliac nodes had tumor, and the remaining pelvic nodal stations were benign.

III. *Abbreviations*: Pt: patient number; Diaph: anterior diaphragmatic nodes; Abd: abdominal nodes; Ing: inguinal nodes.

In order for a serous neoplasm to be considered a psammomacarcinoma, at least 75% of the papillae have to contain psammoma bodies in addition to other pathologic criteria [11,12]. There are a few clinical case reports of psammomacarcinomas and calcification in serous neoplasms has also been reported on CT [10,13–15].

This appearance of a calcified solid or complex cystic mass places LGSC in the differential for adnexal masses that can calcify. These include exophytic uterine or broad ligament

fibroids and ovarian lesions such as Brenner tumors, fibromas and dermoids. Fibroids can be variably calcified with popcorn, peripheral or dense calcification. Feeding vessels from the uterus can help show the uterine origin of exophytic fibroids. Brenner tumors can be complex cystic or solid masses and have extensive calcifications similar to the LGSC tumors in our study [16]. However, Brenner tumors are usually benign lacking distant metastases [8,16]. Fibromas have focal or diffuse dense calcification in a minority of cases (<10%) and calcification is rare

Table 3  
Low grade serous carcinoma on serial CT.

Pt	days	Adnexal mass		Peritoneal implants Calcification/mass size		Calcified nodes	Ascites
		Right	Left	Pelvic	Abdominal		
1	t-165	Calcified 1–5 cm solid mass	Calcified 1–5 cm solid mass	Calcified > 5 cm	Calcified > 5 cm	Diaph 1 cm Abd 1–2 cm Ing > 2 cm	Minimal
	t-32	Increased calcification 1–5 cm mass	Increased calcification 1–5 cm mass	Increased calcification > 5 cm	Increased calcification > 5 cm	Increased calcification	Minimal
2	t-183	Noncalcified 1–5 cm solid mass	Calcified > 5 cm primarily solid mass	Calcified 1–5 cm	Calcified > 5 cm	Diaph < 1 cm Iliac > 2 cm Ing < 1 cm	Small
	t-28	Surface calcification 1–5 cm mass	Increased calcification > 5 cm mass	Increased calcification > 5 cm	Increased calcification > 5 cm	Increased calcification + new Abd 1–2 cm	Minimal
3	t-89	Noncalcified 5.2 cm cystic mass	Noncalcified 3.9 cm cystic mass	Noncalcified < 1 cm	Noncalcified 1–5 cm	None	Minimal
	t-9	Minimal calcification 4.3 cm cystic mass	Minimal calcification 2 cm cystic mass	Calcified < 1 cm	Noncalcified 1–5 cm	None	None
4	t-295	Calcified 8.8 cm cystic mass	Calcified 7.0 cm cystic mass	Calcified 1–5 cm	Calcified > 5 cm	Abd < 1 cm	None
	t-49	Increased calcification 9.1 cm cystic mass	Increased calcification 7.7 cm cystic mass	Increased calcification 1–5 cm	Increased calcification > 5 cm	Increased calcification	None

Findings in patients with serial CT scans prior to oophorectomy. All patients received neoadjuvant chemotherapy. Change noted on subsequent scan. T-# = number of days CT done prior to oophorectomy.

Abbreviations: Pt: patient number; Diaph: anterior diaphragmatic nodes; Abd: abdominal nodes; Ing: inguinal nodes.

in thecomas [8,17–19]. The presence of fat readily categorizes a calcified adnexal mass as a dermoid.

Features that can distinguish LGSC from benign entities include the presence of nodal calcification or peritoneal masses. Nodal calcification was seen in 4 of the 14 patients with LGSC in our study. In the absence of an infectious or inflammatory etiology, the presence of nodal calcification in a patient with a calcified adnexal mass raises the concern for a serous neoplasm [15]. Peritoneal implants are also seen in LGSC but not in patients with benign adnexal masses. However, ascites does not appear to be a helpful distinguishing feature. Ascites was not a prominent finding in the patients with LGSC in our study, even in those with peritoneal masses and serial CT scans. Ascites is also uncommon in fibromas, with Meigs syndrome occurring in 1% of cases [18].

In the few patients with multiple CT scans, the adnexal and peritoneal masses showed increased calcification over time possibly due to the natural course of the disease and/or secondary to chemotherapy effect. LGSC are considered to be fairly chemoresistant [1,20].

Although the number of patients in this study is small, the CT findings of this uncommon tumor were evaluated in patients in whom the diagnosis of LGSC had been made by specialty gynecologic pathologists from a single institution.

## 5. Conclusion

Low grade serous carcinoma of the ovary can appear as a solid, mixed solid cystic, or complex primarily cystic adnexal mass, and the appearance may be due to a co-existing serous

borderline tumor. Calcification of the adnexal mass and peritoneal metastases appears to be common. LGSC is a diagnostic consideration in patients with a calcified adnexal mass and concurrent peritoneal masses or calcified nodes on CT.

## Conflict of interest

The author declare that no conflict of interest.

## References

- [1] Romero I, Sun CC, Wong KK, Bast Jr RC, Gershenson DM. Low-grade serous carcinoma: new concepts and emerging therapies. *Gynecol Oncol* 2013;130(September (3)):660–6.
- [2] Diaz-Padilla I, Malpica AL, Minig L, Chiva LM, Gershenson DM, Gonzalez-Martin A. Ovarian low-grade serous carcinoma: a comprehensive update. *Gynecol Oncol* 2012;126(August (2)):279–85.
- [3] Malpica A, Deavers MT, Lu K, Bodurka DC, Atkinson EN, Gershenson DM, et al. Grading ovarian serous carcinoma using a two-tier system. *Am J Surg Pathol* 2004;28(April (4)):496–504.
- [4] Malpica A. Grading of ovarian cancer: a histotype-specific approach. *Int J Gynecol Pathol* 2008;27(April (2)):175–81.
- [5] Plaxe SC. Epidemiology of low-grade serous ovarian cancer. *Am J Obstet Gynecol* 2008;198(April (4)), 459.e1-8; discussion 459.e8-9.
- [6] Vang R, Shih IeM, Kurman RJ. Ovarian low-grade and high-grade serous carcinoma: pathogenesis, clinicopathologic and molecular biologic features, and diagnostic problems. *Adv Anat Pathol* 2009;16(September (5)):267–82.
- [7] Bent CL, Sahdev A, Rockall AG, Singh N, Sohaib SA, Reznick RH. MRI appearances of borderline ovarian tumours. *Clin Radiol* 2009;64(April (4)):430–8.
- [8] Jung SE, Lee JM, Rha SE, Byun JY, Jung JI, Hahn ST. CT and MR imaging of ovarian tumors with emphasis on differential diagnosis. *Radiographics* 2002;22(November–December (6)):1305–25.

- [9] Van Vierzen PB, Massuger LF, Ruys SH, Barentsz JO. Borderline ovarian malignancy: ultrasound and fast dynamic MR findings. *Eur J Radiol* 1998;28(September (2)):136–42.
- [10] Giordano G, Gnetti L, Milione M, Piccolo D, Soliani P. Serous psammocarcinoma of the ovary: a case report and review of literature. *Gynecol Oncol* 2005;96(January (1)):259–62.
- [11] Schmeler KM, Sun CC, Malpica A, Deavers MT, Bodurka DC, Gershenson DM. Low-grade serous primary peritoneal carcinoma. *Gynecol Oncol* 2011;121(June (3)):482–6.
- [12] Gilks CB, Bell DA, Scully RE. Serous psammocarcinoma of the ovary and peritoneum. *Int J Gynecol Pathol* 1990;9(2):110–21.
- [13] Akbulut M, Kelten C, Bir F, Soysal ME, Duzcan SE. Primary peritoneal serous psammocarcinoma with recurrent disease and metastasis: a case report and review of the literature. *Gynecol Oncol* 2007;105(April (1)):248–51.
- [14] Hiromura T, Tanaka YO, Nishioka T, Tomita K. Serous psammocarcinoma of the ovary: CT and MR findings. *J Comput Assist Tomogr* 2007;31(May–June 3):490–2.
- [15] Agarwal A, Yeh BM, Breiman RS, Qayyum A, Coakley FV. Peritoneal calcification: causes and distinguishing features on CT. *AJR Am J Roentgenol* 2004;182(February (2)):441–5.
- [16] Moon WJ, Koh BH, Kim SK, Kim YS, Rhim HC, Cho OK, et al. Brenner tumor of the ovary: CT and MR findings. *J Comput Assist Tomogr* 2000;24(January–February (1)):72–6.
- [17] Shambhogue AKP, Shambhogue DKP, Prasad SK, Surabhi VR, Fasih N, Menias CO. Clinical syndromes associated with ovarian neoplasms: a comprehensive review. *Radiographics* 2010;30:903–19.
- [18] Sex cord-stromal and steroid cell tumors. Clement PB, Young RH, editors. *Atlas of gynecologic surgical pathology*. Philadelphia, PA: Elsevier Inc.; 2008. p. 386–414 [Chapter 16].
- [19] Outwater EK, Wagner BJ, Mannion C, McLarney JK, Kim B. Sex cord-stromal and steroid cell tumors of the ovary. *Radiographics* 1998;18:1523–46.
- [20] Gershenson DM, Sun CC, Lu KH, Coleman RL, Sood AK, Malpica A, et al. Clinical behavior of stage II–IV low-grade serous carcinoma of the ovary. *Obstet Gynecol* 2006 Aug;108(2):361–8.