

A novel endobronchial approach to massive hemoptysis complicating silicone Y-stent placement for tracheobronchomalacia

A case report

Changwan Ryu, MD, MPH^{a,*}, Daniel Boffa, MD^b, Kyle Bramley, MD^a, Margaret Pisani, MD, MPH^a, Jonathan Puchalski, MD, MEd^a

Abstract

Rationale: Airway stabilization for severe, symptomatic tracheobronchomalacia (TBM) may be accomplished by silicone Y-stent placement. Common complications of the Y-stent include mucus plugging and granulation tissue formation.

Patient concerns: We describe a rare case of massive hemoptysis originating from a silicone Y-stent placed for TBM.

Diagnoses: An emergent bronchoscopy showed an actively bleeding, pulsatile vessel at the distal end of the left bronchial limb of the Y-stent. It was felt that the bleeding was caused by, or at least impacted by, the distal left bronchial limb of the Y-stent eroding into the airway wall.

Interventions: We hypothesized that placement of oxidized regenerated cellulose (ORC) would provide initial hemostasis, and the subsequent placement of a biocompatible surgical sealant would lead to definitive resolution.

Outcomes: ORC provided sufficient hemostasis and the subsequent synthetic polymer reinforced the tissue for complete cessation of the bleed.

Lessons: The combined use of ORC and a biocompatible surgical sealant provided long-term management for life-threatening hemoptysis, and potentially morbid procedures such as embolization or surgery were avoided by advanced endobronchial therapy.

Abbreviations: COPD = chronic obstructive pulmonary disease, CPAP = continuous positive airway pressure, Fr = French size, OR = operating room, ORC = oxidized regenerated cellulose, PEG = polyethylene glycol, TBM = tracheobronchomalacia.

Keywords: biocompatible surgical sealant, oxidized regenerated cellulose, silicone Y-stent, tracheobronchomalacia

1. Introduction

Tracheobronchomalacia (TBM) is an anomaly of the central airways characterized by the excessive expiratory collapsibility of the tracheal and bronchial walls.^[1,2] Congenital causes include prematurity and cartilage abnormalities, while acquired causes stem from prolonged intubation, severe obstructive lung disease, and recurrent tracheobronchitis.^[1,2] As a result of either etiology, there is atrophy of the longitudinal elastic fibers of the pars

membranacea, an increase in membranous tracheal diameter, and fragmentation of cartilaginous rings, leading to weakness of the tracheobronchial wall and supporting cartilage.^[1] The most common symptoms include cough, dyspnea, and recurrent infection.^[1,3]

Airway stabilization for severe, symptomatic TBM has been accomplished by silicone Y-stent placement^[3–5] with subsequent improvement in dyspnea, quality of life, and functional status.^[3] Not uncommonly, the Y-stent has led to the development of mucus plugging, biofilm formation, and granulation tissue development (Fig. 1A and B).^[3] We describe a rare, life-threatening case of massive hemoptysis complicating Y-stent placement and a novel therapeutic approach via the endobronchial application of oxidized regenerated cellulose (ORC) and a biocompatible surgical sealant.

2. Case presentation

A 65-year-old Caucasian woman with a past medical history significant for coronary artery disease requiring recent stenting, allergic asthma, chronic obstructive pulmonary disease (COPD), and severe TBM secondary to her obstructive lung diseases presented to our institution with massive hemoptysis. Three months prior to presentation she underwent placement of a silicone Y-stent as destination therapy for symptomatic TBM. At this point, she experienced recurrent hospitalizations for respiratory failure and refractory dyspnea despite maximization of other medical therapies, including airway clearance techniques, bronchodilators, physical therapy, and continuous positive

Editor: Levent Dalar.

Funding: CR is currently supported by a T32HL007778-21 grant.

Ethics Committee: Approved by the Yale New Haven Hospital Ethics Committee.

The authors have no conflicts of interest to disclose.

^aYale School of Medicine, Department of Internal Medicine, Section of Pulmonary, Critical Care, and Sleep Medicine, ^bYale School of Medicine, Department of Thoracic Surgery, New Haven, CT, USA.

* Correspondence: Changwan Ryu, Yale University School of Medicine, Department of Internal Medicine, Section of Pulmonary, Critical Care, and Sleep Medicine, 300 Cedar Street, TAC 441 South, New Haven, CT 06520 (e-mail: changwan.ryu@yale.edu).

Copyright © 2018 the Author(s). Published by Wolters Kluwer Health, Inc. This is an open access article distributed under the Creative Commons Attribution-ShareAlike License 4.0, which allows others to remix, tweak, and build upon the work, even for commercial purposes, as long as the author is credited and the new creations are licensed under the identical terms.

Medicine (2018) 97:8(e9980)

Received: 22 August 2017 / Received in final form: 19 January 2018 / Accepted: 31 January 2018

<http://dx.doi.org/10.1097/MD.0000000000009980>

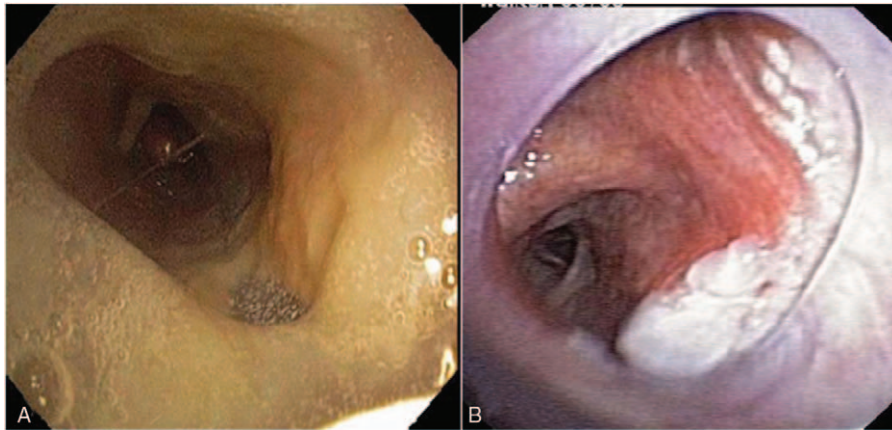


Figure 1. Complications of silicone Y-stent placement. Complications of silicone Y-stents typically occur within the first 3 months of placement, and the most common include (A) infectious biofilm formation and (B) granulation tissue formation, which may be significant.

airway pressure (CPAP). Tracheobronchoplasty was initially considered after Y-stent placement but was not viable because, in addition to declining surgical approaches to management, her multiple co-morbidities and recurrent hospitalizations severely limited her functional status. One month prior to presentation she underwent uneventful argon plasma coagulation to ablate granulation tissue. Upon arrival to our emergency department, she complained of progressive hemoptysis and worsening dyspnea for 2 hours. Physical examination revealed hypoxemic respiratory failure with hemoptysis of 250 ml of frank blood within an hour of presentation and diminished breath sounds in the left lung. She required intubation and bronchoscopy showed an actively bleeding, pulsatile vessel at the distal end of the left bronchial limb of the Y-stent. It was felt that the bleeding was caused by, or at least impacted by, the distal left bronchial limb of the Y-stent eroding into the airway wall. Given her critical condition, she was taken emergently to the operating room (OR) for removal of her stent. Interventional radiology was briefly

considered, but given our impression that the stent needed to be removed and bronchoscopy was required, plus our ability to topically treat the area, embolization was reserved for bronchoscopic failure.

3. Airway management

Following her initial bronchoscopy, hemostasis was achieved via placement of an Arndt endobronchial blocker (Cook Critical Care, Bloomington, IN). In the time it took to bring her emergently to the OR, repeat bronchoscopy demonstrated bleeding cessation. The endobronchial blocker and Y-stent were then removed to allow definitive management in this “window of opportunity.” With this, however, bleeding was again evident and ORC (Surgicel, Ethicon, Somerville, NJ) was immediately placed at the bleeding site through the rigid bronchoscope, again leading to bleeding cessation. We felt a more definitive approach would be required given the ongoing bleeding at a localized source.

To this end, in collaboration with thoracic surgery, 2 ureteral catheters were tied in tandem using stitches to ensure they terminated equidistant in the airways. The 6 French size (Fr) polyurethane catheters (Bard, Covington, GA) were chosen for their length (70 cm), combined size (effectively 12 Fr), and conceptually that each of the 2 sealant components could be mixed together at the distant site of bleeding, thus preventing sealing of the delivery system during actual administration. The tied catheters were advanced through the rigid bronchoscope using direct visualization. Thereafter, the biocompatible surgical sealant (CoSeal, Baxter, Deerfield, IL) was administered endobronchially at the precise bleeding site using the two-syringe system attached to the catheters. Placement of these catheters distally in the left mainstem (Fig. 2) enabled endobronchial mixing of the sealant directly at the bleeding source. She was extubated within 24 hours and was successfully discharged home. A complete schematic of her airway management is shown in Figure 3.

A follow-up bronchoscopy 1 month later demonstrated mucosal healing (Fig. 4), and she reported no additional episodes of hemoptysis. In the 2 years following removal of her stent, there have been no new complications to report and her respiratory status has remained satisfactory despite removal of the stent.

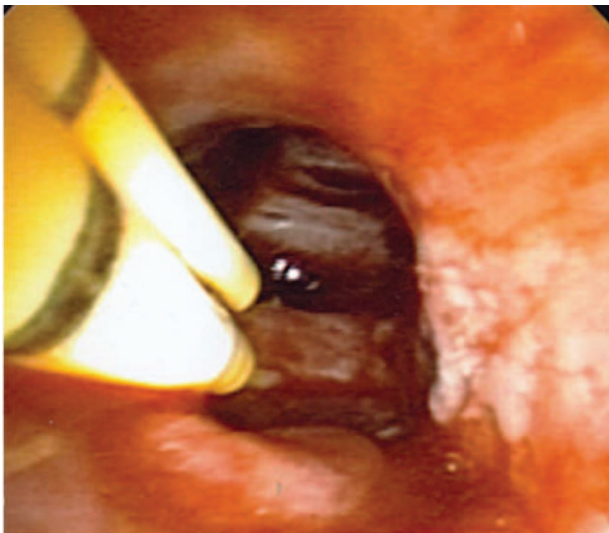


Figure 2. Application of the surgical sealant. Dual ureteral catheters were placed in distal left mainstem bronchus and used to administer each component of the sealant, enabling endobronchial mixing and permanent bleeding control.

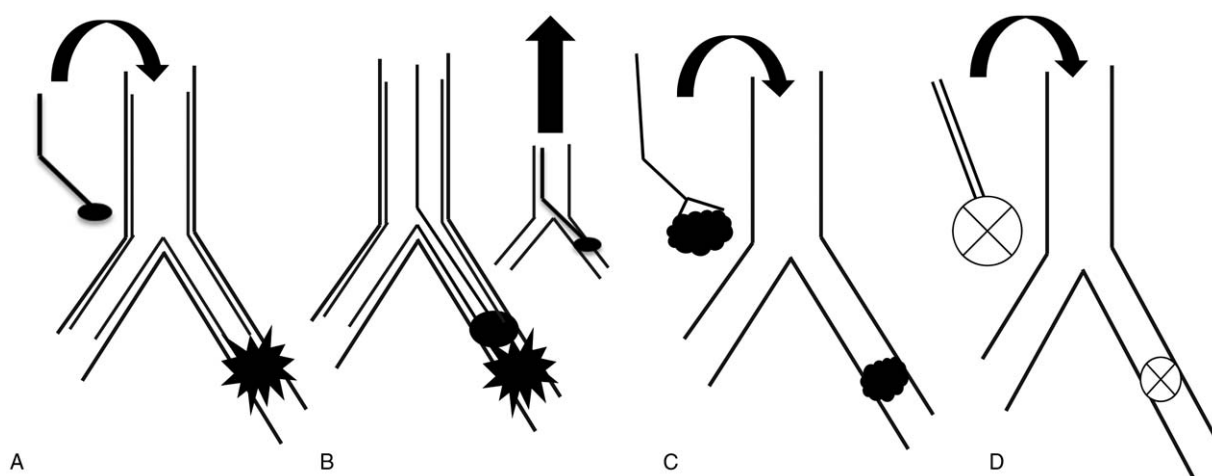


Figure 3. Schematic of airway management. (A) After visualization of pulsatile blood flow in distal left mainstem bronchus (starburst) at the termination of the Y-stent bronchial limb, an endobronchial blocker (oval) was placed for temporary cessation of hemoptysis and to facilitate transfer to the operating room (OR). (B) In the OR, the endobronchial blocker and Y-stent were removed and initial hemostasis was achieved using (C) surgical (cloud), placed endoscopically with forceps. Bleeding stopped and subsequently (D) dual ureteral catheters were used to administer each component of the sealant, enabling endobronchial mixing and permanent bleeding control. OR=operating room.

4. Discussion

The use of silicone Y-stents for airway stabilization in severe TBM has demonstrated improvement in dyspnea, quality of life, and functional status.^[3] Complications typical occur within the first 3 months of stent placement and include obstruction from mucus plugging, stent migration, infection, and granulation tissue formation.^[3] These complications are typically treated with mucolytics, cough suppressants, suctioning, and antibiotics, only rarely necessitating stent removal.^[3,4] In the few reported cases of hemoptysis following silicone Y-stent placement, the proposed etiologies include local erosion from stent apposition, granulation tissue formation resulting in irritation, and fistula formation

with adjacent blood vessels.^[6] In our case, given that the patient previously had granulation tissue that required ablation, we suspect she had ongoing irritation from the stent creating local erosion and prompting pulsatile bleeding from a bronchial artery.

The use of bronchoscopy to control massive hemoptysis commonly involves endobronchial instillation of iced saline^[7] or vasoconstrictive agents such as epinephrine,^[8] tranexamic acid,^[9] or fibrinogen–thrombin combinations,^[10] at the bleeding site. Advanced bronchoscopic procedures include argon plasma coagulation, electrocautery, and laser photocoagulation when a bleeding lesion can be identified.^[8] Bronchial artery embolization and surgery are reserved in cases where hemoptysis cannot be managed bronchoscopically.^[8]

The individual use of ORC^[6] and biocompatible surgical sealants^[11] to achieve hemostasis in hemoptysis has been described, although this combination has not been previously reported. We hypothesized that ORC provided sufficient hemostasis, and the subsequent synthetic polymer reinforced the tissue for complete cessation of the bleed.

ORC contains caustic properties that react with blood to form an artificial coagulum that provides the substrate for further clotting.^[12] Its availability in multiple forms, such as an absorbable mesh, has led to its wide application to control bleeding in highly vascular sites.^[6,12] Its role in the management of hemoptysis via endobronchial application has been described,^[6] and its use in the treatment of hemoptysis remains an off-label indication.

Biocompatible surgical sealants achieve hemostasis by promoting coagulation and providing a mechanical barrier at the site of bleeding.^[13] They are frequently utilized during vascular surgery to control bleeding at anastomotic sites.^[13,14] While various sealants are available,^[13] we employed polyethylene glycol (PEG) polymers that form a highly adhesive hydrogel when mixed together.^[15] The hydrogel then binds to tissue surface proteins to achieve hemostasis with a rapid onset of action.^[15] In our case, we employed urethral catheters as a conduit to deliver each of the polymers because the normal admixing device is not plausible for airways. Although the use of PEG polymers to treat hemoptysis has yet to be described and is presently an off-labeled

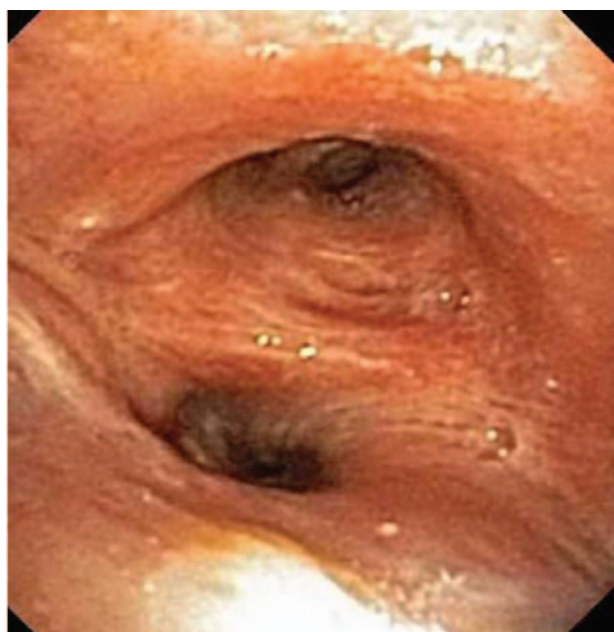

Figure 4. Follow-up bronchoscopy. Bronchoscopy 1 month later demonstrated no active bleeding and improvement of the granulation tissue.

indication for its treatment, we believed PEG polymers to be appropriate for its application in the airways because it is more compliant than other available sealants.^[13,14] Given that the volume of application may increase following admixture, we were prepared to bronchoscopically remove any plug or airway occlusion. In this regard, the rigid bronchoscope was in place and additional balloons, forceps, and recovery and ablativ tools were immediately available if required. We also employed the assistance of a thoracic surgeon (DB), who has had extensive experience with CoSeal and is thoroughly familiar with its properties, to help navigate any potential pitfalls in the novel application of this sealant. We advocate a similar approach for future cases.

5. Conclusion

Massive hemoptysis is a rare complication of silicone Y-stent placement. We present a novel method of managing this life-threatening complication with advanced endobronchial therapy that combined the placement of oxidized regenerated cellulose with a biocompatible surgical sealant. In addition to minimizing ongoing injury, we were able to provide a long-term treatment strategy that avoided potentially morbid procedures, such as embolization or surgery.

References

- [1] Carden KA, Boiselle PM, Waltz DA, et al. Tracheomalacia and tracheobronchomalacia in children and adults: an in-depth review. *Chest* 2005;127:984–1005.
- [2] Septimiu D, Murgu HGC. Tracheobronchomalacia and excessive dynamic airway collapse. *Respirology* 2006;11:388–406.
- [3] Ernst A, Majid A, Feller-Kopman D, et al. Airway stabilization with silicone stents for treating adult tracheobronchomalacia: a prospective observational study. *Chest* 2007;132:609–16.
- [4] Oki M, Saka H. New dedicated bifurcated silicone stent placement for stenosis around the primary right carina. *Chest* 2013;144:450–5.
- [5] Makris D, Marquette CH. Tracheobronchial stenting and central airway replacement. *Curr Opin Pulm Med* 2007;13:278–83.
- [6] Valipour A, Kreuzer A, Koller H, et al. Bronchoscopy-guided topical hemostatic tamponade therapy for the management of life-threatening hemoptysis. *Chest* 2005;127:2113–8.
- [7] Cahill BC, Ingbar DH. Massive hemoptysis. Assessment and management. *Clin Chest Med* 1994;15:147–67.
- [8] Sakr L, Dutau H. Massive hemoptysis: an update on the role of bronchoscopy in diagnosis and management. *Respiration* 2010;80:38–58.
- [9] De Boer WA, Koolen MG, Roos CM, et al. Tranexamic acid treatment of hemothorax in two patients with malignant mesothelioma. *Chest* 1991;100:847–8.
- [10] Tsukamoto T, H Sasaki Fau-Nakamura, Nakamura H. Treatment of hemoptysis patients by thrombin and fibrinogen-thrombin infusion therapy using a fiberoptic bronchoscope. *Chest* 1989;96:473–6.
- [11] Bhattacharyya P, Dutta A, Samanta AN, et al. New procedure: bronchoscopic endobronchial sealing; a new mode of managing hemoptysis. *Chest* 2002;121:2066–9.
- [12] Lewis KM, Spazierer D, Urban MD, et al. Comparison of regenerated and non-regenerated oxidized cellulose hemostatic agents. *Eur Surg* 2013;45:213–20.
- [13] Gabay M, Boucher BA. An essential primer for understanding the role of topical hemostats, surgical sealants, and adhesives for maintaining hemostasis. *Pharmacotherapy* 2013;33:935–55.
- [14] Azadani AN, Mathews PB, Ge L, et al. Mechanical properties of surgical glues used in aortic root replacement. *Ann Thorac Surg* 2009;87:1154–60.
- [15] Wallace DG, Cruise GM, Rhee WM, et al. A tissue sealant based on reactive multifunctional polyethylene glycol. *J Biomed Mater Res* 2001;58:545–55.