

A cryptic message in the brain

Dear Sir,

The science of medicine has developed by leaps and bounds over the years. However, the best intentions of physicians and the most well planned decisions may not do justice to the patients. We present a case where an atypical presentation and a resource limited investigation produced a misdiagnosis, an unnecessary intrusion into the brain and misery for all concerned. It was diagnosed as hemorrhage, post-operative biopsy reported nothing and only reassessment pointed toward the direction of diagnosis.

A 45-year-old diabetic woman came with left sided headache for 5 years which was severe in the early morning and was associated with projectile vomiting and photophobia. She observed progressive, painless loss of vision initially in her left eye and then the right eye. She was not even able to discriminate between colors. She had also developed double vision, which pronounced on looking towards the left side. To add to her troubles there was a progressive hearing loss of the left ear for the past 1 year.

Examination showed: Loss of abduction of the left eye, sensorineural deafness in the left ear and bilateral papilledema. Neck rigidity and Kerning's sign were present.

Investigations revealed: Normal blood work, hepatic and renal function tests. Chest X-ray and echocardiography were also unremarkable.

Computed tomography (CT) brain disclosed: A hypo density on the left cerebral convexity [Figure 1], with peripheral enhancement and a hyper density along the left tentorial leaf [Figure 2].

Patient was diagnosed as subdural hematoma and was subjected to surgery.

However, biopsy report was: Dense fibro collagenous tissue.

No specific infective or neoplastic pathology.

In spite of surgery her symptoms did not subside and she came back 10 days later.

CT brain [Figure 3] after the surgery was: Suggestive of pachymeningitis.

Cerebrospinal fluid (CSF) analysis revealed elevated protein levels and *Cryptococcal* antigen positive.

Patient was treated with amphotericin B 1 mg/kg/day (intravenously) plus flucytosine 100 mg/kg/day for 2 weeks, followed by fluconazole 6 mg/kg/day orally for 8 weeks.

She recovered fully and has no complaints since then.

Patient in question had presented with a clear cut history suggestive of a mass lesion compressing the brain from the left. The surgeon operated on her with the report from the CT scan as the condition was progressing and she needed immediate

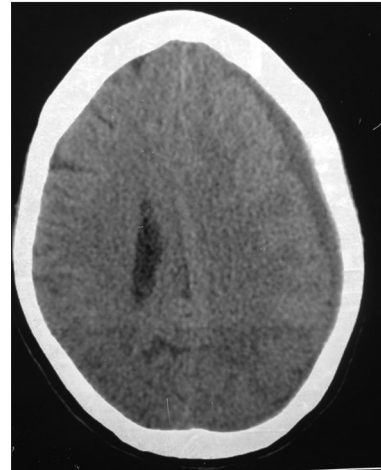


Figure 1: Hypo density on the left cerebral convexity

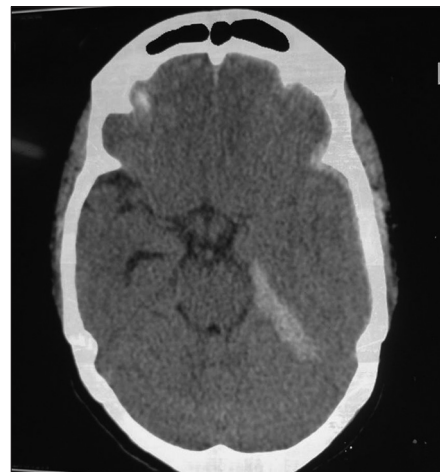


Figure 2: Hyper density along the left tentorial leaf

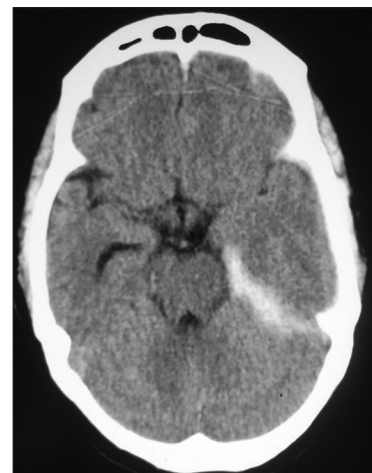

Figure 3: Computed tomography brain after the surgery suggestive of pachymeningitis

intervention. When the biopsy report came in, it was clear that something had gone wrong. And when her symptoms recurred, it was obvious that the diagnosis was off the mark. The second brain imaging suggested a clue to the diagnosis.

CSF analysis was the answer. With a mass lesion and papilledema there was a risk of death with the procedure. However, the progressive nature of the disease demanded a calculated risk. A guarded lumbar puncture was performed and the procedure was uneventful. In view of the patient's diabetic^[1] status, in addition to routine CSF analysis, a *Cryptococcal* antigen test was also ordered. This clinched the diagnosis and saved the patient.

There have been several cases reported with *Cryptococcal*^[2] and pneumococcal^[3] meningitis masquerading as hemorrhage. The presenting features may be identical. Diabetes mellitus is a risk factor for both meningeal infections and cerebrovascular events. The one may be differentiated from the other by a guarded lumbar puncture for CSF analysis.^[4]

The case is quite instructive and humbling at the same time. It highlights the need for careful pre-operative assessment and the importance of differential diagnosis in apparently straight forward presentations. It stresses the need for re-evaluation and logical investigation even in post-operative patients.

Acknowledgments

The authors would like to thank the Department of Radiology, Guntur Medical College.

N. V. Sundarachary, A. Sridhar¹

Departments of Neurology and ¹General Medicine, Guntur Medical College, Guntur, Andhra Pradesh, India

For correspondence:

Dr. A. Sridhar, PG Hostel, Government General Hospital, Guntur, Andhra Pradesh, India.
E-mail: iamimenotu@gmail.com

References

1. Kushawaha A, Mobarakai N, Parikh N, Beylison A. *Cryptococcus neoformans* meningitis in a diabetic patient – The perils of an overzealous immune response: A case report. *Cases J* 2009;2:209.
2. Hoque R, Gonzalez-Toledo E, Jaffe SL. *Cryptococcal* meningitis presenting as pseudosubarachnoid hemorrhage. *South Med J* 2008;101:1255-7.
3. Morgan LK. Pneumococcal meningitis masquerading as subarachnoid haemorrhage. *Med J Aust* 2003;179:559-60;560.
4. Given CA 2nd, Burdette JH, Elster AD, Williams DW 3rd. Pseudo-subarachnoid hemorrhage: A potential imaging pitfall associated with diffuse cerebral edema. *AJNR Am J Neuroradiol* 2003;24:254-6.

Access this article online

Quick Response Code:



Website:

www.annalsofian.org

DOI:

10.4103/0972-2327.120444