

BRIEF COMMUNICATION OPEN



# Corneal graft rejection following COVID-19 vaccine

Konstantinos I. Rallis<sup>1,4</sup>, Darren S. J. Ting<sup>1,2,4</sup>, Dalia G. Said<sup>1,2,3</sup> and Harminder S. Dua<sup>1,2</sup>✉

© The Author(s) 2021

Eye (2022) 36:1319–1320; <https://doi.org/10.1038/s41433-021-01671-2>

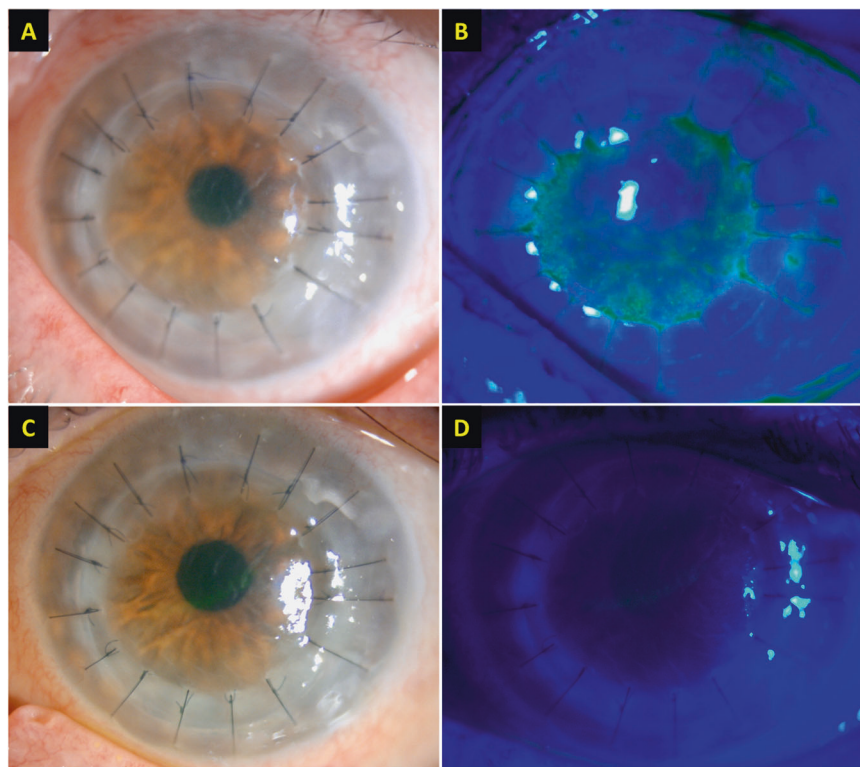
## INTRODUCTION

COVID-19 has affected >100 million with >2 million deaths worldwide. A number of effective mRNA-based [1] and viral vector-based vaccines [2] have been developed and deployed. However, as COVID-19 vaccines have been shown to induce strong immune responses [3], there remains a hypothetical concern whether the vaccine could increase the risk of transplant rejection in non-immunosuppressed patients. In this report, we

highlight a case of acute corneal allograft rejection shortly after the administration of COVID-19 vaccine.

## CASE DESCRIPTION

In February 2021, a 68-year-old woman attended the eye casualty with a 1-day history of left painful red eye and rapid deterioration of vision. Four days earlier, she received her first dose of mRNA-



**Fig. 1** A case of acute corneal endothelial graft rejection after COVID-19 vaccine. **A, B** Slit-lamp photography demonstrating conjunctival hyperaemia, corneal graft haze, diffuse corneal epithelial, and stromal oedema (within the graft), Descemet's folds, scattered keratic precipitates (KPs), and 1+ cells in anterior chamber. An unusual distribution of fluorescein staining with coarse punctate epitheliopathy over the corneal graft was observed. The central corneal thickness (CCT) was 730  $\mu\text{m}$ . **C, D** At 3-week post treatment, the corneal graft rejection was successfully treated with considerable improvement in the graft transparency, reduction in epithelial and stromal oedema, and resolution of epitheliopathy and anterior chamber inflammation. The best-corrected visual acuity improved to 6/12, with a CCT of 609  $\mu\text{m}$ .

<sup>1</sup>Department of Ophthalmology, Queen's Medical Centre, Nottingham, UK. <sup>2</sup>Academic Ophthalmology, Division of Clinical Neuroscience, School of Medicine, University of Nottingham, Nottingham, UK. <sup>3</sup>Research Institute of Ophthalmology, Cairo, Egypt. <sup>4</sup>These authors contributed equally: Konstantinos I. Rallis, Darren S. J. Ting. ✉email: [harminder.dua@nottingham.ac.uk](mailto:harminder.dua@nottingham.ac.uk)

Received: 19 June 2021 Revised: 22 June 2021 Accepted: 23 June 2021  
Published online: 23 August 2021

based BNT162b2 COVID-19 vaccine (Pfizer-BioNtech). On the next day, she developed moderate systemic reactions, including chills, myalgia, and tiredness, followed by unexpected ocular symptoms on the third day.

Her past ocular history included a bilateral lamellar Descemet Stripping Automated Endothelial Keratoplasty (DSAEK) for Fuchs' corneal endothelial dystrophy and a left re-do penetrating keratoplasty (PKP) for failed DSAEK in October 2020. There was no other relevant past ocular/medical history. At 2-month post-PKP, her left eye best-corrected visual acuity (BCVA) was 6/18 with a clear corneal graft. She was maintained on topical prednisolone 0.5% QID for the left eye and dexamethasone 0.1% OD for the right eye.

At presentation, her left BCVA was counting fingers. Slit-lamp examination confirmed the diagnosis of acute corneal endothelial graft rejection, evidenced by conjunctival hyperaemia, diffuse corneal punctate staining, corneal graft oedema, Descemet's folds, scattered keratic precipitates, and anterior chamber activity (Fig. 1). The right corneal graft remained healthy.

The patient was immediately treated with hourly topical dexamethasone 0.1% and a week of oral acyclovir 400 mg 5x/day (to cover for any possible underlying herpes simplex keratitis), with no treatment modification in the right eye. Significant improvement was noted by 3-week post-treatment with complete resolution of corneal graft rejection (Fig. 1C, D).

## DISCUSSION

Corneal graft rejection after vaccination is rare, with most evidence so far being linked to influenza vaccination. To our best knowledge, this is the second report of corneal allograft rejection following COVID-19 vaccine [4].

COVID-19 vaccines have been shown to induce SARS-CoV-2 neutralising antibodies and elicit strong Th1-biased CD4+ responses in human [3]. CD4+ Th1 cells have been shown to be the main mediators of corneal graft rejection [5], which could have contributed to the graft rejection. Intriguingly, corneal graft rejection only occurred in the left eye despite the presence of bilateral grafts. This may be attributed to the more recent history of left eye surgery and a repeat graft, which is known to have a higher risk of rejection. Although a direct cause-and-effect relationship remains to be established, it would be prudent to defer elective corneal transplant by 3–6 months after the second dose of COVID-19 vaccines and to consider institution of intensive topical steroids (6–8 times a day) in grafted eyes at the time of the first dose of vaccine until at least a month after the second dose, as the immune response peaks on 7–28 days post vaccine [3].

## REFERENCES

1. Polack FP, Thomas SJ, Kitchin N, Absalon J, Gurtman A, Lockhart S, et al. Safety and efficacy of the BNT162b2 mRNA Covid-19 vaccine. *N Engl J Med.* 2020;383:2603–15.

2. Voysey M, Costa Clemens SA, Madhi SA, Weckx LY, Folegatti PM, Aley PK, et al. Single-dose administration and the influence of the timing of the booster dose on immunogenicity and efficacy of ChAdOx1 nCoV-19 (AZD1222) vaccine: a pooled analysis of four randomised trials. *Lancet.* 2021;397:881–91.
3. Sahin U, Muik A, Vogler I, Derhovanessian E, Kranz LM, Vormehr M, et al. BNT162b2 induces SARS-CoV-2-neutralising antibodies and T cells in humans. *medRxiv.* 2020. <https://doi.org/10.1101/2020.12.09.20245175>.
4. Phylactou M, Li JO, Larkin DFP. Characteristics of endothelial corneal transplant rejection following immunisation with SARS-CoV-2 messenger RNA vaccine. *Br J Ophthalmol.* 2021;105:893–6.
5. Niederkorn JY. Corneal transplantation and immune privilege. *Int Rev Immunol.* 2013;32:57–67.

## AUTHOR CONTRIBUTIONS

Data collection: KIR and DSJT. Data interpretation: KIR, DSJT, DGS, and HSD. Manuscript drafting: KIR and DSJT. Critical revision of the manuscript: DGS and HSD. Final approval of the manuscript: all authors

## FUNDING

DSJT is supported by the Medical Research Council/Fight for Sight (FFS) Clinical Research Fellowship (MR/T001674/1) and the FFS/John Lee, Royal College of Ophthalmologists Primer Fellowship (24CO4).

## COMPETING INTERESTS

The authors declare no competing interests.

## ADDITIONAL INFORMATION

**Correspondence** and requests for materials should be addressed to H.S.D.

**Reprints and permission information** is available at <http://www.nature.com/reprints>

**Publisher's note** Springer Nature remains neutral with regard to jurisdictional claims in published maps and institutional affiliations.



**Open Access** This article is licensed under a Creative Commons Attribution 4.0 International License, which permits use, sharing, adaptation, distribution and reproduction in any medium or format, as long as you give appropriate credit to the original author(s) and the source, provide a link to the Creative Commons license, and indicate if changes were made. The images or other third party material in this article are included in the article's Creative Commons license, unless indicated otherwise in a credit line to the material. If material is not included in the article's Creative Commons license and your intended use is not permitted by statutory regulation or exceeds the permitted use, you will need to obtain permission directly from the copyright holder. To view a copy of this license, visit <http://creativecommons.org/licenses/by/4.0/>.

© The Author(s) 2021