

Refabrication of an implant-retained auricular prosthesis using clip attachment pickup technique

Sanketh Kethireddy, Keerthi Kethireddy

The Maxillofacial Rehabilitation Centre, Chennai, Tamil Nadu, India

Abstract Increased patient acceptance and widespread use have led to a greater demand for refabrication of existing maxillofacial prostheses exhibiting wear and tear. Refabricating an osseointegrated implant-retained silicone auricular prosthesis on the existing Hader bar is a challenging task if it is performed without removing it. Therefore, an attachment level impression method is utilized for the refabrication of a new prosthesis on an existing Hader bar framework without removing it from the patient's defect. This case report discusses a modification of the Mahidol University technique. This modification provides a simple, speedy, and convenient method through which the relation between the metal framework and attachments could be obtained precisely. This precision allowed for easy fabrication of the acrylic housing, which in turn results in better adaptation of the auricular prosthesis to the patient's face. Therefore, this technique offers advantages to both the prosthetist in fabrication and the patient in facilitating him continue to wear his existing implant-retained prosthesis during refabrication process.

Keywords: Attachment level impression, craniofacial implants, implant retention, indirect acrylic housing, silicone auricular prosthesis

Address for correspondence: Dr. Sanketh Kethireddy, 316, TTK Rd, Alwarpet, Chennai - 200 016, Tamil Nadu, India.

E-mail: drsankethreddy@hotmail.com

Received: 30th June, 2016, **Accepted:** 02nd May, 2017

INTRODUCTION

Defects of the auricle, whether acquired or congenital,^[1] can be of significant disability to patients, from psychological to social, and functional perspective.^[2] Rehabilitation of such defects with an implant-retained auricular prosthesis has been widely practiced for more than three decades since P. I. Branemark advocated the use of craniofacial osseointegrated implants.^[3] Multiple designs have been suggested for various attachments used for both ease of prosthesis placement as well as assured retention

and stability of the prosthesis.^[4,5] Conventionally, an implant level impression technique is employed for either fabrication or refabrication with the use of same Hader bar framework.^[6] This procedure is time consuming and necessitates sending the bar framework to the laboratory, during which time the patient will not be able wear the existing prosthesis. This case report describes a method that overcomes this difficulty using an attachment pickup technique for a quick, economical, and effective refabrication of an osseointegrated implant-retained silicone auricular prosthesis.

Access this article online	
Quick Response Code:	Website: www.j-ips.org
	DOI: 10.4103/jips.jips_227_16

This is an open access article distributed under the terms of the Creative Commons Attribution-NonCommercial-ShareAlike 3.0 License, which allows others to remix, tweak, and build upon the work non-commercially, as long as the author is credited and the new creations are licensed under the identical terms.

For reprints contact: reprints@medknow.com

How to cite this article: Kethireddy S, Kethireddy K. Refabrication of an implant-retained auricular prosthesis using clip attachment pickup technique. *J Indian Prosthodont Soc* 2017;17:310-5.

CASE REPORT

A 46-year-old male with hemifacial microsomia was referred to our center for the fabrication of a right auricular prosthesis. He sought replacement of the existing ill-fitting and unesthetic auricular prosthesis but was desirous of retaining the existing one as a spare.

On examination, a remnant of the right auricle was present in the defect area with two osseointegrated dental implants which were fitted with a twin Hader bar. A silicone auricular prosthesis was attached to the Hader bar with the help of two clips embedded in the prosthesis.

On evaluation [Figure 1], there was a remnant auricle, the right side of the face was relatively smaller than left, and there was an occlusal cant, following which a classification of $O_1M_0E_3N_0S_0$ -Plus was established.^[7] The proximity of the two implants placed meant that only two bars and clips had been fabricated. Due to the presence of remnant auricle in proximity to implants, Grade III skin reaction in the periabutment region was seen.^[8] Silicone auricular prosthesis was found to be unesthetic with thick margins, nontextured surface, improper shade matching, and ill-fitting [Figure 2].

Treatment planning

As the implants had been placed elsewhere, we had no access to previous records. Consequent to the patient being unaware about the implant system, it was not possible to procure the appropriate prosthetic screwdrivers. In addition, the patient requested for the fabrication of a new prosthesis for the existing Hader bar while retaining the older one so as to permit him to use both the prostheses alternatively. It was planned

to refabricate a new silicone implant-retained auricular prosthesis for the existing Hader bar without removing it from the osseointegrated implants. Therefore, a clip (attachment) level pickup impression technique was planned to refabricate an auricular prosthesis as described by Goveas *et al.*^[9] A minor modification was done at the model casting stage of the procedure to ensure accurate fabrication of the acrylic housing, ease of orientation, and reorientation of the same during the process of sculpting and try-in stages.

Technique

Defect and implant areas were thoroughly cleaned with normal saline and cotton gauze followed by:

Attachment splinting

Carding wax was used to block out underneath the metal framework before impression [Figure 3]. Two Hader rider clips (CEKA, Preci-Horix, Switzerland) were attached to the existing cast metal framework on the patient [Figure 4]. Pattern resin (GC America, USA) was used to connect the two Hader rider clips with the help of a prefabricated pattern resin bar. This pattern resin bar facilitated maintenance of the relation between clips, existing metal framework, and soft tissue of the mastoid area [Figure 5] and to pickup attachments into the impression.

Impressioning

A thin layer of petroleum jelly was applied on the hair at the site of impression to avoid pain during impression retrieval. "Trayless facial impression technique" was utilized. A medium body vinyl polysiloxane (Take 1 Advanced, Medium, Kerr Corporation, USA) was syringed onto the targeted area and the adjacent soft

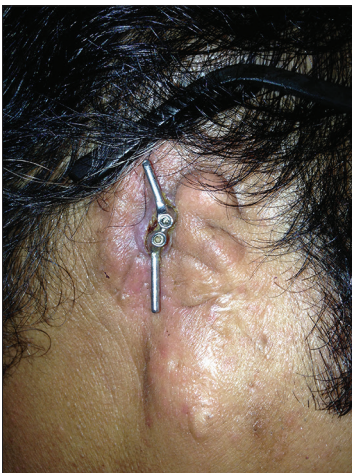

Figure 1: Examination view of the right auricular defect with Hader Bar, auricular remnant, skin reaction around abutment, and proximity of implants seen

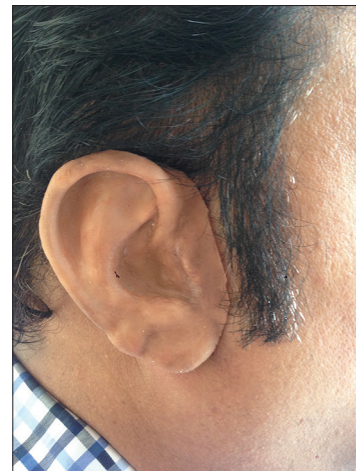

Figure 2: Examination of the right auricular prosthesis, ill-fitting, thick open margins, and improper shade match

tissue till the margins of the auricular prosthesis would extend. Before the material could set, wooden sticks were incorporated [Figure 6] and further reinforced with Type III dental stone (Gold Dental Stone, Chennai).

Model casting

The set impression was retrieved slowly to avoid either distortion of the impression or causing pain to the patient. At this point, a modification was made by incorporating tooth preparation diamond burs into the impression corresponding to each Hader bar [Figure 7]. This was done to enable the housing and the try-in prosthesis to fix and remove multiple times securely during sculpting and try-in processes. Type IV dental stone (Dr. Nok Dental Stone, Lafarge Prestie, France) was cast on the impression, and a working model was obtained, on which the clip rider attachments were reoriented on the dental bur embedded in the cast [Figure 8].

Acrylic housing

Attachment housing was fabricated using clear autopolymerizing polymethyl methacrylate (ProBase Cold, Ivoclar Vivadent AG) [Figure 9] and cured in pressure pot (indirect method). After housing was obtained, fitting was checked on the existing metal framework which was already fitted to patient's implants. The precision of the fit was checked by ensuring no rocking and click while fitting. Care was taken to have adequate surface area, at the same time not encroaching into the silicone prosthetic space.

Auricular wax sculpt and try-in

Existing auricular prosthesis was duplicated using irreversible hydrocolloid (Jeltrate, Dentsply, USA) and was poured with modeling wax (Rolex Modelling wax, India) to obtain the try-in auricular wax-up onto housing placed on the cast. Further, the obtained wax auricle was

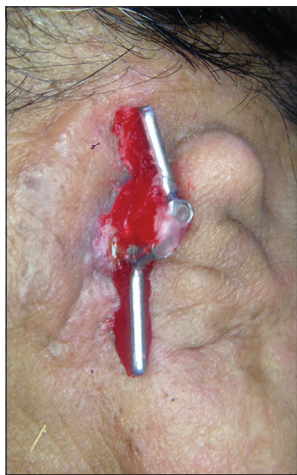

Figure 3: Blockout under Hader bar metal framework with carding wax on the patient

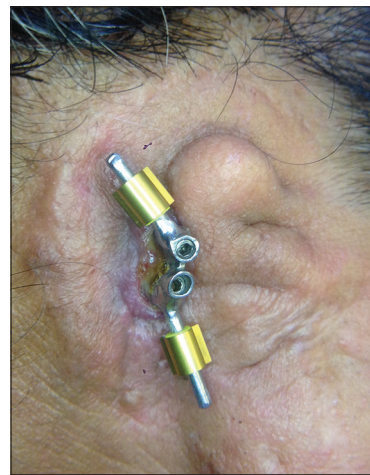

Figure 4: Two Hader rider clips with clip housing in place

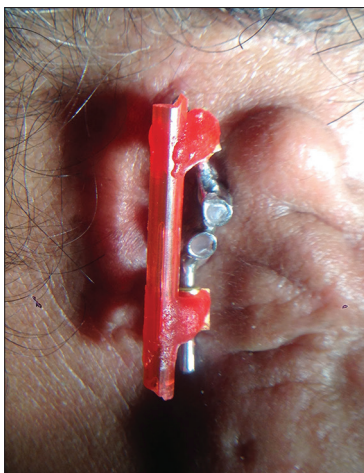

Figure 5: Both the clips assembly are attached with pattern resin for orientation

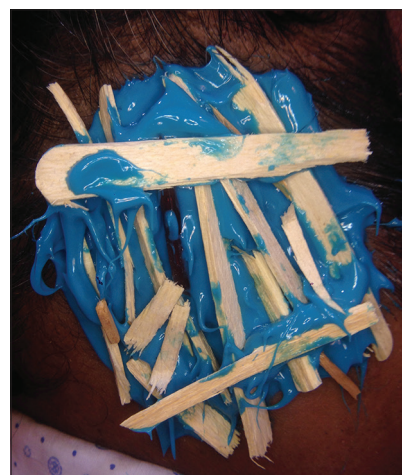

Figure 6: Attachment impression (mute-fit) technique using monophasic vinyl polysiloxane impression material, reinforced with pieces of tongue blades

customized to better mimic the contralateral ear up to a satisfactory wax-up.

Mold making and processing

A three-piece mold [Figure 10] was made using conventional flask, and room temperature vulcanizing (RTV) silicone (MDX 4-4210 medical grade elastomer, Factor II, Lakeside, AZ, USA) was mixed with intrinsic colors (Functional Intrinsic colours II, Factor II, Lakeside, AZ, USA) and packed as similar to conventional auricular prosthesis fabrication.

Finishing

The final auricular prosthesis was inserted after the final extrinsic coloration with dry earth pigments (Functional Extrinsic II, Factor II, Lakeside, AZ, USA).

Clinical evaluation

Prosthesis was fitted on the patient and was evaluated for fit, retention, marginal adaptation, esthetics, and comfort. Precise

fit [Figure 11] was established by noting better adaptation of the prosthesis when compared to the previous one [Figure 12].

Further evaluation was done using a visual analog scale (VAS) by the patient and an independent examiner. The following parameters were considered: fit (seating with click), retention, marginal adaptation, color match, symmetry with contralateral ear, and natural (life-like) appearance.

Each parameter was scored using a VAS from score 0–5 where 0 corresponded to poor and 5 excellent.

The patient was recalled after 6 months to reevaluate the prosthesis using the same parameters. A uniform score of 5 was obtained from both patient and the independent examiner at both examination periods.

This clearly indicates that the clinical outcome and patient satisfaction which are the key elements for evaluation quality of care^[10] have been achieved.

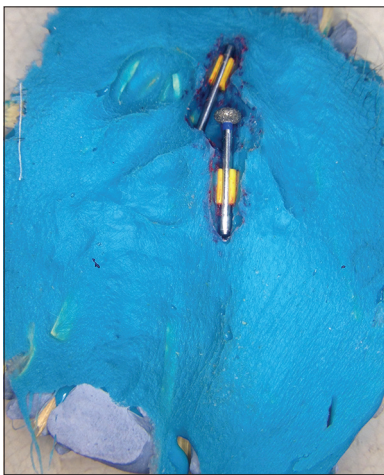


Figure 7: Retrieved impression, picked up clip attachments, followed by placement of tooth preparation burs before cast pour

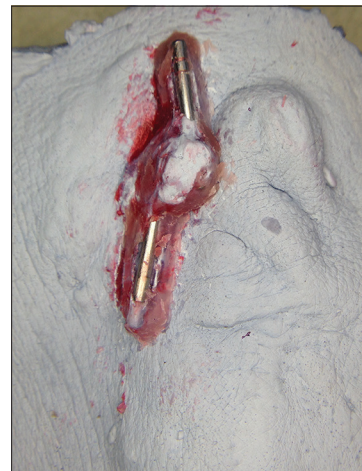


Figure 8: Working model cast with preparation burs in it

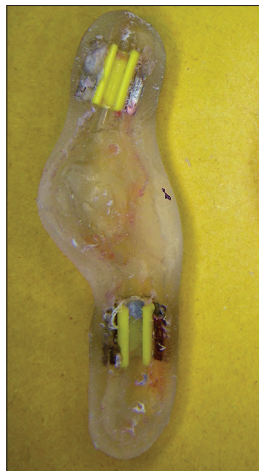

Figure 9: Clear autopolymerizing polymethyl methacrylate housing made indirectly on the cast with clips embedded



Figure 10: Three-piece auricular mold after the wax try-in

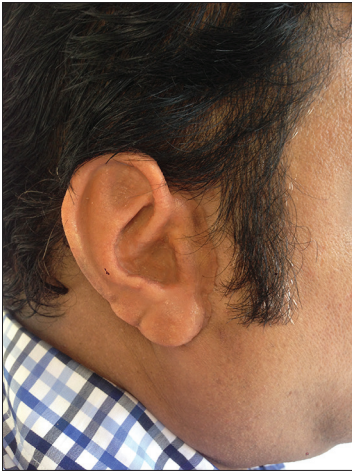

Figure 11: Finished prosthesis with acceptable esthetic and function

DISCUSSION

On average, refabrication of a facial prosthesis is done approximately once in 2 years due to color change^[11,12] or degradation of the facial silicone itself.^[12-16] Various reports have advocated clinical and laboratory methods to fabricate an implant-retained auricular prosthesis. However, to refabricate the same, there are few or no specific methods described in literature.

Analyzing the literature, refabrication techniques can be summarized into (1) fabrication of new metal framework and new silicone prosthesis fitting the new bar, (2) fabrication of a new metal framework by duplication of the original metal bar on the patient's implants without removing it,^[17] (3) fabrication of a new auricular prosthesis by removing the bar from the patient's implants and refitting them both, and (4) fabrication of new auricular prosthesis by making an attachment level pickup impression and refabricating auricular prosthesis without the removal of existing metal bar framework from patient's defect site.^[9]

From the above-summarized techniques, both 1st and 2nd do not necessitate the submission of metal framework to laboratory for the fabrication of prosthesis, therefore enabling the patient to wear existing prosthesis without any interruption. However, both these techniques are expensive due to the fabrication of a new metal framework and require longer duration to deliver both the framework and prosthesis. Technique 3 is a conventional method where the metal bar framework is removed and sent to laboratory for further fabrication of auricular prosthesis.^[6] This technique is an economical option, but the patients have to be without prosthesis during the period of fabrication or should be given a temporary dermal adhesive retained prosthesis. However, in patients with hypersensitivity for

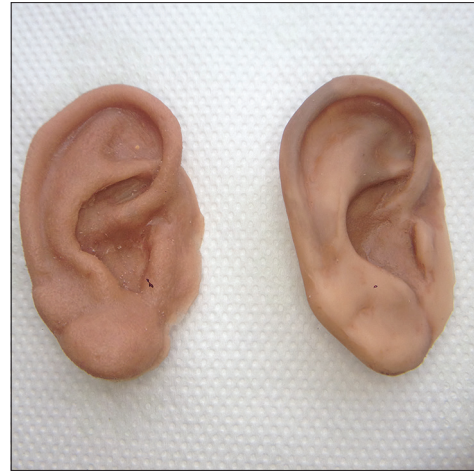


Figure 12: Compression between new and existing prostheses

the dermal adhesive, this technique cannot be advocated.^[18] The existing implant-retained auricular prosthesis can be directly attached using the dermal adhesive to reduce cost and to enable the patient to be with the prosthesis during the fabrication period. Technique 4 postulates an economical solution and also allows the patient to use his own implant-retained prosthesis during the fabrication of a new one.^[9] Both techniques 3 and 4 allow the patients to use both the auricular prosthesis alternatively on the same metal bar framework.

This case had been treated using the type 4 method for refabrication. This technique showed to have various advantages, such as being a cost-effective, precise, quickly fabricate technique, patient can wear their existing prosthesis during the course of refabrication of a new prosthesis, requires less inventory such as implant impression coping and laboratory analogs, like in this case if the implants information is unknown, and if the patients want to have a spare prosthesis for the same metal bar framework. Thereby these advantages made this technique a routine.

From a literature review, refabrication of a new facial prosthesis requires safe preservation of the working mold and flask.^[19] However, it is not practical to keep the flask of each patient, and if it is implant retained, an abutment analog cannot be reused. Even when the molds were preserved, the bar has to be removed from the patient for the processing, thereby the patient has to be without the prosthesis.

It was found that the fitting and accuracy of the pickup of attachments was satisfactory in the technique described in this case report. It was noticed that light-activated composite resin can be utilized instead of a pattern resin;

a medium body can be substituted with dual consistency impression to produce more accurate soft tissue details. The disadvantage is that it requires extreme care during impression retrieval and reorientation of the attachments on the cast making it technique sensitive. The putty consistency material used in previous studies^[20] might distort the tissues while recording and was hence not preferred in this case.

This technique differs from the technique postulated by Goveas *et al.*^[9] by incorporating a tooth preparation diamond bur making this technique more reliable during the sculpting and try-in processes due to frequent removal of the wax-up from the model. When fabricated with proper care, the prosthesis can be made to appear life-like, contributing to the overall psychological well-being of the patient.^[21]

CONCLUSION

Implant-retained craniofacial prosthesis is a reliable treatment option for the restoration of auricular defects. Whereas the need for postsurgical aftercare is relatively minor, prosthetic aftercare is essential to reduce wear and tear and refabrication of a new prosthesis. Therefore, this novel technique provides a simple yet predictable way to refabricate any facial prosthesis.

Financial support and sponsorship

Nil.

Conflicts of interest

There are no conflicts of interest.

REFERENCES

- Subasi MG, Alniaçik G, Kalayci A, Akman S, Durmus E. Prosthetic rehabilitation of partial ear defect: 2 case reports. *J Indian Prosthodont Soc* 2014;14 Suppl 1:196-201.
- Rocke DJ, Tucci DL, Marcus J, McClennen J, Kaylie D. Osseointegrated implants for auricular defects: Operative techniques and complication management. *Otol Neurotol* 2014;35:1609-14.
- Beumer J 3rd, Ma T, Marunick M, Roumanas E. Restoration of facial defects: Etiology, disability, and rehabilitation. In: Beumer J 3rd, editor. *Maxillofacial Rehabilitation: Prosthodontic and Surgical Considerations*. St. Louis: Ishiyaku EuroAmerica, Inc.; 1996.
- Chotprasert N, Srithavaj T, Santawisuk W, Hovichitr W, Visuttiwattanakorn S. Implant-retained auricular prosthesis in a young patient, 6 years follow-up: A clinical report. *Mahidol Dent J* 2007;27:217-22.
- Srithavaj T, Wijitworawong A, Kharel A, Sanohkann S, Santawisuk W. Attachment use in designing a stable facial prosthesis: A new clinical and technical report. *Mahidol Dent J* 2006;26:337-43.
- Jacob RF. *Auricular prosthetic rehabilitation*. In: Taylor TD, editor. *Clinical Maxillofacial Prosthetics*. Chicago: Quintessence; 2000.
- Horgan JE, Padwa BL, LaBrie RA, Mulliken JB. OMENS-plus: Analysis of craniofacial and extracraniofacial anomalies in hemifacial microsomia. *Cleft Palate Craniofac J* 1995;32:405-12.
- Tolman DE, Taylor PF. Bone-anchored craniofacial prosthesis study. *Int J Oral Maxillofac Implants* 1996;11:159-68.
- Goveas R, Shrestha B, Srithavaj ML, Thaworanunta S. Fabrication of a new silicone auricular prosthesis without removing the existing metallic framework. *J Prosthet Dent* 2014;112:1605-8.
- Chang TL, Garrett N, Roumanas E, Beumer J 3rd. Treatment satisfaction with facial prostheses. *J Prosthet Dent* 2005;94:275-80.
- Craig RG, Koran A, Yu R, Spencer J. Color stability of elastomers for maxillofacial appliances. *J Dent Res* 1978;57:866-71.
- Koran A, Yu R, Powers JM, Craig RG. Color stability of a pigmented elastomer for maxillofacial appliances. *J Dent Res* 1979;58:1450-4.
- Yu R, Koran A 3rd, Craig RG. Physical properties of maxillofacial elastomers under conditions of accelerated aging. *J Dent Res* 1980;59:1041-7.
- Haug SP, Andres CJ, Munoz CA, Okamura M. Effects of environmental factors on maxillofacial elastomers: Part III – Physical properties. *J Prosthet Dent* 1992;68:644-51.
- Haug SP, Andres CJ, Munoz CA, Okamura M. Effects of environmental factors on maxillofacial elastomers: Part IV – Optical properties. *J Prosthet Dent* 1992;68:820-32.
- Visser A, Raghoebar GM, van Oort RP, Vissink A. Fate of implant-retained craniofacial prostheses: Life span and aftercare. *Int J Oral Maxillofac Implants* 2008;23:89-98.
- Tarica DY, Brajevic FJ. Duplication of an existing implant-supported bar for an auricular prosthesis. *J Prosthet Dent* 2008;99:408-9.
- Srithavaj T, Choprasert N, Wijitworawong A, Hovichitr W, Sanohkann S. Restoration of large facial prosthesis with a connection to the intraoral prosthesis: A case report. *Mahidol Dent J* 2006;26:351-9.
- Chotprasert N, Srithavaj T, Sanohkan S, Visuttiwattanakorn S. Implant retained orbital prosthesis using console abutment: A case report. *Mahidol Dent J* 2007;27:231-6.
- Jain S, Maru K, Shukla J, Vyas A, Pillai R, Jain P. Nasal prosthesis rehabilitation: A case report. *J Indian Prosthodont Soc* 2011;11:265-9.
- Shanmuganathan N, Maheswari MU, Anandkumar V, Padmanabhan TV, Swarup S, Jibrán AH. Aesthetic finger prosthesis. *J Indian Prosthodont Soc* 2011;11:232-7.