

## Ultrasound-guided bilateral infraclavicular brachial plexus block: A report of three cases

### ABSTRACT

Anesthesiologists avoid multiple upper extremity peripheral nerve block applications due to complications such as increased phrenic nerve palsy and local anesthetic systemic toxicity risk. With the introduction of ultrasound into clinical life and the increase in the number of experienced anesthesiologists, such complications are less common. We also discussed three cases that we think may contribute to the literature on this subject. Our first case was scheduled for operation due to a trigger finger in his left hand and carpal tunnel syndrome in his right hand. Our second case was scheduled for surgery due to distal radius and ulnar fractures in both forearms. Our third case scheduled for operation for a fracture of the right forearm distal radius and a second metacarpal fracture in the left hand. In this report series, we present our experience of bilateral infraclavicular block, which we successfully performed in three cases and did not encounter any complications.

**Key words:** Bilateral infraclavicular block, regional anesthesia, ultrasound

### Introduction

Brachial plexus block (BPB), which is one of the most used methods among the other types of peripheral nerve block, is frequently used in the interventional procedures of the upper extremity, orthopedic manipulations, and the diagnosis and treatment of certain diseases. Regional anesthesia of the shoulder, arm, forearm, and hand can be performed using sympathetic sensory and motor blocks.<sup>[1]</sup> According to the planned intervention, BPB can be performed from five different regions, including interscalene, supraclavicular, infraclavicular, axillary and terminal nerves.<sup>[2]</sup> Because of the high rate of phrenic nerve palsy (PNP) observed in the interscalene block and the high risk of pneumothorax in the supraclavicular block (SCB), the infraclavicular block (ICB),


which has fewer complications, is preferred instead of other blocks in indications where ICB can be preferred over them.<sup>[2]</sup>

The applicability of bilateral BPB for such indications is still a matter of debate owing to several uncertainties. The first uncertainty is the thought that a higher dose of local anesthetic (LA) may be needed for bilateral BPB, which may result in an increased risk of LA systemic toxicity (LAST). However, with the use of ultrasound (US) in regional anesthesia, the direct visualization of target nerves and surrounding tissues has allowed the reduction of the LA dose used and the application of low-volume LA solutions as well as increased the success rate of the block. This has somewhat cleared the doubts about the application of multiple blocks

This is an open access journal, and articles are distributed under the terms of the Creative Commons Attribution-NonCommercial-ShareAlike 4.0 License, which allows others to remix, tweak, and build upon the work non-commercially, as long as appropriate credit is given and the new creations are licensed under the identical terms.

**For reprints contact:** WKHLRPMedknow\_reprints@wolterskluwer.com

**How to cite this article:** Şengel A, Seçilmiş S. Ultrasound-guided bilateral infraclavicular brachial plexus block: A report of three cases. Saudi J Anaesth 2022;16:232-5.

Access this article online	
<b>Website:</b> www.saudija.org	<b>Quick Response Code</b> 
<b>DOI:</b> 10.4103/sja.sja_737_21	

### ABDULHAKIM ŞENGEL, SELÇUK SEÇİLMİŞ<sup>1</sup>

Department of Anesthesiology and Reanimation, Siverek State Hospital, Siverek, Sanliurfa, <sup>1</sup>Department of Anesthesiology and Reanimation, Kahta State Hospital, Kahta, Adiyaman, Turkey

**Address for correspondence:** Dr. Abdulhakim Şengel, Department of Anesthesiology and Reanimation, Siverek State Hospital, Siverek, Sanliurfa, Turkey. E-mail: ahsengel121@gmail.com

**Submitted:** 15-Oct-2021, **Revised:** 16-Oct-2021, **Accepted:** 17-Oct-2021, **Published:** 17-Mar-2022

that can be done within the indication. Thus, if necessary, the application of multiple blocks has become more frequent in clinical settings. However, studies on this subject are still not at the desired level in the literature. Therefore, we believe that studies on this subject should be shared on scientific platforms. Accordingly, in this study, we present our experience of three cases where we planned and performed US-guided bilateral ICB for bilateral upper limb surgery.

## Case Reports

### Case 1

An operation was planned for a 60-year-old, 80-kg male patient due to trigger finger in the left hand and carpal tunnel syndrome in the right hand [Figure 1]. According to the medical history, the patient had no remarkable characteristics other than diabetes mellitus (DM), and his blood sugar was determined to be 218 mg/dL as one of the biochemistry test values obtained during preoperative examinations. Other laboratory tests were within normal limits. Electrocardiography (ECG) of the patient showed a normal sinus rhythm, and posteroanterior chest X-ray (POAG) was evaluated to be normal. The patient, whose physical examination results were normal, was asked to consult with the endocrine diseases department due to DM. After the consultation, the patient was re-evaluated, and we decided to operate the patient [American Society of Anesthesiologists (ASA) III] in compliance with the preoperative fasting period (at least 6 h of fasting is recommended) and recommendations of the endocrine department.

### Case 2

An 8-year-old, 36 kg, female patient was scheduled to undergo operation due to distal radius and ulnar fractures in both the forearms [Figure 2]. The patient had no remarkable medical history, and her preoperative examination results were within normal limits. The patient's (ASA I) physical examination was also normal, and we decided to perform the operation in compliance with the preoperative fasting period (at least 6 h of fasting is recommended).

### Case 3

A 56-year-old, 80-kg female patient was scheduled for operation due to distal radius fracture in the right forearm and the second metacarpal fracture in the left hand [Figure 3]. The preoperative examination results of the patient, who did not have a remarkable history of medical conditions other than asthma, were within normal limits. The patient's ECG showed a normal sinus rhythm, and POAG was evaluated to be normal. The patient's physical examination results were normal, and the pulmonary diseases department was

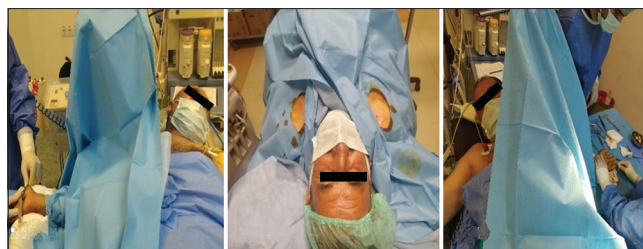

Figure 1: Postblock and intraoperative photograph for case 1

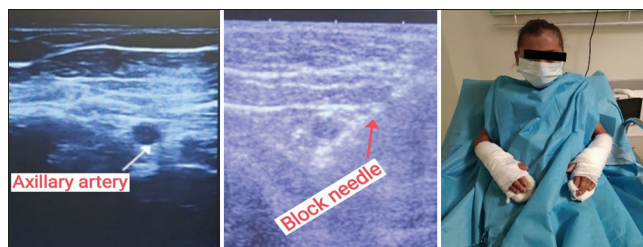


Figure 2: Ultrasound image and postoperative photograph for case 2

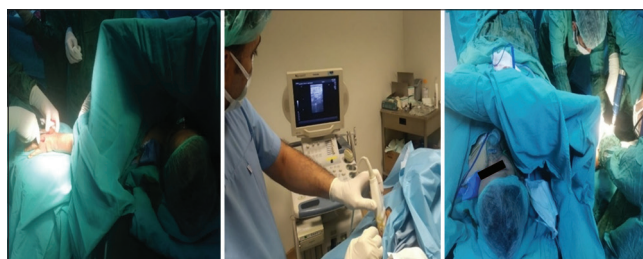


Figure 3: Moment of block and intraoperative photograph for case 3

consulted due to asthma. After consultation, the patient was re-evaluated, and we decided to operate the patient (ASA II) in compliance with the preoperative fasting period (at least 6 h of fasting is recommended) and recommendations of the pulmonary diseases department.

### Implementation of block procedure

The block procedure was explained jointly to all the three patients. However, it should be noted that the three patients were operated at different times.

Informed consent was obtained from the patients (for cases 1 and 3) and their parents (for case 2). After the patient was taken to the unit before the operation, various preparations were made considering the possibility of intubation and difficult ventilation-airway. The patient was monitored using ECG and pulse oximetry (for oxygen saturation level); the noninvasive blood pressure was also monitored. Sedation was not needed for cases 1 and 3. Conversely, case 2 patient was sedated with a combination of 2 mg midazolam (5 mg/5 mL of Midaject, All Ekip) and 35 mg ketamine (500 mg/10 mL of Ketalar, Pfizer) before the block procedure. Sedation was performed at 10 mL/kg/h for all three

patients. The patient's neck was turned to the side opposite to that of the block application, and they were placed in the supine position. The block area was sterilized using 10% povidine iodine. For administering ICB to the patient, we used Toshiba Nemio XG SSA-580A [Japan (origin US)], and a multi-frequency linear probe (10–18 MHz) and 22-G, 50-mm insulated facet-type needle (BBraun Stimuplex, Melsungen, Germany) were used during the block application. The US linear probe, which was placed in-plane right inside the coracoid process to provide an optimal image, was oriented to find the cross-sectional image of the axillary artery in the parasagittal plane. After administering local anesthesia with 3 mL of lidocaine (100 mg/5 mL of Lidon, On Farma) for cases 1 and 3 and 1.5 mL of lidocaine for case 2 to cover the skin and subcutaneous tissue at the injection site, the processing area is entered with a block needle under USG image guidance. After the axillary artery and its surrounding neural structures were determined by the long axis method, the block needle was inserted around all three cords (lateral, medial, and posterior) in a way such that the LA solution could be administered. After reaching the target areas, for cases 1 and 3, the procedure was performed by conducting a negative aspiration test (repeated after each administration of 5 mL of LA solution for cases 1 and 3 and 3 mL of LA solution for case 2), while 5 mL of 2% lidocaine and 10 mL of 0.5% bupivacaine (Buvasin 5 mg/mL, Vem İlaç, Turkey) diluted with 5 mL of 0.9% isotonic sodium chloride (a total of 20 mL of LA solution) were prepared and injected into the relevant areas. For case 2, a total of 14 mL of LA solution, i.e., 3 mL of 2% lidocaine and 7 mL of 0.5% bupivacaine diluted with 4 mL of 0.9% isotonic sodium chloride, was prepared and injected into the relevant areas. In all the three cases, the injection procedure was performed in a way such that the LA distribution was constantly displayed on the US screen in order to avoid complications such as intraneural injection or intraarterial injection. In case the image disappeared from the screen or when resistance was encountered during the procedure, the operation was performed by reorienting the needle via small maneuvers in the form of tilts, thereby providing an optimal image. Immediately after the first block application, the position of the patient was changed, and the block application was initiated on the other side. The second block application was performed in the same way. The blocks were considered successful since there was no withdrawal response and no hemodynamic change in response to a painful stimulus 15 min after both blocks. Later, the patient was transferred to the operating room and the operation was initiated. The duration of operation for case 1 in which operation was performed on both sides without any problems was approximately 1 h and 25 min for operating both sides. The duration of operation for case 3 was approximately 2 h

and 5 min for operating both sides. No additional sedative or analgesic agents were administered to case 1 and 3 patients during the operation. The duration of operation for case 2 was approximately 2 h and 40 min for operating both sides. Sedation agents (midazolam and ketamine) were re-administered to the case 2 patient at the 80<sup>th</sup> minute of the operation for the maintenance of sedation. After the operation, the vital signs of all the three case patients, who were followed up for 30 min in the postoperative care unit, were found to be stable, and the patients were transferred to the orthopedics clinic. The patients who did not complain of postoperative pain up to one day after the operation were discharged on the second day we evaluated that they did not have any neurological sequelae symptoms. One week after discharge, we were informed that no problems were faced by the patients who applied to the orthopedic outpatient clinic for follow-up purposes.

## Discussion

Peripheral nerve blocks (PNB) are widely used as both anesthetics and postoperative analgesics. PNBs, which are safe when performed with the aid of a nerve stimulator and/or US, can be applied multiple times if necessary, but this situation causes other problems. One of the most important concerns associated with bilateral BPB is the potential risk of PNP and LAST.

As per the literature, it has been found that PNP occurred at rates of between 21% and 100% after block application, between 28% and 67% after SCB application, and between 5% and 13% after ICB application.<sup>[3-6]</sup> In another study, PNP was found to be less common in case of ICBs.<sup>[7]</sup>

With regard to LAST, which is another serious side effect as mentioned above, it has been found in the literature that the use of the minimum effective dose of LA required for a successful US-guided block minimizes the risk of LAST.<sup>[8]</sup> In the study conducted by Mangla *et al.*,<sup>[7]</sup> they reported that they reduced LAST risk even more by reducing the volume of LA solution to 30 mL from the previous volume of 40 mL during block application. Moreover, they reported that they tried to reduce LAST risk further by including, in addition to bupivacaine, chlorprocaine and lidocaine, which act more rapidly than bupivacaine, in the LA solution.<sup>[7]</sup> When we look at another study aimed at reducing the risk of LAST, it was stated that the peak plasma concentration of LA could be reached quickly as a result of the absorption of each simultaneous bilateral block, and it was stated that a sufficient time interval should be maintained between each block for this purpose.<sup>[9]</sup> Similar to this study, it was stated

in another study that a time interval between blocks would prevent peak systemic absorption rate overlap for each block, thus preventing a potential LAST risk.<sup>[10]</sup> In another study, it was suggested that a time interval of at least 60 min should be considered between each block in case of multiple block applications to prevent LAST.<sup>[11]</sup>

PNP findings were not detected after bilateral ICB in any of our case patients, and it was reported in previous studies that PNPs seen after ICB were mostly related to the high volume of LA solution used.<sup>[12]</sup> We think that we reduced this risk by performing each of our blocks with a low volume of LA (20 mL for each block in cases 1 and 3 and 14 mL for each block in case 2). Furthermore, we believe that we minimized the risk of PNP by preferring ICB over SCB, even when all three of our patients could be operated under SCB, since, as mentioned above, the incidence of PNP is further reduced with the use of ICBs.<sup>[7]</sup>

Perhaps the most important alarming complication caused by bilateral (multiple) blocks is LAST that may occur as stated in previous studies. In order to avoid encountering such a situation, we performed our block procedure with the aid of US and tried to choose the lowest dose of LA that could be used in our patients. At the same time, we not only lowered the dose but also tried to keep the LA solution low in volume. In our blocks, we used lidocaine as an additional LA along with bupivacaine to keep the dose of bupivacaine low and for the LA solution to act quickly. As seen in the literature, many studies<sup>[9-11]</sup> recommend that these blocks be performed at regular intervals in order to prevent reaching the peak plasma concentration of LA in bilateral (multiple) blocks. However, since we used both low-dose and low-volume LA solutions in our US-guided blocks, we assumed that we would not reach the peak plasma concentration that could cause LAST. Therefore, we did not see any harm in performing our bilateral (multiple) blocks sequentially, and we were not wrong about this prediction since LAST was not observed in any of our patients.

To summarize, we present three cases in which US-guided bilateral ICB was successfully applied during bilateral upper limb surgery and no side effects (PNP, LAST, etc.) were encountered. We tried to show that this method is a reliable and alternative to general anesthesia when bilateral upper extremity surgery is required but general anesthesia should be avoided for any reason. We believe that more studies on this subject should be conducted and published.

### Patient consent statement

The authors confirm that they have received all relevant patient consent forms, in particular the informed consent form. In these forms, either patients or their parents consented to the publication of patient images and other clinical information on scientific platforms provided that patients' identifying information is kept confidential.

### Financial support and sponsorship

Nil.

### Conflicts of interest

There are no conflicts of interest.

### References

1. Acar S, Gürkan Y, Solak M, Toker K. Coracoid versus lateral sagittal infraclavicular block. *Acta Orthop Traumatol Turc* 2013;47:32-7.
2. De Tran QH, Clemente A, Doan J, Finlayson RJ. Brachial plexus blocks: A review of approaches and techniques. *Can J Anaesthesia* 2007;54:662-74.
3. Palhais N, Brull R, Kern C, Jacot-Guillarmod A, Charmoy A, Farron A, *et al.* Extrafascial injection for interscalene brachial plexus block reduces respiratory complications compared with a conventional intrafascial injection: A randomized, controlled, double-blind trial. *Br J Anaesth* 2016;116:531-7.
4. Kang RA, Chung YH, Ko JS, Yang MK, Choi DH. Reduced hemidiaphragmatic paresis with a "corner pocket" technique for supraclavicular brachial plexus block: Single-center, observer-blinded, randomized controlled trial. *Reg Anesth Pain Med* 2018;43:720-4.
5. Kim BG, Han JU, Song JH, Yang C, Lee BW, Baek JS. A comparison of ultrasound-guided interscalene and supraclavicular blocks for post-operative analgesia after shoulder surgery. *Acta Anaesthesiol Scand* 2017;61:427-35.
6. Sivashanmugam T, Maurya I, Kumar N, Karmakar MK. Ipsilateral hemidiaphragmatic paresis after a supraclavicular and costoclavicular brachial plexus block: A randomised observer blinded study. *Eur J Anaesthesiol* 2019;36:787-95.
7. Mangla C, Kamath HS, Yarmush J. Bilateral brachial plexus block using chloroprocaine for surgery of bilateral radial fractures. *Local Reg Anesth* 2019;12:99-102.
8. McNaught A, Shastri U, Carmichael N, Awad IT, Columb M, Cheung J, *et al.* Ultrasound reduces the minimum effective local anaesthetic volume compared with peripheral nerve stimulation for interscalene block. *Br J Anaesth* 2011;106:124-30.
9. Kim BG, Yang C, Lee K, Choi WJ. Bilateral brachial plexus block in a patient with cervical spinal cord injury: A case report. *Medicine* 2020;99:e21126.
10. Mistry T, Balavenkatasubramanian J, Natarajan V, Kuppusamy E. Ultrasound-guided bilateral costoclavicular brachial plexus blocks for single-stage bilateral upper limb surgeries: Abstain or indulge. *J Anaesthesiol Clin Pharmacol* 2019;35:556-7.
11. Holborow J, Hocking G. Regional anaesthesia for bilateral upper limb surgery: A review of challenges and solutions. *Anaesth Intensive Care* 2010;38:250-8.
12. Hendriksen E, Slagt C. Bilateral brachial plexus block using chloroprocaine for surgery of bilateral radial fractures. *Local Reg Anesth* 2019;12:109-10.